World Journal of Zoology 8 (2): 192-197, 2013
ISSN 1817-3098

DOI: 10.5829/idosi.wjz.2013.8.2.7328

Structure ofMetanephrosat Term Embryo Stage of *Megaderma lyra lyra* (Geoffroy) Chiropteran, Mammalian

Kishor Gopal Patil

Department of Zoology, Government Institute of Science,
R.T. Road, Civil Lines Nagpur 440001, (M.S.) India

Abstract: Mammalian kidneys are involved in excretion of waste substances, conservation of water and maintain homeostasis. Chiropteran kidneys are adapted with the diversity in habitats and feeding habits.Themetanephros atterm stageofIndian false vampire, *Megaderma lyra lyra*wasexamined. The right and left kidneys of embryos at term pregnancy wassimple, bean shaped and almost similar in size and weight. The kidneys were differentiatinginto the cortex and medulla which leads into asinglepapilla. The papilla protrudes outside into the ureter. In the cortex the well developed Bowman's capsules were surrounded by convolutions of proximal and distal tubules. At the vascular pole of the Bowman's capsules the glomerular arterioles and the cells of macula densa in juxta-glomerular apparatus are well differentiated. Very thick medulla and papilla bear characteristic dense network of connective tissue; which encloses few differentiating straight renal tubules and blood vessels. The kidneys show the papilla protruding outside the kidney through the hilus.

Key words: Bat · Kidney · Metanephros · UriniferousTubule · False Vampire

INTRODUCTION

In mammals the three types of excretory organs pronephros, mesonephros and metanephros appear in succession during the course of embryogenesis [1]. The pronephros the most primitive organs appear and degenerated in the early embryonic stages in birds and mammals. In the early embryonic stages of mammals the mesonephros attains a considerable degree of development. To the caudal of the mesonephros a third excretory organ develops as metanephros. The metanephrosarises from the mesoderm lies in-between the aorta and the mesonephros.The metanephros developsin later stages and become the functional kidney in the adult.

The chiropteransbear simple kidney divided into an outer cortex, medulla converging in straight lines to the pelvis forming the terminal papilla. In animalivorousmicrochiropteran bats the thick medulla divided into an outer and an inner zone and a long conical papilla protruding outside the kidney which is associated with the feeding habit and the urine concentrating ability of these bats [2-7].

During the development in the 21 somite stage embryo of *Rhinolophus hipposideros* the sclerotomes and mesonephric plaques bears bimetameric relationship for each sclerotomes at the cranial end; this pattern was not consistent in the older embryos of *Nyctalus*; [= *Vesperugo*] *noctula* [8]. Sperber [6] noticed typical fetal furrows on the surface of embryonic kidneys from *Myotis* (Kidney 1.0 mm in length) and *Plecotus*. There is some species specific differentiation of the excretory organs during development. The structureof metanephros at late term embryo stage of *Megaderma lyra lyra* described in this study.

Patil and Janbandhu [9] studied the development of Metanephros in Indian False Vampire *Megaderma lyra lyra*. Patil *et al*. [10] alsoexamined the developing metanephros at phalange stage (with a body mass 0.012g and CR length 15mm) of Indian false vampire *Megaderma lyra lyra*. The kidneys were bean shaped, similar in dimensions and not differentiatedinto cortex and medullary components. In the metanephri examined the wide primary collecting tubules originating from the central large cavity of renal pelvis terminates as ampullae at the external surface and form the furrows. Around the cavity of renal pelvis the thick metanephrogenic mesoderm towards the ampullaegradually transformed into the renal tubules.

Corresponding Author: Kishor Gopal Patil, Department of Zoology, Government Institute of Science, R.T. Road, Civil Lines Nagpur 440001, (M.S.) India, Res: 54, Old JagrutiColony, Katol Road, Nagpur- 440 013, (M.S.) India.

MATERIALS AND METHODS

The study is based on the examination of kidneys from the formalin preserved embryos of *Megaderma lyra lyra* at late term stage of development. Previously the pregnant females of *M. lyralyra* were collected from the underground dilapidated mines around Nagpur, Maharashtra, India.The embryos at late term stage were selected; their body weight and sex were recorded. The kidneys from the selected embryos were dissected out; weight was taken by using the electronic weighing balance; washed overnight and dehydrated, cleared in xylene and embedded in paraffin (58-60°C). The mid sagittal sections of kidneys of embryos were cut at 5-7µm with the help of rotary microtome. For routine histological observations the sections were stained with Haematoxylin-Eosinand observed under light microscope. The measurements of different parts of metanephros were calculated with the help of ocular micrometer.

RESULTS

The kidneysat term stage of embryonic development examined were bean shaped; covered by collagenous capsule, the left and right kidneys possess almost similar dimensions (Fig. 1). In the cortical region well-developed

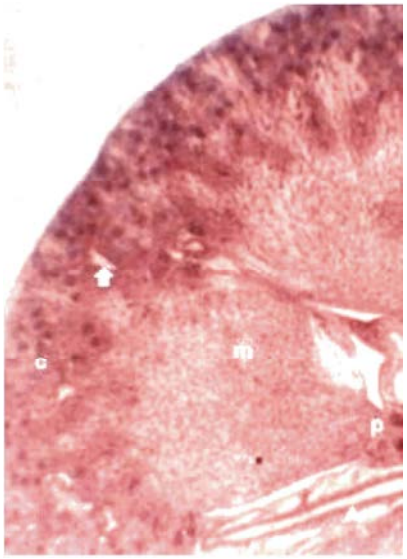

Fig. 1: Sagittal section of the kidney in late embryo stage of *M. lyralyra* to show a dense outer cortex (c), the inner medulla (m) and the papilla (p). Large blood vessels (arrowheads) are embedded in the collagenous tissue of the renal pelvis. The arcuate vessels (thick arrows) are observed in the cortico-medullary region(H and E; X50)

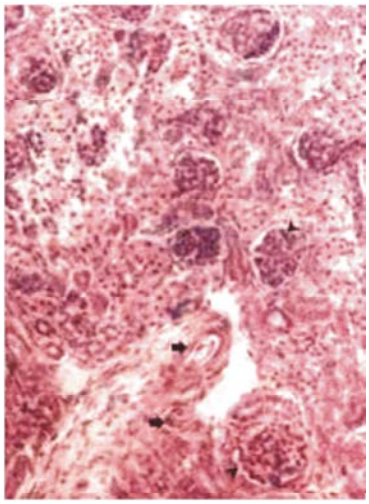

Fig. 2: Part of cortex magnified to show numerous darkly stained Bowmen's capsules (arrowheads). The large number of differentiating tubules with darkly stained nuclei is present surrounding the Bowman's capsules. Note the large cortical blood vessels (thick arrows). (H and E; X200)

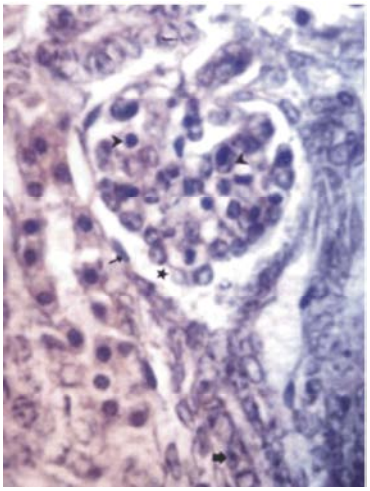

Fig. 3: The glomerulus in the Bowman's capsule the shows cells (arrowheads) with darkly stained nuclei are present in between the capillaries. The capsular lumen (★) lined by squamous epithelial cells (thin arrow) continues through neck as the lumen of proximal convoluted tubule. The squamous epithelial cells of the Bowman's capsule transformed into cuboidal epithelial cells (thick arrow) at the neck of the tubule. The juxta-glomerular apparatus (j) with macula densa is located at the vascular pole of the Bowman's capsule. The differentiating tubules with darkly stained nuclei are present in between surrounding the thick connective tissue (ct).(H and E; X900)

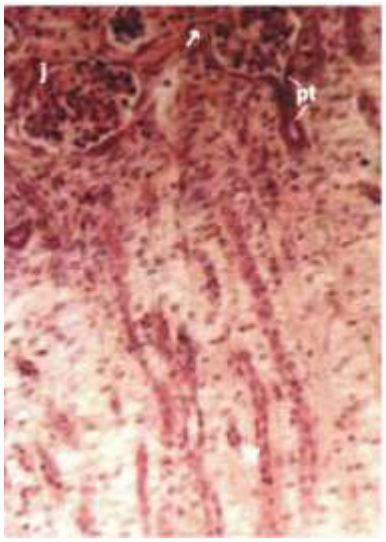

Fig. 4: Part of the cortex and the medulla magnified to show the juxta-glomerular apparatus (j) at its vascular pole and proximal convoluted tubule (pt) cut longitudinally at the tubular pole. The arteriole is noticed (thin arrow) at the vascular pole. In the medulla the differentiating, long, straight and narrow renal tubules (arrowheads) are embedded in the connective tissue matrix(H and E;X200)

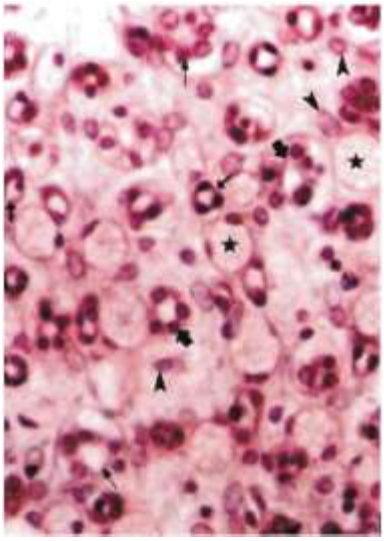

Fig. 5: T.S. through medulla of the term embryo of *M. lyralyra* to show three types of uriniferous tubules with varying diameter and varying number of the epithelial cells. 1. The collecting tubules (thick arrows) with wide lumen lined by the cuboidal epithelial cells with large, round nuclei. 2. The small tubules forming the thin loop of Henle (thin arrows) lined by 2-3 flattened epithelial cells with dark nuclei. 3. The proximal and the distal tubules having intermediate diameter. As compared to the distal tubules (long arrows) the proximal tubules possess very narrow lumen (arrowheads). The medulla at this stage is highly vascularised and show numerous blood capillaries (ê) lined by the endothelial cells. Note the presence of large interstitial cells (long arrowheads) with large nuclei in the connective tissue(H and E; X500)

Bowman's capsules with well differentiated glomeruli are present (Fig. 2). In the Bowman's capsules the glomerular cells with dark, round nuclei occupy the spaces in between the glomerular capillaries, which are surrounded by wide lumen lined by the squamous epithelial cells. The afferent glomerular arteriole and darkly stained juxta glomerular apparatus are observed at the vascular pole of the Bowman's capsules (Fig. 3). Around the Bowman's capsules the renal tubules can be differentiated into the proximal and distal convoluted tubules, but this differentiation is well defined in the medulla. The medulla consists of the different types of the uriniferous tubules with varying outer and luminal diameter and different cell types (Figs. 4 and 5). At this stage the papillaconsists of large collecting ducts, collecting tubules and the thin loop of Henle (Fig. 6).

A typical and detailed structure of the Bowman's capsule is observed in the kidney of late embryonic developmental stage of *M. lyralyra*. At the tubular pole the glomerular lumen continues as the lumen of the proximal convoluted tubule. The squamous epithelial cells of the Bowman's capsule are transformed into the columnar epithelial cells. The afferent and efferent arterioles and the cells of the macula densa are also observed at the vascular pole of the Bowman's capsule. At this stage of embryonic development the long urinary tubules in the medullary region are surrounded by the dense network of the blood capillaries (Figs. 4 and 5). The branches of the renal vessels are also observed in the renal pelvis of the late embryonic kidney of *M. lyralyra* (Fig. 1).

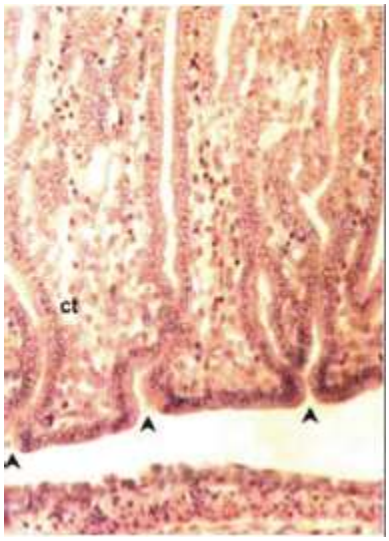

Fig. 6: Papillary region of the kidney of prenatal *M. lyralyra* to show the collecting ducts, lined by the large columnar epithelial cells with basal nuclei. Arrowheads points towards the opening of the collecting ducts into the calyx (arrow head). ct: connective tissue.(H&E; X200)

DISCUSSION

Inmammals the excretory organs i.e. the pronephros, mesonephros and metanephrosdevelop in succession; the pronephros and mesonephros are transitory structureswhilethe metanephrosdevelop into the permanent kidney[1]. Kidney plays an important role in maintaining volume and the concentration of body fluids. The uriniferous tubules in the kidney of mammals are meant to produce significantly concentrated urine as compared to the plasma [11-13].

In *M. lyralyra*the embryos at phalange stage the kidneys exhibits the differentiating renal tubules, the renal corpuscles, the Bowman's capsules. The renal artery entering the kidney anterior to the ureter branches at the region of the renal pelvis. The fetal furrows were also noticed in the developing kidneys of *M. lyralyra* [9,10]. Sperber [6] also observed the renal furrows on the outer surface of the fetal kidneys of *Myotis* and *Plecotus*.

The kidneys at term stage of embryonic development in *M. lyralyra*are covered by collagenous capsule and exhibit the differentiation of outer cortex and

Table 1: Details of Kidney Measurements of *M. lyralyra* at term embryo stage

			Kidney Measurement (LengthxWidthxThick in mm)		Weight of Kidney in gms.	
Sr. No.	Sex	Body wt. in gms.	Right Kidney	Left Kidney	Right Kidney	Left Kidney
1	Male	6	3 x 2 x 2	3 x 2 x 2	0.02	0.02
2	Ø	14	5.5 x 3.5 x 3.4	5.5 x 3.6 x 3.3	0.04	0.04
3	Female	8	3.5 x 2.4 x 2.3	3.8 x 2.4 x 2.3	0.03	0.02
4	Ø	12	6 x 4 x 2.6	6 x 4 x 2.6	0.07	0.06

Table 2: Measurements of different components of Prenatal Kidney of *M. lyralyra (*in µm)

Sr. No.	component	Thickness/ Length*/ Diameter**
1	Capsule	96
2	Cortex	418
3	Medulla	1008
4	Papilla	1642*
/5_	Calyx (space)	112
6	Hilum	1046**
7	Bowman's Capsule	52**
8	Glomerulus	47**
9	Glomerular Lumen	2
10	Juxta-Glomerular Apparatus	33

Table 3: Types of Cells in Uriniferous Tubule of Prenatal Kidney of *M. lyralyra* (in µm).

Sr. No.	Metanephric Component	Diameter Cells	Diameter of Nucleus	No. of cells in T.S.	Shape of cells
1	Glomerulus	5	3	--	Irregular
2	Juxta- Glomerular Cells	5	3	--	Spherical
3	Macula Densa	8	5	6	Cuboidal
4	Proximal convoluted tubule	8	5	4 to 6	Columnar
5	Thin Loop of Henle	6	4	3 to 5	Flattened
6	Distal convoluted tubule	8	5	5 to 7	Cuboidal
7	Collecting Tubule	8	6	7 to 9	Columanr
8	Collecting Duct	8	6	8 to 12	Columnar
9	Interstitial Cells of Papilla	9	6	--	Spherical

Table 4: Diameter of Uriniferous Tubules of Prenatal Kidney of *M. lyralyra* (in μm)

Sr. No.	component	External Diameter	Luminal Diameter
1	Proximal Tubule	19	2
2	Thin Loop of Henle	13	3.5
3	Distal Tubule	22	7
4	Collecting Tubule	27	10
5	Collecting Duct	31	11

inner thick medulla.The cortical region shows well-developed Bowman's capsules with well differentiated glomeruli enclosed inside. In the cortex the renal tubules can be differentiated into the proximal and distal convoluted tubules. The medulla consists of the different types of the uriniferous tubules with varying diameter). The medulla at this stage is highly vascularised and shows numerous blood capillarieslined by the endothelial cells. The presence of large interstitial cellsin the characteristic dance network of connective tissue noticed in the medullary region.The length of loop of Henle is proportional to the medullary thickness; responsible for urine concentrating function by reabsorbing maximum possible water and electrolytes from the filtrate [13]. Thelarge papilla is consists of collecting ducts, collecting tubules and the thin loop of Henle. The interstitial cells are also observed in the connective tissue of the papillary region. The kidneys of postnatal suckling stage attached to the lactating female of *M. lyralyra*were increased in size and show more differentiation of renal components. The postnatal kidneys also exhibit the differentiation of medulla into outer and inner regions [9]. The outer and an inner zone of medulla and a long conical papilla protruding outside the kidney is associated with the feeding habit and the urine concentrating process in this bat [3]. Similar adaptations of medulla and renal papilla are observed in some other carnivores, insectivores, marsupials, microchiropterans and rodents neotropicalmicrochiropteran bats [5, 7]. The length of the loop of Henle is related to the medullary and Papilla thickness. Thus the medullary and papillary thickness can be directly correlated with the urine concentrating as well as water conservation by the kidneys [11, 14]. In *M. lyralyra* the divided medulla and a large papilla may be an adaptation with the animalivorousdiet they consume as well as the urine concentrating ability. Inthe adult of *M. lyralyra* suggested that the kidneys with thick medulla subdivided into outer and inner zones representing the long uriniferous tubules adapted for conservation of water in the animals with high protein rich diet [8].

REFERENCES

1. Patten, B.M., 1968. The Urogenital System, Chapter XIX. In: Human Embryology, 3d. ed., McGraw-Hill Book Company. New York, pp: 449-499.
2. Patil, K.G. and K.S. Janbandhu, 2011. Study on the Renal Structure in Indian Fruit Bat *Rousettusleschenaulti* (Desmarest), Family- Pteropodidae, Order- Chiroptera, Mammalia. Review of Research Journal, I(III): (Online).
3. Patil, K.G. and K.S. Janbandhu, 2012. Observations on the Renal Morphology of Indian False Vampire *Megaderma lyra lyra* (Geoffroy). Asian Journal of Biology and Biotechnology, 1(1)103: 1-11.
4. Patil, K.G. and K.S. Janbandhu, 2012. Morphology and Histoarchitectural Observations on the Renal Organs of Indian Leaf Nosed Bat *Hipposiderosspeoris*, Order-Chiroptera, *Mammalia* (Schnider). International Journal of Biotechnology and Biosciences, 2(1): 64-70.
5. Rosenbaum, R.M., 1970. Urinary System. In: Biology of bats, (W.A. Wimsatt, Ed.) Acad. Press, New York, pp: 331-387.
6. Sperber, I., 1944. Studies on the mammalian kidney. Zool. Bidr. Uppsala, 22: 249-431.
7. Studier, E.H., S.J. Wisniewski, A.T. Feldman, R.W. Dapson, B.C. Boyd and D.E. Wilson, 1983. Kidney structure in Neotropical bats. Journal of Mammology. 64(3): 445-452.
8. Van der Strict, O., 1913. Le mésonéphros chez le Chauve-souris. C.R. Assoc. Anat. Suppl., 15: 60-65.
9. Patil, K.G. and K.S. Janbandhu, 2011. Developmental Stages of Metanephros in Indian False Vampire *Megaderma lyra lyra* (Geoffroy) Chiroptera, Mammalia. Review of Research Journal, I(III): 11: 1-4 (Online).
10. Patil, K.G., K.B. Karim and K.S. Janbandhu, 2012. Metanephros Structure at Phalange Stage of Embryonic Development in Indian False Vampire *Megaderma lyra lyra* (Geoffroy) Chiroptera, Mammalia. Global Journal of Science, Engineering and Technology, 1: 13-18.
11. Al-kahtani, M.A., C. Zuleta, E. Caviedes-Vidal and T. Garland, Jr., 2004. Kidney mass and relative medullary thickness of Rodents in relation to habitat, body size and phylogeny. Physiol. Biochem. Zool., 77(3): 346-365.

12. Beuchat, C.A., 1991. Body size, medullary thickness and urine concentrating ability in mammals. American Journal of Physiology, 258: R298-R308.
13. Patil, K.G., K.S. Janbandhu and A.V. Ramteke, 2011. Renal Morphology of Indian Palm Civet *Paradoxurus hermaphroditus hermaphroditus* (Schrater); Order-Carnivora, Mammalia. Hislopia Journal, 3(2): 177-182.
14. Bassett, J.E., 1982. Habitat aridity and intraspecific differences in the urine concentrating ability of insectivorous bats. Comp. Biochem. Physiol., 72A(4): 703-708.