

## Histopathological Evaluation of A/chicken/iran/339/02 (H9N2), an Iranian Field Isolate of Influenza Virus, on Japanese Quail (*Coturnix coturnix japonica*)

<sup>1</sup>Seyyed Mahmoud Ebrahimi, <sup>2</sup>Hassan Nili and <sup>3</sup>Nooshin Sohrabi

<sup>1</sup>Department of Biotechnology, Razi Vaccine and Serum Research Institute (RV/SRI),  
P.O.Box 31975/148, Karaj, Tehran, Iran

<sup>2</sup>Department of Avian Research, School of Veterinary Medicine,  
P.O.Box 1731, Shiraz University, Shiraz, Iran

<sup>3</sup>Mycology Research Centre, Faculty of Veterinary Medicine, Tehran University, Tehran, Iran

**Abstract:** The respiratory and gastro intestinal systems of the quail could be a major source of avian influenza virus shedding and transmitting viral particles to other birds and species and endanger public health. So, in this study, the gross and histopathological findings of quail experimentally infected with field isolate of A/chicken/Iran/ 339/02 (H9N2) avian influenza virus were examined to evaluate the mortality and mobility rate of this isolate. A total of 50 quails at the age of 14 days were randomly divided in two groups: 25 quails in the trial group and 25 in the control group. The trial group was inoculated with  $10^{6.3}$  50% embryo infectious dose/bird of avian influenza virus via nasal inoculation. Moderate clinical signs were observed 6 days post-infection (p.i.). No mortality was observed. Macroscopic and microscopic findings were observed mostly in the respiratory system, liver and intestine. No clinical and pathological signs were determined in the internal organs of the quails in the control groups. This study determined that the respiratory and gastro intestinal systems were affected more severe than other organs. However, the level of cell injuries has direct relation with accumulation of infection agents.

**Key word:** Avian influenza • H9N2 • Quail • Histopathology • clinical signs

### INTRODUCTION

There is increasing evidence that H9N2 avian influenza viruses are endemic in chickens and other land-based poultry, such as quail, pheasant, chukar and other minor domestic poultry in many Asian and European countries [1-3].

More recently, quails have shown a high incidence of infection with influenza A viruses, particularly H9N2 viruses in Hong Kong where 16% of quails in the markets were found to be positive for H9N2 viruses [4]. Besides, the H5N1 viruses were found to be cocirculating with H9N2 and H6N1 viruses in the Hong Kong poultry markets. Sequence analysis suggested that the 1997 H5N1 virus was a reassortant containing genes from an H6N1 and/or an H9N2 virus. Both viruses are endemic in quail in Hong Kong [5-6]. Also, there has been concern about the role of Japanese quail in the genesis of influenza viruses with pandemic potential [7]. Thus, since 1997; there has been increased interest in characterizing the incidence and subtypes of avian

influenza A virus infection in quail. So far the studies on the pathological changes of the quails caused by the virus are in deed limited. Therefore, in the present study, the gross and histopathological findings of quail experimentally infected with field isolate of A/chicken/Iran/339/02 (H9N2) avian influenza virus were examined.

### MATERIALS AND METHODS

**Specimen Collection:** Lungs, trachea and Liver were collected from chicken showing clinical signs and mortality of avian influenza virus (AIV) in Fars province of Iran in 2002 and were stored in -70°C.

**Birds:** A total of fifty two-week-old Japanese quails (*Coturnix coturnix japonica*) were obtained from commercial quail industry in Yazd province of Iran and were fed *ad libitum* by standard grower diet throughout our experiment according to the national research council requirements [8].

**Virus Preparation:** The virus isolation was performed by injecting infected bird tissue (mucosal surface of trachea) homogenates into allantoic cavity of 10-day-old specific-pathogen-free embryonated chicken eggs, according to standard procedures [9] and avian influenza (H9N2) virus was isolated and named A/chicken/Iran/339/02. The titer of the propagated virus was then calculated as a median embryo infectious dose (EID<sub>50</sub>) per milliliter. The Reed and Muench method was used for virus titration [10]. This virus stock was used in current experiment.

**Birds and Avian Influenza Challenging:** A total of 50 quails at the age of 14 days were randomly divided into two groups of 25birds/group. Each group was reared in separate room, with similar environmental conditions, same availability of feeders and drinkers conditions, with separate ventilation systems and offered feed and drinking water *ad libitum* at the animal research unit of Shiraz university school. Before the experiment, rooms were vigorously washed and fumigated using formaldehyde. Before inoculation, birds were bled to confirm negative avian influenza infectious status. Each birds in group 2 (trial group) received at 43 days of age a similar challenge of H9N2-AIV field isolate. Briefly, each quails in trial group were intranasally inoculation with 10<sup>6.3</sup> embryo infectious dose/bird of A/chicken/Iran/ 339/02 (H9N2) isolate. Birds in group 1 (control group) received sterile allantoic fluid as a negative control. Birds were monitored daily for clinical signs and death until the end of study. Quails were anesthetized, then sacrificed on 42 (1 day before infection), 49 (6 days post-infection),

56 (13 days post-infection) and 66 (23 days post-infection) days of age in order to monitor the macroscopic and microscopic findings from birds of trial group in comparison to control group, sequentially. Tissue samples such as: trachea, lung, air sac, liver, spleen, kidney, pancreas, adren, cardiac system, skin, brain and intestine were fixed in 10% neutral formalin solution and then subjected for histopatological examination.

## RESULTS

No mortality was observed, clinical signs such as depression, ruffled feathers, diarrhea and nasal and eye discharges were observed on 49 and 56 days of age in some birds of trial group. Macroscopic findings were observed between days 6 and 13 after inoculation, these findings were not appreciable different. No macroscopic finding was determined in the quails slaughtered on day 23 after inoculation (not illustrated).

Macroscopic findings in trial group were mild in severity. Congestion and haemorrhagia were observed mostly in the respiratory system, liver and intestine. Trachea in some birds was moderately exudated, the content of the intestines was dilute and petechial haemorrhagia was observed in the intestines mucosal surface.

Microscopic findings varied from sever to mild in the trial group on days 6, 13 and 23 after inoculation, respectively. The hyperemia, edema and infiltration of lymphocytes, macrophages and heterophils were mostly observed in the respiratory systems, liver, spleen and

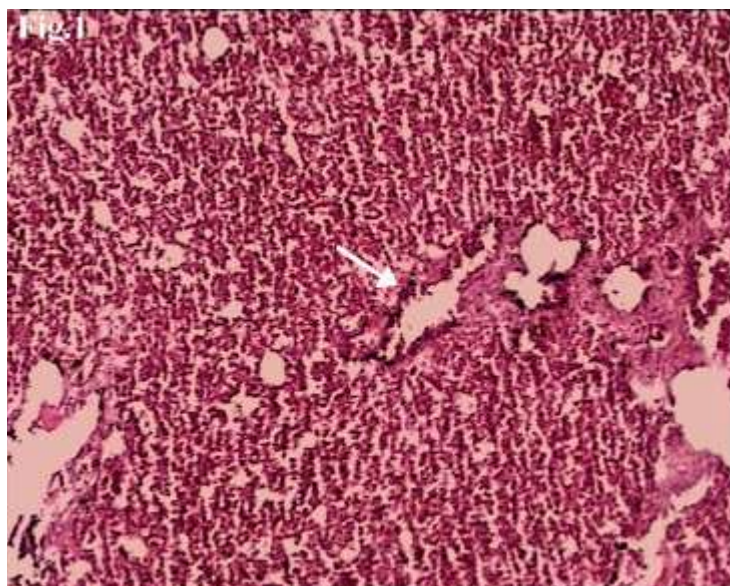


Fig. 1: Lung, inflammatory cells infiltration in the interstitial area with hemorrhage and edema of a quail infected with H9N2 of avian influenza virus subtype on day 6 post-infection, H&E×360.

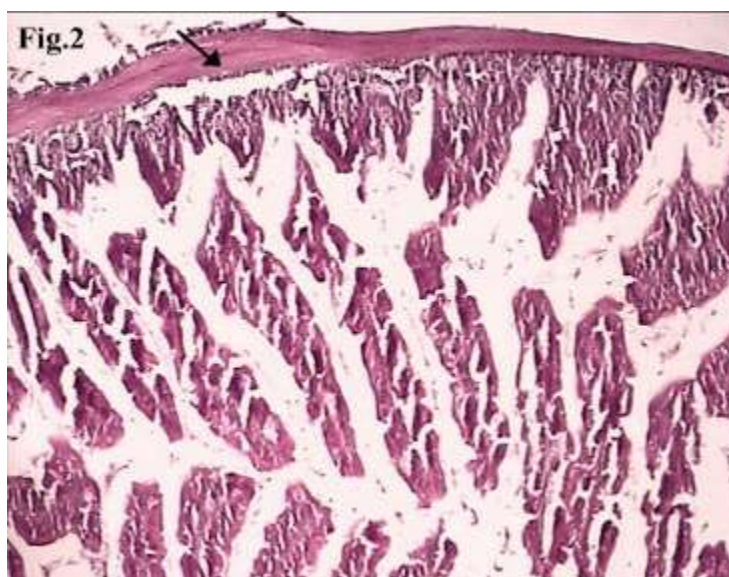


Fig. 2: Duodenum, Hyperemia, edema, hyperplasia and degeneration in cells of lamina epithelia were observed in quails infected with H9N2 of avian influenza virus subtype on day 13 post-infection, H&E×360.

intestines, but these findings were determined to be moderate in kidney and pancreas organs. However, no microscopic finding was observed in the skin, brain and cardiac system (not illustrated). Deciliation and sloughing were observed in the tracheal epithelium and microscopic findings in lung was considerable (Fig. 1). Hydropic degeneration, apoptosis, focal necrosis and kupffer cell activation were found in liver. Degeneration in cells of lamina epithelia, desquamation and hyperplasia were observed in the intestines (Fig. 2).

No macroscopic and microscopic findings were determined in the internal and external organs of the quails in the control groups (not illustrated).

## DISCUSSION

In this experimental study, the virus was isolated from the broiler farm which was showing obvious influenza clinical signs and mortality rated up to 30%, did not caused any mortality or disease in quails. It was reported that the severity of the disease depended whether the infection was natural or experimental. Although some avian influenza virus (AIV) strains caused sever systemic infection and high mortality in natural conditions and this virus strain caused only a mild infection without any mortality in the experimental study in chicken [11-13]. In an outbreak of H9N2 in Iran, mortality rate increased up to 65% in chickens [14], while experimental studies using all H9N2 AI viruses from the Middle East shown to have low or no mortality in chickens [15].

In this study, the mentioned macroscopic and microscopic findings were determined mostly in the respiratory system, liver, spleen and intestines of the quails to be sever more than other organ. Swayn *et al.* (1997) reported that in chickens the respiratory system, spleen, kidney and pancreas were affected in the low severity AIV infections; however, the skin, brain, cardiac and the adren were affected in the sever cases [16]. It seems there is a relation between the severity of the AIV infections and the tissue and organ tropism in avian species. It is reported that the occurrence of the disease syndrome or the degree of severity of the disease depends on multiple factors, including the pathogenicity of the virus, care and feeding conditions, the host species, age of the host, route of infection and existence of secondary bacterial infection [17-18].

This study determined that the respiratory and gastro intestinal system were affected more server than other organs and according to other study which indicated that the level of cell injuries has direct relation with accumulation of infection agents [19-20]. Therefore, these systems could be a major source of AIV shedding and transmitting viral particles to other birds and species.

The limitation of our study was that we did not consider chicken as a positive control group to be compared histopathologically with quails in negative control and trial groups. We did not follow the level of viral shedding on separate days after inoculation. Thus, further study will be needed to follow up the level of AIV in internal organs of quail and viral shedding on different days after inoculation.

Our study with H9N2 virus isolated from a broiler farm which was showing influenza clinical signs and mortality could not produce disease and mortality in quails. Hence, quails might have played role in the genetic reassortment or spread of the disease and cause economic losses in poultry industry and endanger public health.

#### ACKNOWLEDGMENTS

We acknowledge assistance provided by Mohamadi and Rezaei from avian disease department of Shiraz University Veterinary School. This research was supported by Avian Diseases Research Center of Shiraz University.

#### REFERENCES

1. Cameron, K.R., V. Gregory, J. Banks, I.H. Brown, D.J. Alexander, A.J. Hay and Y.P. Lin, 2000. H9N2 subtype influenza A viruses in poultry in Pakistan are closely related to the H9N2 viruses responsible for human infection in Hong Kong. *Viol.*, 278: 37-41.
2. Guan, Y., K.F. Shortridge, S. Krauss and R.G. Webster, 1999. Molecular characterization of H9N2 influenza viruses: were they the donors of the "internal" genes of H5N1 viruses in Hong Kong? *Proc. Natl. Acad. Sci. USA*. 96: 9363-67.
3. Liu, M., Y. Guan, M. Peiris, S. He, R.J. Webby, K. Perez and R.G. Webster, 2003. The quest of influenza A viruses for new hosts. *Avian Dis.*, 47: 849-56.
4. Guan, Y., K.F. Shortridge, S. Krauss, P.S. Chin, K.C. Dyrting, T.M. Ellis, R.G. Webster and M. Peiris, 2000. H9N2 influenza viruses possessing H5N1-like internal genomes continue to circulate in poultry in Southeastern China. *J. Virol.*, 74: 9372-80.
5. Chin, P.S., E. Hoffmann, R. Webby, R.G. Webster, Y. Guan, M. Peiris and K.F. Shortridge, 2002. Molecular evolution of H6 influenza viruses from poultry in Southeastern China: prevalence of H6N1 influenza viruses possessing seven A/Hong Kong/156/97 (H5N1)-like genes in poultry. *J. Virol.*, 76: 507-16.
6. Hoffmann, E., J. Stech, I. Leneva, S. Krauss, C. Scholtissek, P.S. Chin, M., Peiris, K.F. Shortridge and R.G. Webster, 2000. Characterization of the influenza A virus gene pool in avian species in southern China: was H6N1 a derivative or a precursor of H5N1? *J. virol.*, 74: 6309-15.
7. Makarova, N.V., H. Ozaki, H. Kida, R.G. Webster and D.R. Perez, 2003. Replication and transmission of influenza viruses in Japanese Quail. *Viol.*, 310: 8-15.
8. National research council, 1984. Nutrients requirements of poultry 8<sup>th</sup> revised edition. Washington, DC: National Academy Press, pp: 11-15.
9. Tumpey, T.M., D.L. Suarez, L.E. Perkins, D.A. Senne, J.G. Lee, Y.J. Lee, *et al.*, 2002. Characterization of a highly pathogenic H5N1 avian influenza A virus isolated from duck meat. *J. Virol.*, 76: 6344-55.
10. Reed, L.J. and H.A. Muench, 1938. Simple method for estimating fifty per cent endpoints. *American J. Hygiene*. 27: 493-97.
11. Brugh, M. and M.L. Purdue, 1991. Emergency of highly pathogenic virus during selective chicken passage of the prototype mildly pathogenic A/chicken/Pennsylvania/83 (H5N2) influenza virus. *Avian. Dis.*, 35: 824-33.
12. Naem, K. and M. Hussain, 1995. An outbreak of avian influenza in poultry in Pakistan. *Vet. Record.*, 137: 439-439.
13. Nili, H. and K. Asasi, 2002. Natural cases and an experimental study of H9 N2 avian influenza in commercial broiler chickens of Iran. *Avian. Pathol.*, 31: 247-252.
14. Vafsi, Marandi, M. and M.H. Bozorgmehrifard, 1999. An outbreak of non-highly pathogenic avian influenza chickens in Iran. *Proceedings of the 61st meeting of the world veterinary association*. Lyon, France.
15. Banks, J., E.C. Speidel, P.A. Haris and D.J. Alexander, 2000. Phylogenetic analysis of influenza A viruses of H9 hemagglutinin subtype. *Avian Pathol.*, 29: 353-60.
16. Swayne, D.E., 1997. Pathobiology of H5N2 Mexican avian influenza virus infections of chickens. *Vet. Pathol.*, 34: 557-67.
17. Brugh, M. and C.W. Beard, 1986. Influence of dietary calcium stress on lethality of avian influenza viruses for laying chickens. *Avian. Dis.*, 30: 672-678.
18. Swayne, D.E. and R.D. Slemons, 1994. Comparative pathology of a chicken-origin and two duck-origin influenza virus isolates in chickens: The effect of route inoculation. *Vet. Pathol.*, 31: 237-45.
19. Taubenberger, Jeffery, K. and M. Morens David, 2008. The Pathology of Influenza Virus Infections. *Annu Rev Pathol. Mech. Dis.*, 3: 499-522.
20. Capua, I. and D.J. Alexander, 2009. Avian influenza infection in birds: A challenge and opportunity for the poultry veterinarian. *Poult. Sci.*, 88: 842-846.