

Histological Characteristics of the Esophageal Wall of the Common Quail (*Coturnix coturnix*)

Ali Parchami and Rahmat Allah Fatahian Dehkordi

Department of Anatomical sciences, Faculty of Veterinary Medicine,
University of Shahrekord, Shahrekord, Iran

Abstract: The present investigation aimed to study the histomorphometric of the esophageal wall of the common quail (*Coturnix coturnix*). Five adult male and five adult female common quail were used in the experiment. Results showed that the overall histological characteristics of the esophageal wall in common quail is similar to those of the other birds. The muscularis mucosa which is a very well developed continuous layer is formed of smooth muscle fibers. The simple branched mucus glands are present in both cervical and thoracic parts of esophagus. The glands are less developed in the cervical part in comparison to thoracic part of the organ. An important characteristic feature of the esophagus in common quail is the presence of mucous glands in the crop. The tunica muscularis of esophagus is composed only of smooth muscle. In both sexes, the mean thickness of epithelium is significantly greater in crop as compared to thoracic part of esophagus ($p < 0.05$) and in cervical part as compared to thoracic part of the organ ($p < 0.05$). The mean thickness of the lamina propria is significantly lesser in crop as compared to both cervical and thoracic parts of the esophagus ($p < 0.05$). The mean thickness of the both circular and longitudinal layers is significantly greater in thoracic part as compared to crop and cervical part of esophagus ($p < 0.05$). There was no sex difference in histomorphometric properties of the esophagus in common quail.

Key words: Common quail • Esophagus • Esophageal glands • Morphometry

INTRODUCTION

The esophagus is a thin-walled distensible tube which transports food from the pharynx to the stomach allowing birds to swallow their food whole. Thus, it contains a number of longitudinal folds which provide distensibility. The avian esophageal wall consists of four layers: mucosal, submucosal, muscle tunic and the serosal layer and generally contains only smooth muscle cells, with a circular muscle layer predominating [1]. Unlike mammals, the avian esophagus divided into a cervical and thoracic region. In addition, the esophagus of birds lacks both upper and lower esophageal sphincters which are present in mammals [2]. In many, but not all (eg., gulls, penguins, ostriches), species of birds the cervical esophagus is expanded to form a crop. The crop functions to store food and may be spindle-shaped, bilobed, or unilobed. In the chicken, the crop is ventral diverticulum of the esophagus and contains longitudinal folds on the inner surface thus making it distensible. Beyond the crop,

the esophagus continues as the thoracic esophagus to connect with the proventriculus [3]. In the available literature, there is a lack of detailed histomorphometric data characterizing the microscopic properties of the esophageal wall in common quail. The aim of this study was therefore to describe these properties of the esophagus in this species at light microscopic level.

MATERIALS AND METHODS

Five adult male and five adult female common quail (*Coturnix coturnix*) were used in the experiment. After two weeks, the animals were deeply anesthetized by excess ether inhalation. Tissue samples were taken from the middle parts of cervical and thoracic regions of esophagus and crop. Samples were immersed immediately in 10% buffered formalin solution at room temperature during 48 hours and processed to embed in Paraffin. Paraffin-embedded sections were cut at 5 μ m and stained with haematoxylin-eosin. The mean thickness of the

epithelium, lamina propria, lamina muscularis mucosa, tunica submucosa and circular and longitudinal muscular layers were measured using an ocular micrometer. All stereological results were statistically evaluated by Student t-test. Results are reported as mean \pm SEM with a significance level of 0.05.

RESULTS

The esophagus of the common quail has three distinct anatomical portions: cervical part, crop and thoracic part. The cervical part of the esophagus is considerably larger than the thoracic part. The esophageal wall consist of the usual layers of a tubular digestive organs; i.e. tunica mucosa, tunica submucosa, tunica muscularis and tunica adventitia.

The tunica mucosa is lined with stratified squamous epithelium. The lamina propria is formed of loose connective tissue. Fine connective tissue fibers, fibroblasts and areas of lymphocyte infiltration can be seen in this layer. The muscularis mucosa which is a very well developed continuous layer is formed of smooth muscle fibers. The tunica submucosa is composed of loose connective tissue with larger blood vessels, lymphatics and nerve fibers. The simple branched mucus glands are present in both cervical and thoracic parts of esophagus. The glands are less developed in the cervical part in comparison to thoracic part of the organ. An important characteristic feature of the esophagus in common quail is the presence of mucous glands in the crop. The tunica muscularis of esophagus is composed only of smooth muscle and is composed of two distinct layers: an inner circular and an outer longitudinal layer. The circular layer is thicker than the longitudinal layer. The two layers are separated by connective tissue fibers in which runs a nerve plexus. The tunica adventitia is composed of loosely arranged connective tissue which binds the organ to surrounding tissues. Nerve fibers and blood vessels can be found in this layer. There was no sex difference in microscopic appearance of the esophagus in common quail.

Table 1 compare the morphometric features of the different parts of esophageal wall in common quail. The important observations are as follows:

In both sexes, the mean thickness of epithelium is significantly greater in crop as compared to thoracic part of esophagus ($p < 0.05$) and in cervical part as compared to thoracic part of the organ ($p < 0.05$).

In both sexes, the mean thickness of the lamina propria is significantly lesser in crop as compared to both cervical and thoracic parts of the esophagus ($p < 0.05$).

In both sexes, the mean thickness of the both circular and longitudinal layers is significantly greater in thoracic part as compared to crop and cervical part of esophagus ($p < 0.05$). There was also no sex difference in morphometric measures of the esophagus in common quail.

DISCUSSION

Results obtained from the present investigation showed that the overall histological characteristics of the esophageal wall in common quail is similar to those of the other birds. It is well stablished that the cervical and thoracic parts of the esophagus show differences in anatomical and physiological characteristics in birds. Our results showed that many simple branched mucus glands are present in both cervical and thoracic parts of esophagus. However the glands are less developed in the cervical part in comparison to thoracic part of the organ. In contrast to this finding, the esophageal glands tend to be numerous in the upper than in the lower esophagus in chickens [1]. The glands open into the lumen by simple ducts passing through the lining epithelium. Like the other birds and unlike the mammals, the esophageal glands of the common quail are situated in lamina propria. The esophageal glands are pronounced in humans, dogs and chickens, but are poorly developed in cats, rats and rabbits. They may be present throughout the length of the esophagus as in the dog or restricted in location, such as in the pig, where they are found cranially [4].

Table 1: Average micrometric measurements in μm of the esophagus in common quail.

Regions	Gender	Epithelium	Lamina propria	Muscularis mucosa	T. submucosa	T. muscularis (circular layer)	T. muscularis (longitudinal layer)
Cervical part	male	230 \pm 40	150 \pm 25	30 \pm 5	80 \pm 30	160 \pm 20	100 \pm 15
	female	250 \pm 20	165 \pm 25	20 \pm 5	85 \pm 20	180 \pm 30	110 \pm 20
Crop	male	270 \pm 30	60 \pm 10	25 \pm 5	40 \pm 10	150 \pm 25	90 \pm 20
	female	245 \pm 25	60 \pm 20	35 \pm 10	40 \pm 25	140 \pm 45	105 \pm 15
Thoracic part	male	160 \pm 20	120 \pm 30	30 \pm 5	50 \pm 20	240 \pm 30	150 \pm 20
	female	150 \pm 30	110 \pm 25	35 \pm 5	70 \pm 30	260 \pm 20	180 \pm 35

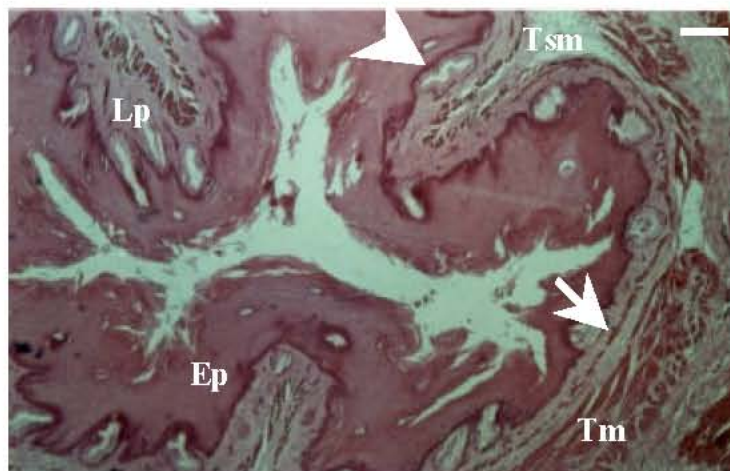


Fig. 1: Photomicrograph of the cervical part of esophagus in the common quail. Epithelium (Ep), Lamina propria (Lp), Muscularis mucosa (arrow), Tunica submucosa (Tsm), Tunica muscularis (Tm), Esophageal glands (arrowhead). (H and E, bar=150 μ m).

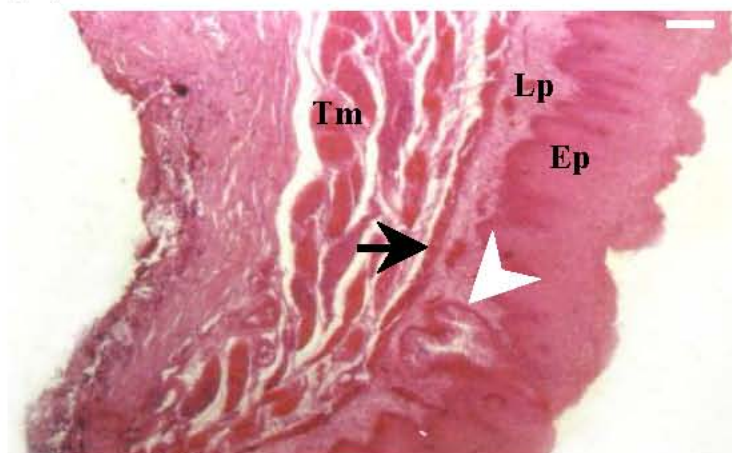


Fig. 2: Photomicrograph of the crop in the common quail. Epithelium (Ep), Lamina propria (Lp), Muscularis mucosa (arrow), Tunica muscularis (Tm), Crop gland (arrowhead). (H and E, bar=100 μ m).

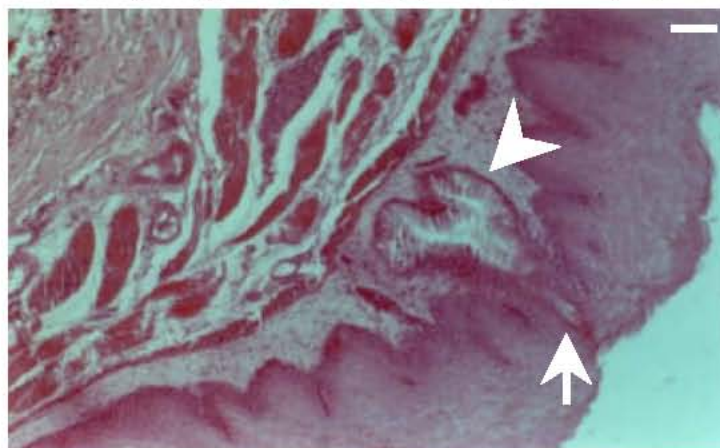


Fig. 3: Higher magnification of the crop in the common quail, showing a mucous gland (arrowhead) in lamina propria. Note the simple duct of the gland passing through the lining epithelium (arrow). (H and E, Bar=70 μ m).

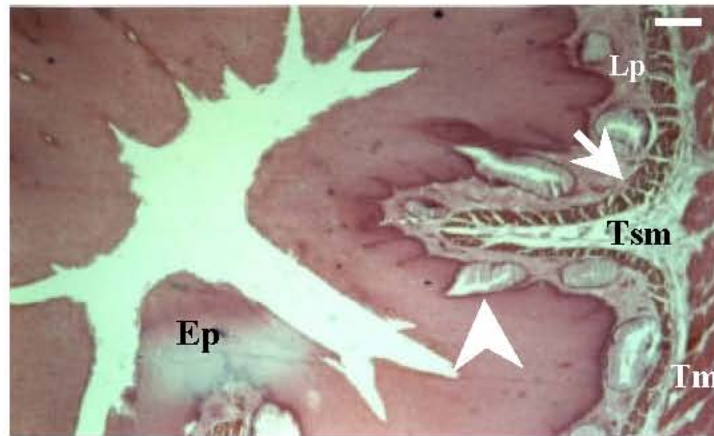


Fig. 4: Photomicrograph of the Thoracic part of the esophagus in the common quail. Epithelium (Ep), Lamina propria (Lp), Muscularis mucosa (arrow), Tunica submucosa (Tsm), Tunica muscularis (Tm), Crop gland (arrowhead). (H and E, bar=100 μ m).

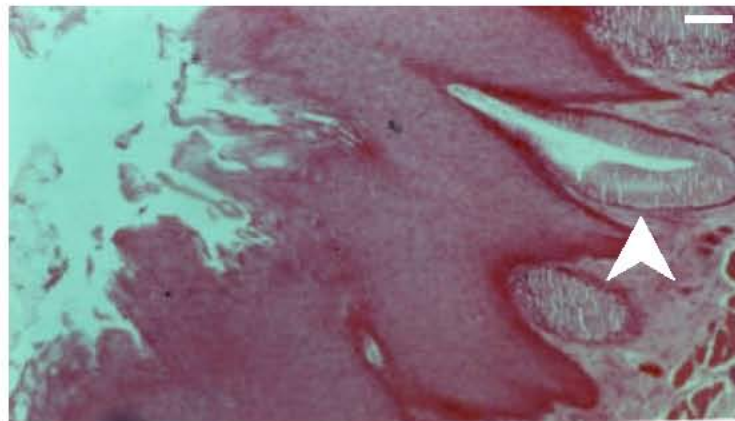


Fig. 5: Higher magnification of the thoracic part of the esophagus in the common quail. Note the esophageal mucous gland (arrowhead) in lamina propria of the organ (H and E, Bar=20 μ m).

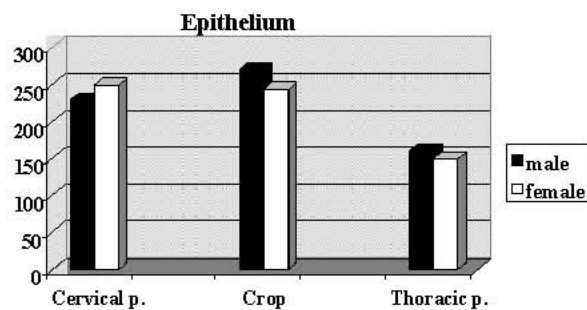


Fig. 6: Mean thickness of epithelium in different regions of the esophagus of the common quail.

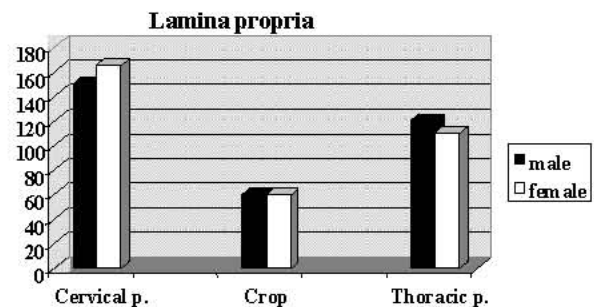


Fig. 7: Mean thickness of lamina propria in different regions of the esophagus of the common quail.

In many, but not all (eg., gulls, penguins, ostriches) species of birds the cervical esophagus is expanded to form a crop. The crop functions to store food and may be spindle-shaped, bilobed, or unilobed. In the chicken, the crop is ventral diverticulum of the esophagus and

contains longitudinal folds on the inner surface thus making it distensible [3]. Data obtained from the present study showed that an unusual finding of the crop in common quail is the presence of mucus glands in the lamina propria of the organ. Similar mucus glands have

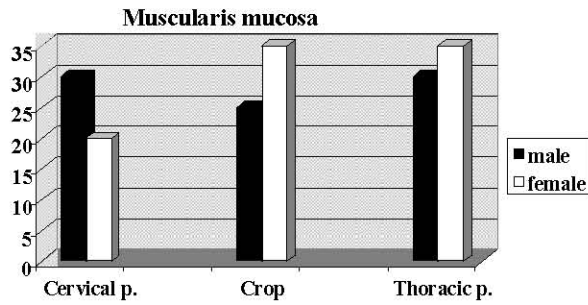


Fig. 8: Mean thickness of tunica muscularis mucosa in different regions of the esophagus of the common quail.

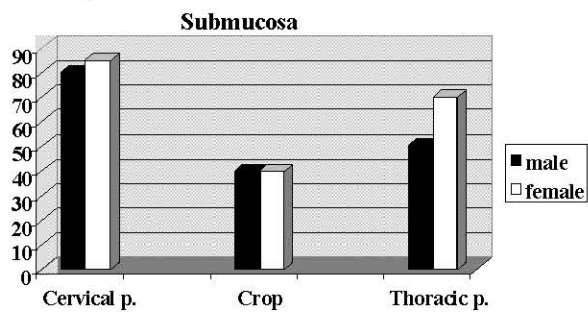


Fig. 9: Mean thickness of tunica submucosa in different regions of the esophagus of the common quail.

been reported in the crop of the chicken; however they are restricted to the junction of the crop and esophagus. The absence of secretory glands in the crop suggests that any digestion that may occur therein is caused either by enzymes already present in the food, by enzymes from micro-organisms or else by enzymes regurgitated from lower down the alimentary canal [1]. Some carbohydrate digestion may occur in the crop due to the presence of amylase activity in chickens [5]. Bolton (1965) [6] reported that starch is hydrolyzed within the crop where it can either be absorbed; converted to alcohol, lactic or other acids; or transported down to gastrointestinal tract. Substantial amylolysis occurs in the crop. Sucrose is also hydrolyzed within the crop. While absorption of sugars from the crop appears possible, it is probably minimal. In pigeons and doves, crop-milk is produced during the breeding season under the influence of prolactin [3]. During brooding, the large symmetrical crop of both male and female pigeons elaborates a crumbly material (crop milk) consisting of desquamated lipid-laden cells; mixed with ingested food, it is regurgitated and fed to the nestlings [7].

Data obtained from the present investigation also showed that the composition of muscle layers in common quail is similar to that of the chickens. It composed only

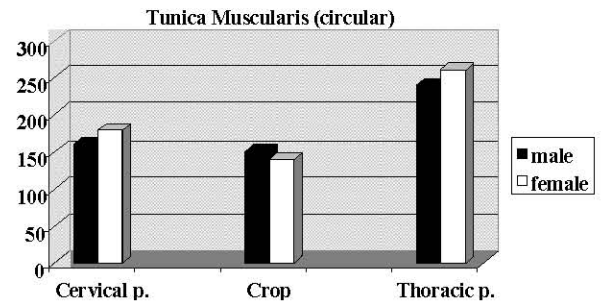


Fig. 10: Mean thickness of tunica muscularis (circular layer) in different regions of the esophagus of the common quail.

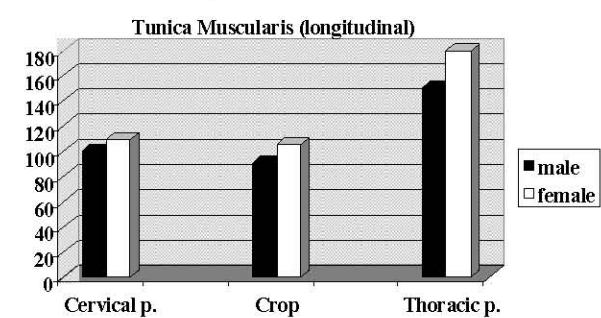


Fig. 11: Mean thickness of tunica muscularis (longitudinal layer) in different regions of the esophagus of the common quail.

of smooth muscle fibers throughout the esophagus. In many species of mammals, however, the two layers of tunica muscularis cranially consist of skeletal muscle that caudally is replaced by smooth muscle. In the porcine esophagus both types of muscle occur within the middle third or so of its length. By comparison, in the horse and the cat the transition area where skeletal muscle is replaced by smooth is located toward the caudal end of the esophagus. In dogs and ruminants the skeletal muscle is never replaced by smooth muscle [4].

Results obtained from morphometric findings of the present investigation showed that in both sexes, the mean thickness of epithelium is significantly greater in crop as compared to thoracic part of esophagus. Keeping in mind that the crop acts as a temporary reservoir for swallowed food, this finding may be due to the greater exposure of the epithelium of the crop with food particles compared to the other parts of the esophagus. Data obtained from the present study also showed that in both sexes, the mean thickness of the both circular and longitudinal muscular layers is significantly greater in thoracic part as compared to crop and cervical part of esophagus ($p < 0.05$). This finding disagree with those of Fatahian Dehkordi and Parchami (2011) [8] in native chickens who stated that the

thickness of the muscular layer was significantly greater in cervical part of esophagus than its thoracic part and in thoracic part of esophagus than crop. These differences might be due to the genetic variations in the different avian species. However more investigations are needed for precise explanation. Regarding gender differences in morphometric properties of the esophageal wall, our findings agree with that of Fatahian Dehkordi and Parchami in native chickens who stated that no statistically significant differences were found between male and female with respect to the thickness of the histological layers of the esophagus.

REFERENCES

1. Hodges, R.D., 1974. The histology of the fowl. Academic Press, pp: 45-47.
2. Mule, F., 1991. The avian oesophageal motor function and its nervous control: Some physiological, pharmacological and comparative aspects. *Comparative Biochem. Physiol.*, 99: 491-498.
3. Whittow, G.C., 2000. *Sturkie's Avian Physiology*. Academic press, New York, London, pp: 302-315.
4. Samuelson, D.A., 2007. *Textbook of veterinary histology*. Saunders Co., pp: 320-323.
5. Philips, S.M. and R. Fuller, 1983. The activities of amylase and a trypsin-like protease in the gut contents of germ-free and conventional chickens. *British Poultry Science*, 24: 115-121.
6. Bolton, W., 1965. Digestion in crop. *British Poultry Science*, 6: 97-102.
7. Dyce, K.M., W.O. Sack and C.J.G. Wensing, 1995. *Textbook of veterinary anatomy*. W.B Saunders Co. pp: 780-781.
8. Fatahian Dehkordi, R.A. and A. Parchami, 2011. Effects of sex and region on histomorphometrical structure of the esophagus in native chickens. *Iranian Veterinary Journal*, 6(3): 12-19.