Middle-East Journal of Scientific Research 25 (3): 511-517, 2017
ISSN 1990-9233

DOI: 10.5829/idosi.mejsr.2017.511.517

Glaucoma - a Survey on Prevalence

[1]T. Meera Devi aad [1]Mrs. M. Madhumalini

[1]Professor Department of Electronics and Communication and Engineering,
Kongu Engineering College, Erode, India
[2]Research Scholar, Department of Electronics and Communication and Engineering,
P.A College of Engineering and Technology, Pollachi, India

Abstract: Glaucoma is an eye disease associated with increased pressure within the eye (also known as elevated intraocular pressure or elevated IOP) which can cause blindness (loss of vision gradually) and damage to the structure of retina. The glaucoma is occurred due to high eye pressure which may cause the structural form changes of the Optic Nerve Head (ONH) and Retinal Nerve Fiber Layer (RNFL) thickness. The observable part of ONH which is the features of glaucoma such as disc, cup, neuroretinal rim, Parapapillary atrophy and blood vessels. Automatic analysis of retina images is becoming an important screening tool now days. This technique helps to detect various kind of risks and diseases of eyes. Several techniques are there to detect the abnormality of retina due to glaucoma. This survey describe a system which is mainly based on image processing and classification techniques for detection of glaucoma by comparing and measuring different parameters of fundus images of glaucoma patients and normal patients.

Key words: Glaucoma, Optic Nerve Head, Retina images, Image processing, Classification and Fundus images

INTRODUCTION

Glaucoma is the second leading cause of blindness worldwide [1]. It is characterized by a gradual loss of visual function to lead to blindness. Another feature associated with glaucoma is high pressure in the eye, changes in the structure of the Optic Nerve Head (ONH) and Retinal Nerve Fiber Layer (RNFL) thickness . In ONH structural changes may occur in some parts such as discs, cup, neuroretinal rim, blood vessels and parapapillary atrophy (PPA) [2].

The examination of ONH can be done directly by using the direct ophthalmoscope, indirect ophthalmoscope or use the posterior pole lens is equipped with a slit lamp [3]. When an expert does the examination of ONH directly, it can make the patient feel uncomfortable. To overcome this, the examination of ONH can be observed through a retinal image, where the image produced by some types of equipment, such as funduscopy, Confocal Scanning Laser Ophthalmoscopy (CSLO), Heidelberg Retina Tomograph (HRT) and Optical Coherence Tomography (OCT) [4]. Almost all examinations performed manually by an expert, allow any divergence accuracy of examination result due to the dependence on the domain knowledge of a different expert.

Early detection of glaucoma is needed because the early stages of the disease symptoms are not felt by most of the patients and slow progression of the disease. It causes, damage is already severe in the ONH when the disease is detected the current research about automatic detection of glaucoma has been developed. The study was developed in a different way, where the difference can be viewed from a number of areas including the use of the features, methods of segmentation, feature extraction techniques and methods of classification.

This paper are review about the automatic feature extraction technique in retinal images and provide an overview of the recent developments related to research automatic glaucoma detection.

Glaucoma: ONH or also called as disc is an elliptical-shaped area. On the inside of the disc, there is another elliptical-shaped area with smaller size is called a cup. For an area that is between disc and cup called as neuroretinal rim. Parapapillary atrophy (PPA) is an area

Corresponding Author: Mrs. M. Madhumalini, Research Scholar, Department of Electronics and Communication and Engineering, P.A College of Engineering and Technology, Pollachi, India.

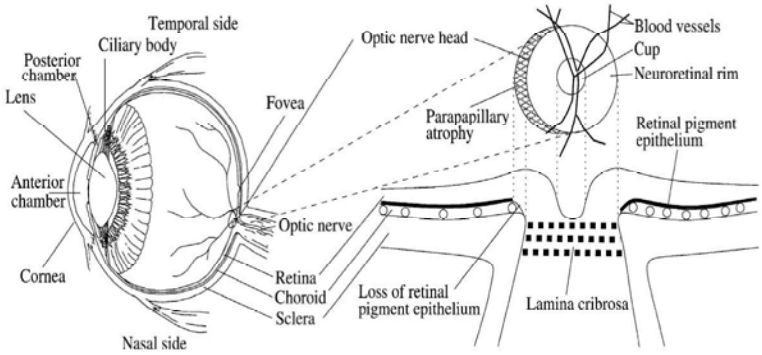

Fig. 1: Eye's Anatomy and Structure of ONH

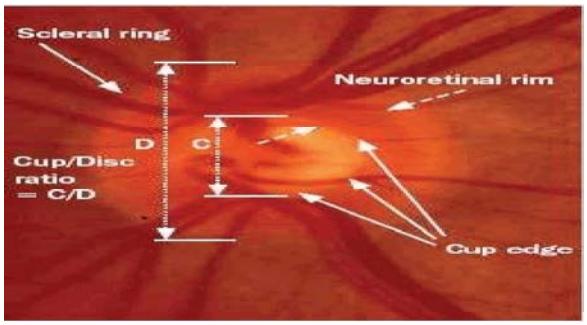

Fig. 2: Disc and Cup in Fundus Image

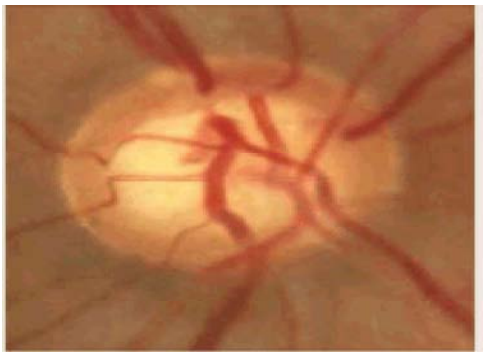

Fig. 3: Enlargement of Cup Size

that does not always appear on the retina which is located on the outside of the ONH, where the PPA is directly adjacent to the disc. The part that looks like hair and emerged from the middle of the area referred to as the ONH blood vessels [5].

Disc and cup are used to calculate the value of Cup-Disc Ratio (CDR). CDR is the value of a cup diameter divided by the diameter of the disc. CDR value can be calculated based on the diameter of the vertical or horizontal diameter of the disc and the cup. In 90% of normal eyes CDR-value of less than 0.5 the example of fundus image which present the diameter of disc and cup is shown in Figure 2

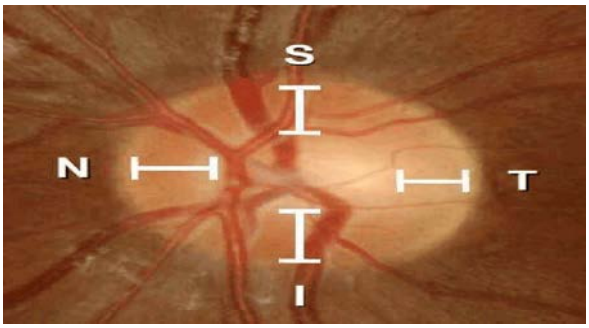

Fig. 4: ISNT Rule on the Right Eye

Enlargement of cup size is an early change that could affect the value of the CDR, where the value of the CDR can be used as a parameter to detect glaucoma disease. The example of cup size enlargement is shown in Figure 3.

The neuroretinal rim which is the area between the disc and the cup in the normal eye looks pink-orange and has a broad estimate of between 1.4 to 2.0 mm 2. It is divided into four parts: Inferior, Superior, Nasal and Temporal (ISNT). Inferior rim is the distance between the disc and the cup on the top, the superior rim is the distance between the disc and the cup on the bottom, nasal rim is the distance between the disc and the cup in the section close to the nose while the temporal rim is the distance between the disc and the cup opposite the nasal rim. The location of the ISNT for more details is shown in Figure 4. Cup in ONH is not positioned at the center, so that the thickness of each section neuroretinal rim area is different. Sequentially based on the thickest part is inferior, superior, nasal and temporal. Inferior is the thickest part while the temporal thinnest part. The order is based on the thickness of the basis ISNT rule.

PPA is a part with crescent-shaped, which consists of two types of alpha-zone and beta-zone. Alpha-zone is an area of hypopigmentation and hyperpigmentation. This part looks at the patient does not have the effect of

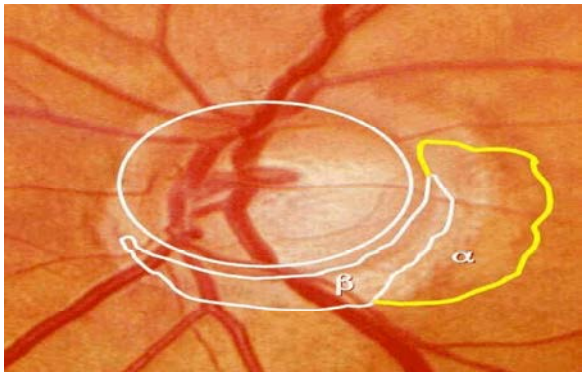

Fig. 5: PPA with Alpha-Zone and Beta-Zone On The Right Eye

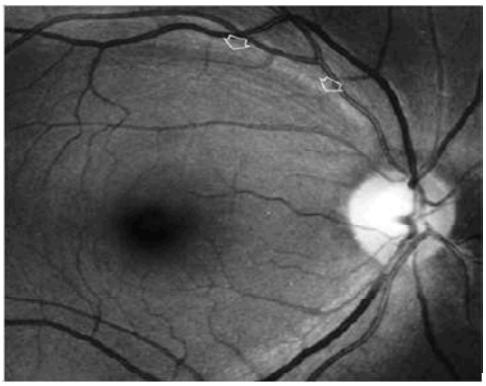

Fig. 6: Structure of RNFL

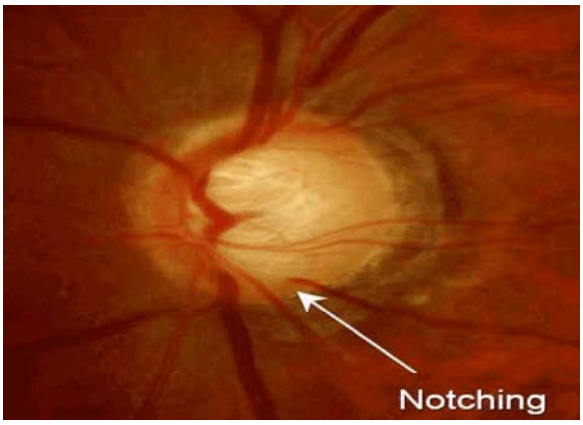

Fig. 7: Notching

myopia and glaucoma disease. A second type of PPA is beta-zone. It occurred more frequently in patients with glaucoma, which has the characteristic white color. Both types of PPA are located outside the area of the disc. Beta-zone is directly bordering the disc on the temporal side, while alpha-zone directly adjacent to the beta-zone [6]. The areas of alpha-zone and beta-zone are shown in Figure 5.

RNFL looks like a bunch of scratches that colored light is distributed evenly on the normal eye. In normal eye RNFL mostly seen in the inferior temporal area, followed in the area of the superior temporal, superior nasal and inferior nasal. RNFL can be observed by ophthalmoscopy and wide angle photos without the red color. The structure of the RNFL is shown in Figure 6.

Glaucoma Diagnosis: Diagnosing glaucoma may be based on several type of examination. The examination of glaucoma can be done by looking at the patient's medical history, Intraocular Pressure (IOP), visual ability test and observation of ONH manually using ophthalmoscopy or by observing the retinal image structures. Qualitative examination of the ONH can be done by using the ONH Stereo Photographs (ONHSPs), Confocal Scanning Laser Ophthalmoscopy (CSLO), Scanning laser polarimetry (SLP) and Optical Coherence Tomography (OCT) to distinguish normal eyes and glaucoma.Almost all examinations performed manually by an expert. The examination result has allowed difference accuracy due to the limitations and dependence domain knowledge from an expert.

Characteristics of Glaucoma: Normal eyes and glaucoma can be distinguished based on the changes in the ONH and RNFL. Enlargement of cup size can lead to changes the value of CDR and neuroretinal rim area becomes smaller. Area neuroretinal rim thinning (notching) make void the ISNT rule. The changes in the initial stages of neuroretinal rim are located on the inferior and superior rim. Figure 7 shows the thinning of neuroretinal rim in the inferior part.

Nerve fiber layer hemorrhage appears as a red line that is parallel or close to the surface area dics. Hemorrhage is possible contained in the neuroretinal rim area or PPA. Nerve fiber layer in normal eyes look like scratches are formed from a collection of axons in the retina, which is located around the neuroretinal rim to PPA. In the eyes of glaucoma nerve fiber layer thinning and become unclear [7]

Type of Features: Research about detection or classification of glaucoma using retinal image is influenced by the selection of features and feature extraction techniques. Feature extraction technique in retinal images are classified based on the type of the features. The type of feature is divided into two groups namely morphological and non-morphological.

To get the morphological feature we need segmentation process before measuring the geometric parameters. The examples of the morphological features are RNFL, PPA and the part of ONH such as disc and cup. After segmentation process produce the disc and cup boundary we can use them to calculate the values of disc and cup diameter, disc and cup area, CDR and neuroretinal rim area.

Non-Morphological feature is a feature that is no need segmentation process or extracted from the existing image (Image-based featured). Color, shape and texture are type of features that captured from the existing image. So it can be represented the characteristic of glaucoma disease. Color feature can be used to extract such as cup, neuroretinal rim, PPA to represent the characteristics. The blood vessels, neuroretinal rim and PPA can be extracted to represent characteristic based on shape feature, while RNFL can be extracted by texture feature.

Research about Glaucoma: Huiqi Li *et al* (2003) proposed algorithms to extract features automatically and robustly in color fundus images. PCA is employed to locate optic disk. A modified ASM is proposed in the shape detection of optic disk. A fundus coordinate system is established based on the fovea localization. An approach to detect exudates by the combined region growing and edge detection is proposed. The success rates of disk localization, disk boundary detection and fovea localization are 99%, 94% and 100% respectively. The sensitivity and specificity of the exudates detection are 100% and 71% correspondingly. The success of the proposed algorithms can be attributed to the utilization of the model-based methods. The satisfactory feature detection could make the automatic analyzing system become more reliable.

Cheng *et al*. (2004) proposed a new technique for glaucoma detection based on RetCam. In this study, for glaucoma detection RetCam is used which is an imaging modality that captures the image of irridocorneal angle. The manual grading and analysis of the RetCam image is quite a time consuming process. In this study, they developed an intelligent system for analysis of iridocorneal angle images, which can distinguish between open angle glaucoma and closed angle glaucoma automatically.

Research about glaucoma detection with morphological features has been done by Chrastek *et al*. (2005). It used several features that were CDR, Neuroretinal rim and PPA to detect glaucoma. To extract these features were used morphological method for localizing ONH, Hough transform to limit the search space and active contour models to find the end of the boundary line. The experiment was performed on 159 numbers of images (normal and glaucoma). The accuracy achieved in this study was 73.2% using the Linear Discriminant Analysis (LDA), 75.8% using Ctree and bagging 77.8%.

Several studies using CDR features to detect glaucoma was performed by Xu *et al* (2007). To obtain the value of CDR was require disc and cup segmentation process. In this study the segmentation process performed by detecting the cup and disc boundary with free-form deformable model (snake) technique. Boundary was extracted based on combination of some of the information that is smoothness, gradient, depth and other information. The algorithm used is to modify the original snake technique. The method is applied to 100 retinal fundus images having both normal and glaucoma taken from the National University Hospital. Accuracy for boundary detection in this research was 94%.

Optic disc segmentation process was done with the information integration of the local image that was around a point of interest into a multi-dimensional feature space. Next, the cup segmentation was done by anatomical features such as vessel bends at the cup boundary. Through this stage the resulting accuracy of two things were 91% for cup-to-disc vertical diameter ratio and 87% for cup-to-disc area ratio. The dataset consist of 33 normal and 105 glaucoma (total of 138) images.

They have used the dataset from database ORIGA light consisting of 625 retinal fundus images, where the data consists of 168 glaucoma images and 457 normal images. The dataset was randomly divided into two sections each of 325 data is used for training and the rest for the testing process. Selection of training and testing data randomly produced accuracy of 92% for segmentation disc and 81% for segmentation cup. The optic disc and cup segmentation is done based on the statistical model-based methods. Segmentation optic disc and cup performed by merging knowledge-based Circular Hough Transform and optimal channel selection

Another method that can be applied to disc and cup segmentation process consists of three stages. First, applied K-means clustering method, next stage was boundary process using Multi thresholding, Active Contour Method, Fuzzy C Means Clustering and ANN then performed morphological operations to fill the holes and a small part in the cluster of optic disc and cup. Third, Ellipse Fitting is used to mark the optic disc and cup boundary. This study used fundus image as input data.

The method was tasted on 10 images consisting of normal and glaucoma fundus image. The accuracy reached 97.77% using ANFIS, 98.12% and 97.35% using SVM using Back propagation.

The superpixel classification methods can be used to segment the optic disc and cup. Optic disc segmentation process for classifying each superpixel including disc / non-disc used histograms and statistical surround center (CSC). This method produced accuracy reached 90.5%. The cup segmentation also used histograms and CSC, the location information is also included as features and the accuracy result reached 85.9%. The dataset was used consist of 2326 retinal fundus images. The data taken from two different place, first from Singapore Malay Eye Study (Simes) with 3072x2048 pixel size as 650 data (168 glaucoma and 482 normal). Second, from the Singapore Chinese Eye Study (SCES) 1676 data (46 glaucoma and normal 1630).

Mei-Ling Huang *et al*. (2007) developed an automated classifier based on adaptive neuro-fuzzy inference system (ANFIS) which differentiate between normal and affected eyes. Stratus optical coherence tomography (OCT) technique was used for calculation of glaucoma variables (optic nerve head topography, retinal nerve fiber layer thickness). Decision making was performed in two stages: feature extraction using the orthogonal array and the selected variables were treated as the feeder to adaptive neuro-fuzzy inference system (ANFIS), which was trained with the back-propagation gradient descent method in combination with the least squares method. With the Stratus OCT parameters used as input, receiver operative characteristic (ROC) curves were generated by ANFIS to classify eyes as either glaucomatous or normal. The mean deviation was -0.67±0.62 dB in the normal group and -5.87±6.48 dB in the glaucoma group. The inferior quadrant thickness parameter was used for distinguishing between normal and glaucomatous eyes.

Wong *et al*. (2008), proposed Optic Cup and Disk Extraction from Retinal Fundus Images for Determination of Cup to Disc Ratio. They proposed a method for automatic Cup to Disc Ratio (CDR) determination. First the optic disc is extracted by variation level-set method. Then they compared the performance of a Threshold based Level Set method against a Color Intensity Threshold based approach towards the extraction of the optic cup. Next step is cup segmentation. It first identifies a point in the optic disc that contains the cup. Using the color intensity information from the chosen point, the cup region is obtained when the pixels corresponding to the cup have been selected. The cup boundary is determined by threshold and then applying the level-set method to optimize the detected cup contour.

Zhuo Zhang *et al*. (2009) proposed a convex hull based ellipse optimization algorithm for a more accurate detection of neuro-retinal optical cup. Comparing with the state-of-the-art ARGALI system, the new approach achieves a better CDR value calculation, which results to more accurate Glaucoma Diagnosis. The good performance of the new approach leads to a large scale clinical evaluation involving 15 thousand patients from Australia and Singapore

Gunduz (2009) *et al*, they explained about Correntropy is a kernel-based similarity measure which contains the information of both statistical and temporal structure of the underlying dataset. Correntropy makes use of kernel methods, its estimation is computationally efficient. This can be employed as a discriminative measure for detecting nonlinear characteristics in time series. Results of tests performed on data collected from natural systems are in agreement with findings in time series analysis literature.

Nayak (2009) *et al*, Glaucoma Detection using digital fundus images. Digital image processing techniques, such as preprocessing, morphological operations and thresholding, are widely used for the automatic detection of optic disc, blood vessels and computation of the features. We have extracted features such as cup to disc (c/d) ratio, ratio of the distance between optic disc center and optic nerve head to diameter of the optic disc and the ratio of blood vessels area in inferior-superior side to area of blood vessel in the nasal-temporal side. These features are validated by classifying the normal and glaucoma images using neural network classifier.

Bock *et al*. (2010) developed the research by modifying the feature extraction method. The feature extraction methods were used such as the value of intensity pixel rows, FFT and Bspline methods, then reduced the size of the features dimensions using PCA. This research made the Glaucoma Risk Index (GRI) system using two-stage classification scheme to combined different features (fraw, ffft, fspline) in the first stage classification, then in the next stage the features normalized become one feature as fp. This research used 575 experimental data (239 glaucoma and 336 normal images). The accuracy of Area under Convergence (AUC) reached 80% and GRI reached 88%.

Joshi *et al*. (2011) developed an automated OD parameterization technique depending on segmented OD and cup regions which are collected from monocular

retinal images. An OD segmentation technique is developed which works by integrating the information of local images around each point of interest in multidimensional feature space. This technique is quite robust against any form of variations found in the OD region. They utilized a cup segmentation technique depending on anatomical information such as vessel bends at the cup boundary, which is quite vital as considered by glaucoma experts. The bends in a vessel can be easily detected by utilizing a region of support concept, which helps in selecting the right scale for analysis. In this study, a multi-stage strategy is used to find a reliable subset of vessel bends called r-bends, which is followed by a local spline fitting in order to find the desired cup boundary.

Mookiah (2012) *et al*, explained the system for the automated identification of normal and glaucoma classes using Higher Order Spectra (HOS) and Discrete Wavelet Transform (DWT) features. The extracted features are fed to the Support Vector Machine (SVM) classifier with linear, polynomial order and Radial Basis Function (RBF) to select the best kernel function for automated decision making. In this work, SVM classifier with kernel function of polynomial order 2 was able to identify the glaucoma.

Jiang Liu *et al*. (2013)4designed automated glaucoma detection technique through medical imaging informatics (AGLAIA-MII) that takes into consideration everything starting from patient personal data, patient's genome information for screening and medical retinal fundus image. The AGLAIA-MII architecture uses information from multiple sources, including subjects' personal data, imaging information from retinal fundus image and patients' genome information. Features from each data source will be extracted automatically. Subsequently, these features will be passed to a multiple kernel learning (MKL) framework to generate a final diagnosis outcome. AGLAIA-MII achieved an area under curve value of 0.866, which is much better than 0.551, 0.722 and 0.810 obtained from the individual personal data, image and genome information components, respectively.

This methodology had shown a substantial improvement over the previous glaucoma detection techniques depending on intraocular pressure performed in two stages: feature extraction using the orthogonal array and the selected variables were treated as the feeder to adaptive neuro-fuzzy inference system (ANFIS), which was trained with the back-propagation gradient descent method in combination with the least squares method. With the Stratus OCT parameters used as input, receiver operative characteristic (ROC) curves were generated by ANFIS to classify eyes as either glaucomatous or normal. The mean deviation was -0.67±0.62 dB in the normal group and -5.87±6.48 dB in the glaucoma group. The inferior quadrant thickness parameter was used for distinguishing between normal and glaucomatous eyes.

Gilles (2014) *et al*, explained the Empirical Mode Decomposition (EMD). It decomposes a signal accordingly to its contained information. Its adaptability seems useful for many applications, this approach to build adaptive wavelets. The main idea is to extract the different modes of a signal by designing an appropriate wavelet filter bank. This construction leads us to a new wavelet transform, called the empirical wavelet transform.

Acharya (2015) *et al*, Automated glaucoma diagnosis method using various features extracted from Gabor transform applied on digital fundus images. The features are ranked using various ranking methods namely: Bhattachaiyya space algorithm, t-test, Wilcoxon test, Receiver Operating Curve (ROC) and entropy. In this work, t-test ranking method yielded the highest performance with an average accuracy of 93.10%, sensitivity of 89.75% and specificity of 96.20% using 23 features with Support Vector Machine (SVM) classifier.

CONCLUSION

From the review of the above papers and different features, it can be concluded that many different techniques can be used to detect glaucoma using different features. Glaucoma is a primary cause of permanent blindness. Hence, the detection and diagnosis has to be done in its earlier stages. Lot of recent research is being carried for detection of Glaucoma using fundus images, but still detection of progression of Glaucoma in patient remains to be researched. In future, we need to develop more accurate, robust as well as affordable automated techniques for glaucoma detection so that the benefits are passed on the poorest of poor people. Once glaucoma is correctly diagnosed then they can take proper medicine or undergo surgery in a timely manner to avoid total blindness.

REFERENCES

1. Quigley, H.A., 1996. Number of People with Glaucoma Worldwide, pp: 389-393.
2. Krieglstein, G. and R. Weinreb, 2009. Glaucoma Progress III (Essentials in ophthalmology). Berlin Heidelberg: Springer-Verlag, 2009.

3. Bourne, R.R.A., 2006. GLOSSARY The Optic Nerve Head In Glaucoma, COMMUNITY EYE Heal., 19(59): 44-45.
4. Hoffmann, E.M., L.M. Zangwill, J.G. Crowston and R.N. Weinreb, 2007. Optic Disk Size and Glaucoma, 52(1).
5. Chrastek, R., M. Wolf, K. Donath, H. Niemann, D. Paulus, T. Hothorn, B. Lausen, R. Lammer, C. Mardin and G. Michelson, Automated Segmentation of the Optic Nerve Head for Diagnosis of Glaucoma, Medical Image Analysis, 9: 297-314.
6. Choplin, N.T. and D.C. Lundy, Eds., 2007. Atlas of Glaucoma, Second Edition London: Information Healthcare, 2007.
7. Morrison, C.J. and P.I. Pollack, 2003. Glaucoma Science and Practice", Thieme Medical Publishers, Inc, 2003.
8. Huiqi Li and Opas Chutatape, 2003. A Model- Based Approach for Automated Feature Extraction in Fundus Images, Proceedings of the ninth IEEE International Conference on Computer Vision (ICCV 2003) 2-Volume Set 0-7695-1950-4/03, 2003.
9. Jun Cheng, Jiang Liu and Beng Hai Lee, 2004. Closed Angle Glaucoma Detection in RetCam Images, IEEE Proceedings of the 32nd Annual International Conference, pp: 4096-4099.
10. Chrastek, R., M. Wolf, K. Donath, H. Niemann, D. Paulus, T. Hothorn, B. Lausen, R. Lammer, C. Mardin and G. Michelson, 2005. Automated Segmentation of the Optic Nerve Head for Diagnosis of Glaucoma, Medical Image Analysis, 9: 297-314.
11. Xu, J., O. Chutatape, E. Sung, C. Zheng and P.C.T. Kuan, 2007. Optic Disk Feature Extraction Via Modified Deformable Model Technique for Glaucoma Analysis, Pattern Recognition, 40: 2063-2076.
12. Mei-Ling Huang, Hsin-Yi Chen and Jian-Jun Huang, 2007. Glaucoma detection using adaptive neuro-fuzzy inference system, Expert Systems with Applications, 32: 458-468.
13. Zhuo Zhang, Jiang Liu, Neetu Sara,Cherian, Ying Sun, Joo Hwee Lim, Wing Kee Wong, Ngan Meng Tan, Shijian Lu, Huiqi Li and Tien Ying Wong, 2009. Convex Hull Based Neuro-Retinal Optic Cup Ellipse Optimization in Glaucoma Diagnosis, 31st Annual International Conference of the IEEE EMBS Minneapolis, Minnesota, USA, September 2-6, 2009.
14. Gunduz, A. and J.C. Principe, 2009. Correntropy as a novel measure for nonlinearity tests,' Signal Processing, 89(1): 14-23.
15. Nayak, J. Acharya, U. R. Bhat, P. S. Shetty, N. and Lim, T. C. (2009), 'Automated diagnosis of glaucoma using digital fundus images,'Journal of Medical Systems, vol. 33, no. 5, pp. 337-346.
16. Bock, R., J. Meier, L.G. Nyúl, J. Hornegger and G. Michelson, 2010. Glaucoma risk index?: Automated Glaucoma Detection from Color Fundus Images, Medical Image Analysis, 14(3): 471-481.
17. Gopal Datt Joshi and Jayanthi Sivaswamy, 2011. Optic Disk and Cup Segmentation From Monocular Color Retinal Images for Glaucoma Assessment, IEEE Transactions On Medical Imaging, pp: 1192-1205.
18. Jiang Liu, Zhuo Zhang, Damon Wing Kee Wong, Yanwu Xu, Fengshou Yin, Jun Cheng, Ngan Meng Tan, Chee Keong Kwoh, Dong Xu, Yih Chung Tham, Tin Aung and Tien Yin Wong, 2013. J. Am. Med. Inform. Assoc., 0: 1-7.
19. Gilles, J., G. Tran, and S. Osher, 2014. 2D empirical transforms. Wavelets, ridgelets and curvelets revisited, SIAM Journal on Imaging Sciences, 7(1): 157-186.
20. Acharya, U.R., L.W.J. Eugene, K. Noronha, L.C. Pmin, L.P. Nayak and S.V. Bhandary, 2015. Decision support system for the glaucoma using Gabor transformation', Biomedical Signal Processing and Control, 15: 18-2.