

Effect of Diclazuril, Semduramicin, Salinomycin and Maduramycin as Preventive Anticoccidial Drugs on Chicken Intestinal Morphology

¹Hossein Hassanpour, ²Shahab Bahadoran, ²Sanaz Koosha, ²Elaheh Askari and ²Sima Homai

¹Department of Basic Sciences (Physiology Division),
Faculty of Veterinary Medicine, Shahrekord University, Shahrekord, Iran

²Department of Clinical Sciences, Faculty of Veterinary Medicine,
Shahrekord University, Shahrekord, Iran

Abstract: To determine the effect of four anticoccidial drugs, on the normal intestinal mucosa, broiler chicks were reared since they were 1-Day old and treated by diclazuril, semduramicin, salinomycin and maduramycin (1, 20, 60 and 5 mg/kg of diet, respectively) for 3 weeks. Segments from the duodenum, jejunum and ileum were collected for morphometric analysis. There were negative effects on growth and feed conversion in chickens treated by these drugs after 4 weeks. These drugs decreased villous length, width and surface area, mostly in the duodenum and jejunum. There was also a reduction of the lamina propria thickness in the intestine by anticoccidials except semduramicin which increases lamina propria. The effect of anticoccidial drugs in the muscle layer was different. It appeared that semduramicin consistently increased it in the three parts of the intestine. It is concluded that four anticoccidial drugs, diclazuril, semduramicin, salinomycin and maduramycin have adverse effects on chicken performance and intestinal morphology, especially villus dimensions and absorptive surface. There was also evidence for involvement of these drugs in the intestinal motility and secretion.

Key words: Intestinal morphology • Broiler chicken • Anticoccidial drugs

INTRODUCTION

The coccidia consist of a wide variety of single celled, parasitic animals in the subkingdom Protozoa of the phylum *Apicomplexa*. As a group, the coccidia of the genus *Eimeria* are predominately host-specific; i.e., each species occurs in a single host species or a group of closely related hosts. The species of coccidia in the chicken all invade the lining of the intestine or ceca [1,2].

Coccidiosis in broiler chicken is a permanent problem in the worldwide. In spite of the improvement of management and zoohygienic conditions in broiler growing in recent years, outbreaks of coccidiosis still occur [3,4].

High-intensity rearing systems, particularly in the poultry industry, have resulted in a dependence on anticoccidial feed additives to provide prophylactic control against protozoal infections caused by

pathogenetic species of *Eimeria*. Nine species of coccidia belonging to the genus *Eimeria* are known to infect poultry that are most susceptible, due to the warm humid environment created in intensive rearing units on modern farms [5]. The degree of pathogenesis caused by each species of *Eimeria* varies. The most pathogenic species in chickens are these are *Eimeria acervulina*, *E. brunetti*, *E. maxima*, *E. mitis*, *E. necatrix*, *E. praecox* and *E. tenella* which can give rise to specular outbreaks of disease [1,4].

In the modern broiler industry, efficient control of coccidiosis is still of the greatest importance for obtaining profitable production. The resilience of the oocyst necessitates chemoprophylaxis by the use of anticoccidial drugs. Since the introduction of the sulphonamides in the early forties, the development and introduction of a continual succession of these and other drugs have been more or less successful in preventing serious economic loss from the disease [6,7].

At the present study, the effects of four anticoccidial drugs (semduramicin, salinomycin and maduramycin as polyether ionophores; diclazuril as chemical drug) were evaluated on the performance and intestinal morphology of healthy broiler chicken. These selected drugs are the most common anticoccidials used in the poultry industry of Iran as prophylactic agents against clinical and subclinical coccidiosis.

MATERIALS AND METHODS

Animals, Management and Treatments: Forty five, one-day-old fast-growing chickens from Ross 308 breed were randomly divided into five equal groups with three replicates per group (9 birds per group) (one control and four treatment groups). Chicks were reared at standard condition for four weeks and provided *ad libitum* access to water and a standard ration (Starter: 32 MJ metabolisable energy (ME)/kg of diet, 230g/kg crude protein (CP), Grower: 32 MJ metabolisable energy (ME)/kg of diet, 200g/kg CP formulated to meet requirements for broilers [8]. At treatment groups, diclazuril, semduramicin, salinomycin and maduramycin were added to the basal diet at 1, 20, 60 and 5 mg/kg of diet, respectively and fed to the birds from second week (for 21 days).

Feed consumption and body weight and weight gain were recorded in the each group, feed conversion were calculated at the end of experiment. The study was approved by the Ethics Committee of Shahrekord University.

Morphometric Analysis of the Intestine: The intestinal morphometric variables evaluated were villus sizes (height, width, surface area and lamina propria thickness) from the duodenum, jejunum and ileum. After 28 days of age, 6 chicks from each group were killed by decapitation. 2-cm segments of the midpoint of the duodenum (duodenum), the midpoint between the bile duct entry and Meckel's diverticulum (jejunum) and the distal end of the lower ileum (ileum) were dissected. The segments were flushed with phosphate buffered saline (PBS, PH 7), fixed in Clark fixative for 45 min. and then left in ethyl alcohol for longer storage. Each segment was divided into 3 sections along its length. Sections were left in periodic acid Schiff (PAS) reagent for 2-3 min., rows of villi were cut in thickness of the sections, transferred over the glass slides and covered with a cover-slip. These samples were examined by a microscope with eyepiece

graticules (10×) and magnification of ×100 [9]. The villus height was measured from the top of the villus to the top of the lamina propria. Surface area was calculated using the formula $= (2\pi) \times (VW/2) \times (VL)$ in which VW = villus width and VL = villus length [10]. The lamina propria thickness was measured at the space between the base of the villus and the top of the muscularis mucosa. The muscle layer was measured from the top of the muscularis propria to the serosa [11]. This experiment was done for 9 birds / treatment in three replications. In each bird, three segments of each one of the duodenum, jejunum and ileum was examined.

Statistical Analysis: All results are represented as mean \pm SEM. Comparisons were made using one way ANOVA with Tukey's post hoc test (SPSS-14.0 package). P values less than 0.05 were considered statistically significant.

RESULTS

Bird Performance of the Anticoccidial Drugs- Treated Groups: Effects of diclazuril, semduramicin, salinomycin and maduramycin individually, on the performance of broiler chickens are presented in Table 1. The parameters of bird performance were only presented for the last week of rearing (14-28 days of age); in previous weeks, these parameters were insignificant. Individual additions of these anticoccidial drugs significantly ($P<0.05$) decreased the weight gain and body weight and increased feed conversion rate (FCR), of course increasing of FCR only was insignificant in diclazuril-treated group compared with the control. The weight gain and body weight were lowered by diclazuril, semduramicin, salinomycin and maduramycin, respectively about 17.2% and 11.8%, 17.2% and 12.1%, 23.3% and 15.8% and 26.9% and 18.7%. The FCR were increased in the groups treated by diclazuril, semduramicin, salinomycin and maduramycin about 11.2%, 12.9%, 12.4% and 21.2%, respectively. Feed intake of birds fed on the diets supplemented with these drugs did not changed compared with control. These parameters in the previous weeks.

Morphometric Analysis of Intestine: The duodenum villus height, width, lamina propria thickness, muscle layer and surface area were significantly ($P<0.05$) lower in all anticoccidial drugs-treated groups than the control after 28 days (Table 2 and Figure 1).

Table 1: Effect of anticoccidial drugs on chicken performance

	n	Body Weight (g) (28 days)	Weight gain (g) (14-28 days)	Feed intake (g) (14-28 days)	FCR (14-28 days)
Control	6	1020.8 ± 15.7 ^a	702.8 ± 15.5 ^a	1194.7 ± 44.2 ^a	1.70 ± 0.06 ^a
Diclazuril	6	900.9 ± 27.2 ^b	581.8 ± 27.3 ^b	1100.3 ± 52.4 ^a	1.89 ± 0.02 ^{ab}
Semduramicin	6	897.0 ± 14.4 ^b	581.9 ± 15.1 ^b	1115.5 ± 13.4 ^a	1.92 ± 0.07 ^b
Salinomycin	6	859.7 ± 25.5 ^{bc}	539.3 ± 26.0 ^{bc}	1026.7 ± 15.2 ^a	1.91 ± 0.08 ^b
Maduramycin	6	830.3 ± 9.1 ^c	513.5 ± 6.1 ^c	1056.0 ± 35.7 ^a	2.06 ± 0.60 ^b

^{a,b,c} Means with the different indices between groups are significantly different for $p < 0.05$

Table 2: Intestinal morphology in chickens treated by four anticoccidial drugs

		Villus dimensions			
	Groups	Height (mm)	Width (mm)	Lamina propria (mm)	Muscle layer (mm)
Duodenum	Control	1.00±0.043 ^a	0.76±0.041 ^a	0.77±0.031 ^a	0.22±0.024 ^a
	Diclazuril	0.78±0.061 ^b	0.55±0.032 ^b	0.47±0.034 ^b	0.30±0.024 ^b
	Semduramicin	0.84±0.051 ^b	0.54±0.031 ^b	0.39±0.020 ^b	0.31±0.022 ^b
	Salinomycin	0.55±0.033 ^c	0.64±0.047 ^c	0.15±0.017 ^c	0.14±0.012 ^c
	Maduramycin	0.55±0.034 ^c	0.56±0.039 ^b	0.16±0.020 ^c	0.13±0.014 ^c
Jejunum	Control	0.55±0.034 ^a	0.57±0.032 ^a	0.34±0.021 ^a	0.22±0.011 ^a
	Diclazuril	0.49±0.029 ^b	0.44±0.019 ^b	0.28±0.018 ^b	0.20±0.018 ^a
	Semduramicin	0.22±0.007 ^c	0.29±0.010 ^c	0.53±0.032 ^c	0.60±0.022 ^b
	Salinomycin	0.36±0.020 ^d	0.51±0.033 ^{ab}	0.10±0.010 ^d	0.10±0.001 ^c
	Maduramycin	0.18±0.093 ^e	0.29±0.017 ^c	0.16±0.016 ^d	0.11±0.010 ^c
Ileum	Control	0.39±0.020 ^a	0.43±0.024 ^a	0.27±0.021 ^a	0.19±0.013 ^a
	Diclazuril	0.40±0.019 ^a	0.42±0.036 ^a	0.22±0.015 ^a	0.23±0.013 ^a
	Semduramicin	0.23±0.009 ^b	0.21±0.008 ^b	0.50±0.033 ^b	0.49±0.015 ^b
	Salinomycin	0.27±0.026 ^b	0.48±0.036 ^a	0.12±0.010 ^c	0.16±0.036 ^a
	Maduramycin	0.10±0.010 ^c	0.24±0.015 ^b	0.10±0.010 ^c	0.15±0.014 ^a

^{a,b,c} Means with the different indices between groups are significantly different for $p < 0.05$

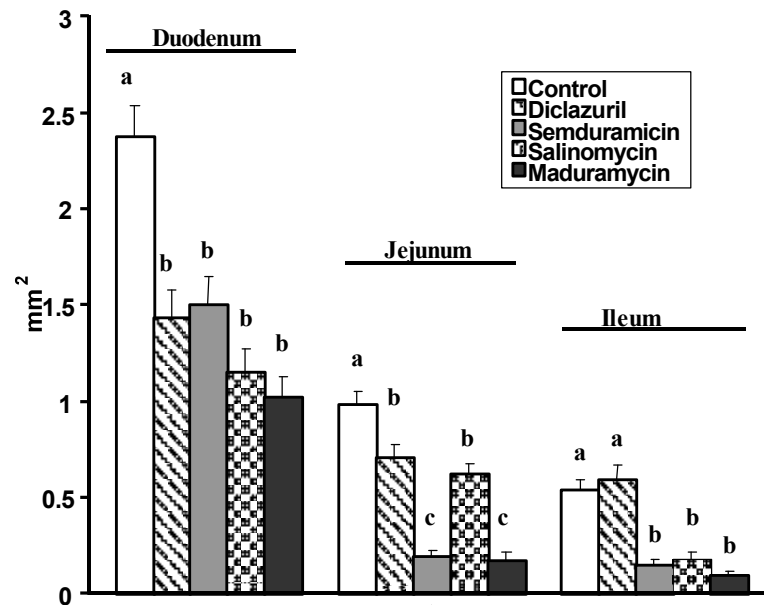


Fig. 1: Comparison of intestinal surface area in chickens treated by four anticoccidial drugs. Values are mean±SEM. Different letters show significant difference ($P < 0.05$)

The jejunum villus height, width and surface area were consistently lower for the all anticoccidial drugs-treatments, but the decreasing of width only was insignificant in salinomycin-treated group. The jejunum villus lamina propria thickness also were significantly ($P<0.05$) lower in the most treated groups while only was greater in semduramicin-treated group than control. The effect of diclazuril in the jejunum villus muscle layer was not significant compared to control, while semduramicin increased it and salinomycin or maduramycin decreased it significantly ($P<0.05$) (Table 2).

The decreasing of ileum villus height and surface area were also significant ($P<0.05$) in the most treated groups compared with the control; but there was not significant variation in diclazuril- treated group (Table 2 and Figure 1). The ileum villus width was only lower in semduramicin and maduramycin-treated groups than control. The effect of anticoccidial drugs in ileum villus lamina propria thickness and muscle layer were different; While diclazuril has no significant effect, Semduramicin significantly ($P<0.05$) increased them. On the other hand, Salinomycin and Maduramycin significantly ($P<0.05$) decreased the ileum villus lamina propria thickness wherever these two drugs did not affect in muscle layer compared to control (Table 2).

DISCUSSION

Maintaining bird health, regarding diseases or agents acting on the gastrointestinal tract, is crucial in broiler production, since this is the entry route of nutrients for bird development. The small intestine is responsible for the digestion and absorption of nutrients from food and the duodenal segment mainly for absorption [12]. Broilers exhibiting shortening of villi have impaired nutrient absorption [13]. Cell divisions in the intestine of birds, unlike mammals, are not restricted to crypts, occurring also along the villi [14]. According to Nabuurs [15], the ideal intestinal morphometry in birds are long villi and shallow crypts. That is, length of villi is related to the digestive capacity and intestinal absorptive area [14,16]. However, factors such as pathogens or drugs can cause changes in the intestinal morphology [17].

Coccidiosis is an enteritis caused by protozoan parasites, in which lesions occur due to loss of intestinal cells. Nowadays, it is common that anticoccidials are used prophylactically throughout the entire growing period in chicken to achieve total continual prevention of occurrence or suppression of coccidiosis.

In the present study, we used four anticoccidial drugs, diclazuril, semduramicin, salinomycin and maduramycin as protection in the diets of healthy chickens for four weeks and found their adverse effects on the bird performance i.e. body weight, weight gain, feed conversion rate. It has been reported that with no *Eimeria* present in the chicken, each intake of an anticoccidial drug lead to a negative effect on growth or feed conversion of a bird. Modern anticoccidial drugs tend to have a smaller margin between effective and toxic dosage [6]. In fact in most experiments a negative influence is seen. This is different for each drug and depends on the dosage administered. However, as soon as *Eimeria* infections build up in the flocks, the possible growth depressing effect of the drug will be neutralized by effective control of the infection [6]. The compensatory growth seen after withdrawal of the drug from the feed, as noticed by McDougal and McQuiston [18] could also be explained by the growth depression effect of the drug used in their study.

Brake *et al.* [19] also reported adverse effects of semduramicin, on broiler breeders. They found that semduramicin causes dose-related decrease in egg production, percentage shell, fertile hatchability and increase in early embryonic mortality.

To our knowledge, the effects of anticoccidial drugs on normal intestinal mucosa have not been studied previously in growing chicken. In this experiment, we found that these drugs decreased villous length, width and surface area, mostly in the duodenum and jejunum. However, these data are probably the evidence of impaired nutrition absorption of intestine and reduced enteric function due to anticoccidial drugs.

In this study, we also reported the reduction of lamina propria thickness in the intestine by anticoccidials except semduramicin which increases lamina propria. It appears that Lieberkühn's glands have been decreased by diclazuril, salinomycin and maduramycin and increased by semduramicin. The reason of this difference is unknown for authors. However, it is predictable that these drugs may influence intestinal secretion in chickens. Of course, it needs further studies to clarify the effect of anticoccidials on the intestinal secretions in broiler chickens.

The effect of anticoccidial drugs in the muscle layer was different. It appears that semduramicin consistently increased it in the three parts of intestine. The reason of these effects in the muscle layer by anticoccidial drugs is not clear. It is perhaps that these drugs influence on intestinal motility in addition of the effects on absorptive surface and secretions of the intestine.

It was concluded that four anticoccidial drugs, diclazuril, semduramicin, salinomycin and maduramycin have adverse effects on chicken performance and intestinal morphology, especially villus dimensions and absorptive surface. There was evidence for involvement of these drugs in the intestinal motility and secretion that need more studies to confirm.

ACKNOWLEDGMENTS

This work had been supported by the funds granted by Vice Chancellor for Research of Shahrekord University.

REFERENCES

- Conway, D.P. and M.E. McKenzie, 2007. Poultry coccidiosis: Diagnostic and testing procedures. Blackwell Pub.
- Sarkar, A.K., 2006. Pathological Study of Coccidiosis in Chick Bird. Res. J. Anim. Vet. Sci., 1: 55-56.
- Cox, F.E.G., 1998. Control of coccidiosis: lessons from other sporozoa. Inter. J. Parasitol., 28: 165-179.
- Erni'k, F. and P. Bedrni'k, 2001. Controlling Coccidiosis in Broiler Growing. Poultry Inter., 40: 36-42.
- Chapman, H.D., T.E. Cherry, H.D. Danforth, G. Richards, M.W. Shirley and R.B. Williams, 2002. Sustainable coccidiosis control in poultry production: the role of live vaccines. Inter. J. Parasit., 32: 617-629, J.E. Riviere and M.G. Papich, 2009. Veterinary pharmacology and therapeutics. Blackwell Pub.
- Braunius, W.W., 1982. Coccidiosis in Broilers: the Effective use of Anticoccidial Drugs. World Poultry Sci. J., 38: 176-185.
- Kitandu, A. and R. Juranova, 2006. Progress in Control Measures for Chicken Coccidiosis. Acta Vet. Brno, 75: 265-276.
- NRC, 1994. Nutrient Requirements of Poultry. National Academy of Science Press, Washington D.C.
- Teshfam, M., H. Nodeh and M. Hassanzadeh, 2005. Alterations in the intestinal mucosal structure following oral administration of triiodothyronine (T3) in broiler chickens. J. Appl. Anim. Res., 27: 105-108, A.K. Zamani Moghaddam, H. Hassanpour and A. Mokhtari, 2009. Oral supplementation with vitamin C improves intestinal mucosa morphology in the pulmonary hypertensive broiler chicken. Brit. Poultry Sci., 50: 175-180.
- Sakamoto, K., H. Hirose, A. Onizuka, M. Hayashi, N. Futamura, Y. Kawamura and T. Ezaki, 2000. Quantitative study of changes in intestinal morphology and mucus gel on total parenteral nutrition in rats. J. Surg. Res., 94: 99-106.
- Aptekmann, K.P., S.M. Artoni, M.A. Stefanini and M.A. Orsi, 2001. Morphometric analysis of the intestine of domestic quails (*Coturnix coturnix japonica*) treated with different levels of dietary calcium. Anat. Histol. Embryol., 30: 277-280.
- Assis, R.C.L., F.D. Luns, M.E. Beletti, R.L. Assis, N.M. Nasser, E.S.M. Faria and M.C. Cury, 2010. Histomorphometry and macroscopic intestinal lesions in broilers infected with *Eimeria acervulina*. Vet. Parasitol., doi:10.1016/j.vetpar.2009.1011.1017.
- Boleli, I.C., A. Maiorka, M. Macari, R.L. Furlan and E. Gonzales, 2002. Estrutura funcional do trato digestório. Fisiologia aviária aplicada a frangos de corte. Jaboticabal: FUNEP-UNESP, pp: 75-95, J.G. Cunningham and B.G. Klein, 2004. Textbook of Veterinary Physiology.
- Uni, Z., S. Ganot and D. Sklan, 1998. Posthatch development of mucosal function in the broiler small intestine. Poultry Sci., 77: 75-82.
- Nabuurs, M.J.A., 1995. Microbiological, structural and functional changes of the small intestine of pigs at weaning. Pig News Info., 16: 93N-97N.
- Uni, Z., G. Zaiger, O. Gal-Garber, M. Pines, I. Rozenboim and R. Reifen, 2000. Vitamin A deficiency interferes with proliferation and maturation of cells in the chicken small intestine. Brit. Poultry Sci., 41: 410-415.
- Pluske, J.R., D.J. Hampson and I.H. Williams, 1997. Factors influencing the structure and function of the small intestine in the weaned pig: a review. Livest. Prod. Sci., 51: 215-236.
- McDougald, L.R. and T.E. McQuiston, 1980. Compensatory growth in broilers after withdrawal of ionophorous anticoccidial drugs. Poultry Sci., 59: 1001-1005.
- Brake, J., T.S. Cummings, C.R. Pinedo and K.W. Bafundo, 2001. Effects of the ionophore anticoccidial semduramicin on broiler breeders. Poultry Sci., 80: 260-265.