

Schistosomus Reflexus Fetus in A Cross-Breed Egyptian Cow: A Case Report

N. Mansour, E. Almadaly, A. Karen and A. Ramoun

Department of Theriogenology, Faculty of Veterinary Medicine,
Kafrelsheikh University, Kafrelsheikh, Egypt

Abstract: The present case study describes an unusual schistosomus reflexus fetus in a cross-breed Egyptian cow. The consistent and variable defects and handling of the congenital anomalous fetus are discussed.

Key words: Schistosomus Reflexus • Fetus • Cow • Egypt

INTRODUCTION

Schistosomus reflexus (SR) is a rare and fatal congenital anomaly with many consistent and variable defects, mainly observed in ruminants and causes dystocia [1, 2]. Its consistent defects include spinal inversion, exposure of abdominal viscera due to presence of a fissure in the ventral abdominal wall, limb ankylosis, positioning of limbs adjacent to the skull, as well as lung and diaphragm hypoplasia [1-3]. Variable defects of SR include scoliosis, cleft sternum, exposure of thoracic viscera and abnormalities of the digestive and urogenital systems [3]. The prevalence of SR is in the range of 0.01% [4] to 1.3% [5] of bovine dystocias. The schistosomus reflexus foeti had been reported to be born as a co-twin with a normal [5], or a freemartin calf [6], or as conjoined twins [7]. This case report describes for the first time some defects as an unusual SR fetus in a crossbred Egyptian cow.

Case History: A 7-year old, cross-bred cow (Egyptian native x Holstein) was admitted to the Veterinary Teaching Hospital of Faculty of Veterinary Medicine, Kafrelsheikh University, Egypt, with a history of dystocia 6 hours after the rupture of fetal sacs. The cow had been naturally bred and neither suffered from any illness nor received any medications during her gestation period. The cow had been examined by a private veterinarian who found the fetal viscera inside the vagina. He had removed these viscera and failed to remove the fetus by manual traction.

Handling of the Case: At the Veterinary Teaching Hospital, outer examination revealed the presence of signs of parturition such as relaxation of sacro-sciatic ligaments, enlarged udder and presence of colostrum in the teats. Vaginal examination revealed an intact soft birth canal and a fully-dilated cervix. In addition, a relatively small-sized fetus was detected in ventral transverse presentation in front of the pelvic brim. With the exception of the abdomen and the thorax, fetal parts were covered with a thick membrane. Epidural analgesia was induced by administration of 7 ml of Debocain® in sacro-coccygeal space. A per-cutaneous longitudinal fetotomy cut was applied on the fetus behind the thorax dividing the fetus into two parts. Each part was removed by traction using a Krey schöttler double-hook and the prominent bony parts were guarded with the hand of obstetrician to avoid the injury of the birth canal. After extraction of the fetus, 4 gm of oxytetracyclin tablets were inserted intra-uterine and ergometerine maleate was administered intramuscularly (i.m.). A combination of penicillin and streptomycin and flunixin meglumine was systemically administered for the next 3 days.

RESULTS AND DISCUSSION

The two halves of fetus were replaced at the site of cut to regain the original pre-partum body conformation. The eviscerated fetus weighed 14.7 Kg. Inspection of the removed fetus revealed that the head, neck and fore limbs were completely enclosed within a thick-membrane glistening sac. Also, the fetal hind limbs and pelvis were

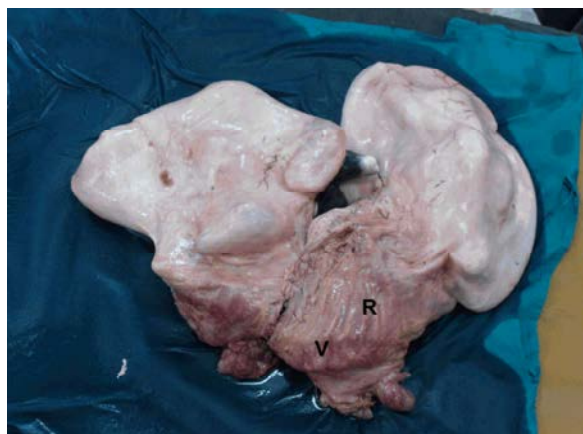

Fig. 1: Schistosomus reflexus fetus was delivered by fetotomy. With the exception of the chest and abdomen, the fetal parts are completely covered by 2 separate thick membranous sacs. Note the dorsally reflected chest ribs (R) and ventral curvature of the vertebral column (V)

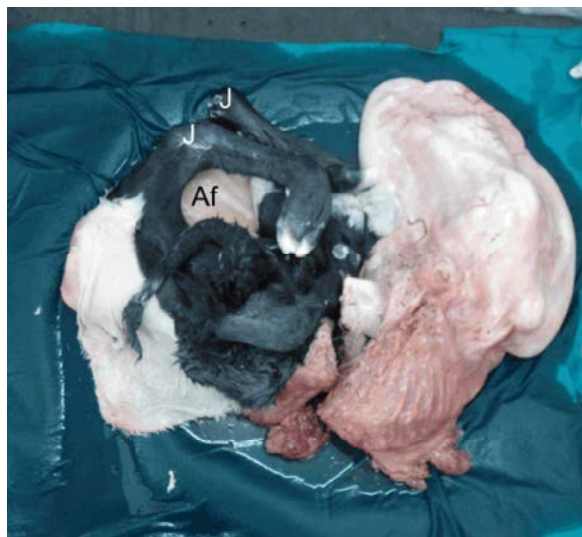


Fig. 2: Schistosomus reflexus fetus after incision of the skin covering the pelvis and hind limbs. Notice the ankylosed joints of hind limbs (J) and accumulation of amniotic fluid (Af)

enclosed within another membranous sac (Fig. 1). Each sac was incised; the inner surface of these membranous sacs was completely covered with hairs confirming that these sacs are the reflected skin. Previously, head and limbs of SR foetai were encapsulated within the reflected skin [8, 9]. Each side of reflected chest and abdominal skin might have fused with its other side forming two separate sacs, one enclosed the head and the fore limbs and the

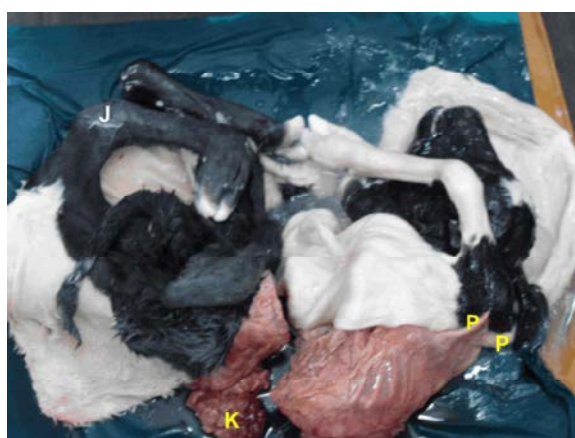

Fig. 3: Schistosomus reflexus fetus after incision of the skin covering the hind limbs and the pelvis and that covering the head, neck and forelimbs. Notice the ankylosed joints of fore limbs (J), two prominent processes (P) and the kidney (K)

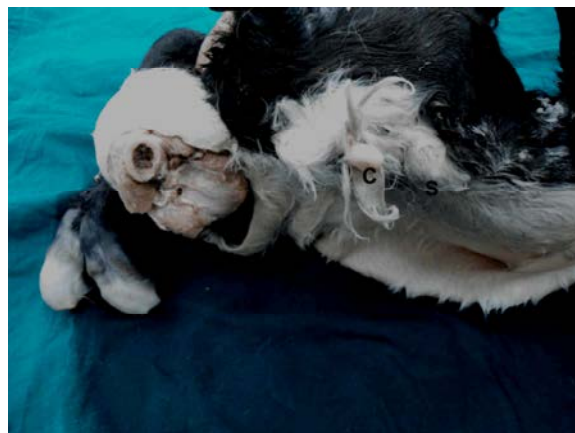


Fig. 4: Inguinal region of the schistosomus reflexus fetus. Notice the enlarged clitoris-like structure protruding from small opening in the inguinal region surrounded by long and heavy hair (C) and an empty scrotum (S)

other enclosed the hind limbs and the pelvis. A tenacious amniotic-like fluid was found accumulated in each sac (Fig.2). Multiple congenital anomalies were observed in the fetus including ankylosis of the joints of fore and hind limbs (Fig. 2 and 3), ventral curvature of the vertebral column and the four limbs were close to the head due to their dorsal inversion. These anomalies were the defining features of SR fetus as previously described [3]. Other anomalies were observed such as dorsally reflected ribs which fused at sternum, atresia ani and an empty scrotum. Similar findings were reported by Cavalieri and Farin [6].

In addition, two bony processes were projected from the thorax (Fig.3) and there was a large clitoris-like structure protruding from a small orifice surrounded by heavy and long hair cranial to the scrotum (Fig. 4). These last two anomalies were not reported in the previous studies.

Conflict of Interest: The authors declare that they have no conflict of interest

REFERENCES

1. Din Dar M.U., F. Ahmad, K.H. Dar and H. Athar, 2015. A Typical Case of True Schistosomus Reflexus (SR) in a Local Ewe of Kashmir. *J. Veterinar Sci. Technol.*, 6: 4. <http://dx.doi.org/10.4172/2157-7579.1000241>.
2. Suthar, D.N., V.K. Sharma, V.S. Dabas and D.B. Bhoi, 2011. Per-vaginal handling of Schistosomus reflexus as a cause of dystocia in a Goat. *Veterinary World* 4(7): 330-331, DOI:10.5455/vetworld.4.3303
3. Laughton, K.W., R.S. Fischer, W.G. Halina and G.D. Partlow, 2005. Schistosomus reflexus syndrome: A heritable defect in ruminants. *Anat., Histol. Embryol.*, 34: 312-318.
4. Sloss, V.E. and D.E. Johnston, 1967. The cause and treatment of dystocia in beef cattle in western Victoria. *Australian Veterinary Journal*, 43: 13-21.
5. Knight, R.P., 1996. The occurrence of schistosomus reflexus in bovine dystocia. *Australian Veterinary Journal*, 73: 105-107.
6. Cavalieri, J. and P.W. Farin, 1999. Birth of a Holstein freemartin calf co-twinning to a schistosomus reflexus fetus. *Theriogenology*, 52: 815-826.
7. Rajani, C.V. and K.S. Raghavan, 2010. Dystocia due to conjoined twins with schistosomus reflexus in cattle. *Tamilnadu Journal of Veterinary and Animal Sciences*, 6: 52-53.
8. Rai M.T., V.K. Sundaravadanan and K.N.V. Sastry, 1975. A case of bovine schistosomus reflexus. *Indian Veterinary Journal*, 52: 504.
9. Roberts, S.J., 1986. *Veterinary Obstetrics and Genital diseases*. Woodstock, VT: Published by the Author, 78: 336.