

Applied Anatomy of the Rabbit's Skull and its Clinical Application During Regional Anesthesia

Ali Louei Monfared

Department of Anatomy,
Faculty of Para-Veterinary Medicine, University of Ilam, Ilam, Iran

Abstract: Rabbit is used for many purposes including as an animal model in a variety of biomedical research fields and also for meat and fur production. On the other hand, there has recently been a marked increase in its popularity as a companion animal and it has become the third most popular mammalian pet in the United Kingdom after the dog and cat. Since, there is a lack of information on anatomical measurements of the skulls of rabbits and its clinical value during regional anesthesia; the present work was taken. The investigation was carried out on the eleven adult New Zealand white rabbits older than two year without any apparent skeletal disorders. Then, a total of seventeen skull measurements and indices were recorded. In the present study, the skull length, cranial length, nasal length and cranial width of the adult rabbits were 9.41 cm, 6.11 cm, 3.29 cm and 3.12 cm respectively. Also, the cranial index was 50.81. In addition, the distances from the root of premolar tooth to infra-orbital canal and from the latter to the root of the incisors teeth were 0.57 cm and 3.37 cm, respectively. The length and height of the mandibles of the adult rabbits were 7.5 cm and 2.93 cm, respectively. Furthermore, the distances from the lateral alveolar root to mental foramen and from the mental foramen to caudal mandibular border were 1.89 cm and 5.3 cm, respectively. In the current work, the distances from mandibular foramen to the base of mandible as well as from caudal border of mandible to below of the mandibular foramen were 0.87 cm and 1.78 cm, respectively. Also, the distances from the base of mandible to condyloid process and from the latter to the maximum height of mandible were 2.58 cm and 0.33 cm, respectively. Finally, the distance from caudal border of mandible to mandibular foramen and from the latter to mandibular angle were 1.51 cm and 0.67 cm, respectively. These data as important landmarks are discussed with regard to their application to clinical maneuvers around the head of the rabbits such as regional anesthesia during treating head injury and dental extraction.

Key words: Applied Anatomy • Rabbit • Skull • Regional Anesthesia

INTRODUCTION

Rabbit is used for many purposes including as an animal model in a variety of biomedical research fields and also for meat and fur production [1]. On the other hand, there has recently been a marked increase in its popularity as a companion animal and it has become the third most popular mammalian pet in the United Kingdom after the dog and cat [2, 3]. Consequently there has been an increasing interest and necessity in the level of the veterinary care demanded by owners for this species [3].

Previous investigators reported that rodent models are extremely useful for conducting basic research involving the skeleton and represent reliable and affordable alternatives to nonhuman primates [4].

It had been demonstrated that the morphologic and morphometric investigations on the skull are not only reflect contributions of genetic and environmental components to individual development, but also are foundations of the clinical and surgical practices [5, 6]. In addition, applied anatomy is one of the principles of the clinical and surgical practice; because it enables the clinician to visualize details of structures relevant to

Corresponding Author: Ali Louei Monfared, Department of Basic Sciences, division of anatomy and histology, Faculty of Para-Veterinary Medicine, University of Ilam, Ilam, Iran, Pajoohesh Street, Bangonjab, University of Ilam, Ilam, Iran. Tel: +98-8412222015+989183419098.

the case at hand [7, 8]. Similarly, the directions of the cranial nerves and their passages from different foramina in the skull are of clinical importance in regional anesthesia around the head for surgical purposes [8, 9].

Since, there is very little information on the applied anatomy of the skull of the New Zealand white rabbit and its clinical value during regional anesthesia; therefore, the aim of this study was to evaluate some craniometrical parameters of the head region and its application for regional anesthesia.

MATERIALS AND METHODS

To do the experiment, eleven adult New Zealand white rabbits older than two year without any apparent skeletal disorders were purchased from Razi Institute (Karaj, Iran). The animals were anaesthetized and their heads were severed at the occipito-atlantal joint and processed in the veterinary anatomy laboratory using the boiling maceration techniques for skeleton preparation that have been reported by Simoens *et al.* [10]. The main steps in skull skeleton preparing briefly are following:

- Skin and most of the muscles were separated and eyes were enucleated.
- Heads were heated to over 80°C for at least 1 hour in solution of surfactant (detergent) and soap chips.
- Muscles of boiled heads were separated with the aid of forceps and scalpel in running water.
- Further separation of muscles and ligaments from the skulls was done after left in detergent water at least 20-30 minutes.
- Separation of remaining muscles and ligaments from the skull was done after left in 1% sodium hypochlorite solution for at least 24 hours.
- After that, the skulls were left in the above solution, for 48-72 hours with solution, being changed at least twice and clean in running tap water.
- The skulls were then left to dry.

A total of 17 gross anatomical measurements were done in the upper jaw and mandibles using scale, thread and digital calipers and the results were presented as means±SD in Table 1. These anatomical parameters of the upper and lower jawbones of the adult rabbit's skulls are defined below and shown in Figs. 1-5.

Skull Length: From the dorsal lateral nasal cartilages to the external occipital protuberance; sub-divided into cranial length and nasal length.




Fig. 1: Skull of the rabbit; dorsal view. A: Skull length, B: Cranial length, C: Nasal length, D: Cranial width.

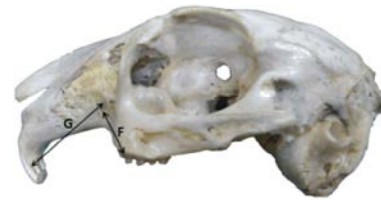

Fig. 2: Skull of the rabbit; lateral view. F: The root of premolar tooth to infra-orbital canal, G: Infra-orbital canal to root of incisors teeth.

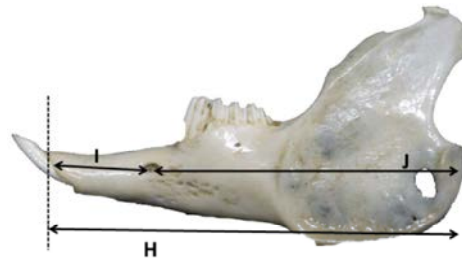


Fig. 3: Mandible of the rabbit; lateral view. H: Mandibular length, I: Lateral alveolar root to mental foramen, J: Mental foramen to caudal mandibular border.

Cranial Length

Nasal Length

Cranial Width

Cranial Index: $\text{Cranial width} \times 100 / \text{cranial length}$.

The Root of Premolar Tooth to Infra-Orbital Canal:

From the root of the first premolar tooth to the mid level of the infra-orbital canal.

Infra-Orbital Canal to Root of Incisors Teeth:

Measurement is taken vertically from the mid-level of the in infra-orbital canal to the root of the incisors teeth.

Mandibular Length: From the level of the cranial extremity of the alveolar root of the incisor to the level of the caudal border of the mandible.

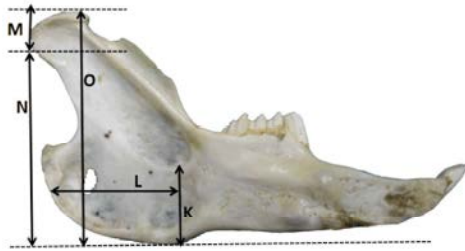


Fig. 4: Mandible of the rabbit; medial view. K: Mandibular foramen to base of mandible, L: Caudal border of mandible to below of the mandibular foramen, M: Condyloid process to height of mandible, N: Condyloid process to the base of the mandible, O: Maximum mandibular height.

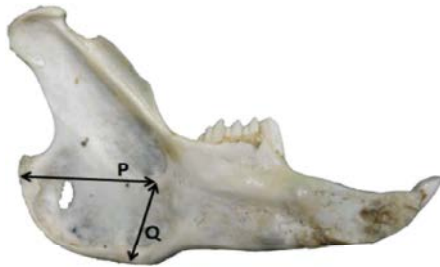


Fig. 5: Mandible of the rabbit; medial view. P: Caudal border of mandible to the level of mandibular foramen, Q: Mandibular foramen to mandibular angle.

Lateral Alveolar Root to Mental Foramen: Shortest distance from the mental foramen to the lateral extent of the alveolar root of lower incisor.

Mental Foramen to Caudal Mandibular Border: From the level of the mental foramen to the extreme caudal border of the mandible.

Mandibular Foramen to Base of Mandible: Vertical line from the ventral limit of the mandibular foramen to the base of the mandible.

Caudal Border of Mandible to below of the Mandibular Foramen: Length from the caudal most border of the mandible to the vertical line produced by description of measurement of mandibular foramen to base of the mandible.

Condyloid Process to Height of Mandible: From the maximum height of mandible to the condyloid process.

Table 1: Mean±SD of the anatomical measurements of the mandibles and upper jaws of rabbit (cm)

Morphometric parameter	Mean±SD
A	9.41±2.17
B	6.11±0.34
C	3.29±0.01
D	3.12±0.11
E	50.81±8.04
F	0.57±0.01
G	3.37±0.42
H	7.5±0.55
I	1.89±0.04
J	5.3±0.43
K	0.87±0.09
L	1.78± 0.22
M	0.33±0.26
N	2.58±0.22
O	2.93±0.17
P	1.51±0.23
Q	0.67±0.04

Condyloid Process to the Base of the Mandible

Maximum Mandibular Height: From the basal level of the mandible to the highest level of the coronoid process.

Caudal Border of Mandible to the Level of Mandibular Foramen

Mandibular Foramen to Mandibular Angle: Shortest distance from the mandibular foramen to the extreme caudal border of the angle of the mandible.

RESULTS

In the present study, the skull length, cranial length, nasal length and cranial width of the adult rabbits were 9.41 cm, 6.11 cm, 3.29 cm and 3.12 cm respectively. Also, the cranial index was 50.81 (Figure 1, Table 1). In addition, the distances from the root of premolar tooth to infra-orbital canal and from the latter to the root of the incisors teeth were 0.57 cm and 3.37 cm, respectively (Figure 2, Table 1).

The length and height of the mandibles of the adult rabbits were 7.5 cm and 2.93 cm, respectively. Furthermore, the distances from the lateral alveolar root to mental foramen and from the mental foramen to caudal mandibular border were 1.89 cm and 5.3 cm, respectively (Figure 3, Table 1). In the current work, the distances from mandibular foramen to the base of mandible as well as from caudal border of mandible to below of the mandibular foramen were 0.87 cm and 1.78 cm, respectively. Also, the distances from the base of mandible to condyloid process and from the latter to the maximum height of mandible were 2.58 cm and 0.33 cm, respectively (Figure 4, Table 1).

Finally, the distance from caudal border of mandible to mandibular foramen and from the latter to mandibular angle were 1.51 cm and 0.67 cm, respectively (Figure 5, Table 1).

DISCUSSION

In this study, the values of skull length, cranial length, nasal length and cranial width of the New Zealand white rabbits were similar to the results from previous investigation on the domestic rabbits (*Oryctolagus cuniculus*) [11].

On the basis of results from the current study, in the New Zealand white rabbits the distances from the root of premolar tooth to infra-orbital canal and from the latter to the root of the incisors teeth were 0.57 cm and 3.37 cm, respectively. It had been demonstrated that the infra-orbital foramen in the skull of rabbit is over the alveolus for the first premolar tooth and infra-orbital nerve emerges through this foramen [12-15]. Therefore, these data can be useful for tracking the infra-orbital nerve and necessary for the desensitization of the skin of the upper lip, lower eyelid, nostril and face on that side of the level of the foramen [16,17]. The injection of local anesthetic agents within the canal via the infra-orbital foramen will also lead to analgesia of the incisor and first premolar teeth.

In the present study, the distance from the lateral alveolar root to mental foramen was 1.89 cm. This parameter is a vital guide that will detect the location of the mental nerve for this regional nerve block in the rabbits; especially for lower lip anesthesia. The injection of the local anesthetic agents can be made in the rostral aspect of the mandibular canal through the mental foramen to mandibular nerve block in the mental zone. This will ensure the loss of sensation of the lower incisors, premolar and lower lip on the same side [16-18] during lower lip trauma, dental extraction and treatment of the tooth injuries.

Upon to the results from the current study, the mandibular length and height in the New Zealand white rabbits were similar to the data obtained for the domestic rabbits (*Oryctolagus cuniculus*) [11]. Similar results had been reported in the values of the distances between the mandibular foramen to base of mandible and condyloid process to the base of the mandible [4, 11].

The caudal border of the mandible to bellow of the mandibular foramen was 1.78 cm in the New Zealand white rabbits. In addition, the distance from the caudal border of mandible to the level of mandibular foramen and from the

latter to the border of mandibular angle was 1.51 cm and 0.67 cm, respectively. The anesthetic agents must to be injecting on the medial side of the mandible, thereby; a successful nerve block produces anesthesia of the lower jaw with its teeth and the lower lip. These data are necessary for achieving the regional anesthesia of the mandibular nerve and also have clinical importance for desensitization of all the teeth in lower jaw [18].

In conclusion, the morphometric information of the skull and applied anatomy of the head region of the rabbits provide an important baseline for further research in this field. Furthermore, these results can also be useful tool that will aid the regional anesthesia of the cranial nerves around the head especially during treating head injury and dental extraction of the New Zealand white rabbit.

ACKNOWLEDGEMENTS

The author wish to acknowledge Mr. Kazem Chawooshi, Mr. Ali Akbar Hosseinzadeh, Ms. Hajar Azizian and Ms. Dr. Rohollah Fatahi for their assistance with preparing the skulls.

REFERENCES

1. Shively, M.J., 1979. Xeroradio-graphic anatomy of the domesticated rabbit (*Oryctolagus scuniculus*) Part I: head, thorax and thoracic limb. The Southwestern Veterinarian, 32: 219-233.
2. Nicholson, M., 2001. British Rabbit Concil. <http://www.thebrc.org/>.
3. Meredith, A., 2009. Rabbits, Royal (Dick) School of Veterinary Studies, University of Edinburgh. <http://www.aquavet.i12.com/>.
4. Bagi, C.M., E. Berryman and M.R. Moalli, 2011. Comparative Bone Anatomy of Commonly Used Laboratory Animals: Implications for Drug Discovery. Comparative Medicine, 61(1): 76-85.
5. Karimi, I., V. Onar, G. Pazvant, M. Hadipour and Y. Mazaheri, 2011. The cranialmorphometric and morphologic characteristics of Mehraban sheep in western Iran. Global Veterinaria, 6(2): 111-117.
6. Wehausen, J.D. and R.R. Ramey, 2000. Cranial morphometric and evolutionary relationships in the northern range of *Ovis Canadensis*. Journal of Mammalogy, 81: 145-161.
7. Ommer, P.A. and K.R. Harshan, 1995. Applied anatomy of domestic' animals, 1st Edition. Jaypee brother's medical publisher, India.

8. Dyce, K.M., W.O. Sack and C.J.G. Wensing, 2002. Textbook of Veterinary Anatomy, ed 3. Philadelphia, W.B. Saunders.
9. Hall, L.W., K.W. Clarke and C.M. Trim, 2000. Wright's Veterinary Anesthesia and Analgesia. 10. ed. London, ELBS and Bailliere Tindall.
10. Simoens, R., P.R. Oles and H. Lauwers, 1994. Morphometric analysis of foramen magnum in Pekingese dogs. American Journal of Veterinary Research, 55: 33-39.
11. Farag, F.M., S.M. Daghash, E.F. Mohamed, M.M. Hussein and S.M. Hagrass, 2012. Anatomical Studies on the Skull of the Domestic Rabbit (*Oryctolagus cuniculus*) With Special Reference to the Hyoid Apparatus. Journal of Veterinary Anatomy, 5(2): 49-70.
12. McLaughlin, C.A. and R.B. Chiasson, 1990. Laboratory anatomy of the rabbit. Briston. Mc Graw Hill.
13. Craigie, E.H., 1969. Bensley's practical anatomy of the rabbit (8th edn). Toronto Press, Canada.
14. Barone, R., C. Pavau and P.C. Blin, 1973. Atlas D, Anatomie Du lapin Atlas of rabbit Anatomy. Boulevard Saint Germain, Paris.
15. Popesko, P., V. Rajtova and J. Horak, 1992. A colour atlas of the anatomy of small laboratory animals, Vol.1, Rabbit and guinea pig. Wolfe Publishing, Bratislava.
16. Crabb, E.D., 1931. Principles of functional anatomy of the rabbit. Philadelphia, P. Blakiston's son and co., inc
17. Bensley, B.A., 1910. Practical anatomy of the rabbit; an elementary laboratory textbook in mammalian anatomy. Toronto, The University Press; Philadelphia, P. Blakiston's Son and Co.
18. Flecknell, P.A., 1980. Laboratory animal anesthesia. Academic press limited. London, pp: 137.