

## Gross Anatomy of the Head Region of the Iranian Native Horse and its Clinical Value During Regional Anesthesia

*Ali Louei Monfared*

Department of Anatomy, Faculty of Para-Veterinary Medicine, University of Ilam, Ilam, Iran

**Abstract:** The horse's skull has the form of a long, four-sided pyramid, the base of which is caudal. Since there is a lack of comprehensive data on the gross anatomy of the head region of the Iranian native horse and its clinical value during regional anesthesia; therefore, the present work was carried out. This study involved some morphometric parameters of the mandibles and upper jaws of eighteen Iranian native horses aged between 5-8-year-old. Then, a total of 17 head measurements and indices were recorded. The supraorbital foramina distance, infraorbital foramina distance, skull length, cranial length and nasal length were 21.4 cm, 12.7 cm, 50.7 cm, 29.9 cm and 20.8 cm, respectively. Also, the distances from facial crest to the infra-orbital canal and from the latter to the root of the alveolar tooth were 4.9 cm and 7.53 cm, respectively. The length and height of the mandibles were 28.5 cm and 17.1 cm, respectively. Furthermore, the distances from the lateral alveolar root to mental foramen and from the mental foramen to caudal mandible border were 7.4 cm and 21.1 cm, respectively. The distances from mandibular foramen to the base of mandible as well as from caudal border of mandible to below of the mandibular foramen were 6.3 cm and 5.85 cm. Finally, the distance from caudal border of mandible to mandibular foramen and from the latter to mandibular angle were 4.8 cm and 6.4 cm, respectively. These data as important topographic landmarks are discussed with regard to their application to clinical maneuvers around the head of the Iranian native horses such as regional anesthesia during treating head injury and dental extraction.

**Key words:** Gross Anatomy • Head • Horse • Regional Anesthesia

### INTRODUCTION

The horse's skull has the form of a long, four-sided pyramid, the base of which is caudal. It is convenient; however, to exclude the mandible from present consideration [1]. It has been demonstrated that the morphologic and morphometric studies of the head region are not only reflect contributions of genetic and environmental components to individual development and describe genetic and ecophenotypic variation, but also are foundations of the clinical and surgical practices [2, 3]. On the other hand, clinical anatomy is one of the principles of the clinical and surgical practice; because it enables the clinician to visualize details of structures relevant to the case at hand [4, 5]. Furthermore, the

directions of the cranial nerves and their passages from different foramina in the skull are of clinical importance in regional anesthesia around the head [5, 6].

As a whole, there are a few studies on the gross anatomy of the skull and its clinical value for regional anesthesia in the domestic animals. For instance, Louei Monfared *et al.* [7] determined the applied landmarks on the head region of the Iranian native goats and their application to clinical maneuvers around the head. In addition, Radinsky [8] studied the ontogeny and phylogeny in horse's skull evolution and demonstrated that when comparing skull length, it is necessary to consider the skull as being composed of two major components; the neuro-cranium and the splanchnocranium. Also, Evans and McGreevy [9] considered the

**Corresponding Author:** Ali Louei Monfared, Department of Basic Sciences, Division of Anatomy and Histology, Faculty of Para-veterinary Medicine, University of Ilam, Ilam, Iran, Pajoohesh Street, Bangonjab, University of Ilam, Ilam, Iran.  
Tel: +98-8412222015 & +989183419098, Fax: +98-8412222015.

conformation of the equine skull and reported that there are significant differences in the morphometric indices of craniums between thoroughbreds, standardbreds and Arabians breeds. Furthermore, Perez and Martin [10] determined the cause of a groove frequently found on the dorsal border and medial side of the nasal process of the Equine incisive bone. They concluded that the sulcus seems to be caused by the combined action of the lateralis nasi muscle and the medial accessory cartilage of the nose.

Since there is a lack of comprehensive data on the gross anatomy of the head region of the Iranian native horse and its clinical value during regional anesthesia; therefore, the present work was carried out.

## MATERIALS AND METHODS

This study involved some morphometric parameters of the mandibles and upper jaws of eighteen Iranian native horses aged between 5-8-year-old without any apparent skeletal disorders. The specimens were brought for dissection purposes in the anatomy laboratories, University of Tehran (Tehran, Iran) and also University of Ilam (Ilam, Iran). The heads were severed at the occipito-atlantal joint and processed in the veterinary anatomy laboratory using the boiling maceration techniques for skeleton preparation that have been reported by Simoens *et al.* [11]. The main steps in skull skeleton preparing briefly are following:

- On the working day, frozen horse head were allowed to thaw.
- Skin and most of the muscles were separated and eyes were enucleated.
- Heads were heated to over 80°C for at least 1 hour in solution of anionic surfactant (detergent) and soap chips.
- Muscles of boiled heads were separated with the aid of forceps and scalpel in running water.
- Further separation of muscles and ligaments from the skulls was done after left in detergent water at least 20-30 minutes.
- Separation of remaining muscles and ligaments from the skull was done after left in 1% sodium hypochlorite solution for at least 24 hours.
- After that, the skulls were left in the above solution, for 48-72 hours with solution, being changed at least twice and clean in running tap water.
- The skulls were then left to dry.

Table 1: Mean  $\pm$  SD of the morphometric measurements of the mandibles and upper jaws of the Iranian native horse (cm)

Morphometric parameter	Mean $\pm$ SD
A	21.4 $\pm$ 4.59
B	12.7 $\pm$ 6.16
C	50.7 $\pm$ 8.73
D	29.9 $\pm$ 5.29
E	20.8 $\pm$ 6.39
F	4.9 $\pm$ 0.82
G	7.53 $\pm$ 0.69
H	28.5 $\pm$ 7.18
I	7.4 $\pm$ 0.33
J	21.1 $\pm$ 9.28
K	6.3 $\pm$ 1.84
L	5.85 $\pm$ 0.62
M	3.7 $\pm$ 0.88
N	13.4 $\pm$ 0.58
O	17.1 $\pm$ 2.94
P	4.8 $\pm$ 0.62
Q	6.4 $\pm$ 0.75

A total of 17 morphometric measurements were done in the upper jaw and mandibles using scale, thread and digital calipers and the results were presented as means  $\pm$  SD in Table 1. These morphometric parameters of the upper and lower jawbones of the Iranian native horse's skulls are defined below and shown in Figs. 1-5.

**Supraorbital Foramina Distance:** Greatest width between the supraorbital foramina.

**Infraorbital Foramina Distance:** Facial width between the supraorbital foramina.

**Skull Length:** From the dorsal lateral nasal cartilages to the external occipital protuberance; sub-divided into cranial length and nasal length.

**Cranial Length:**

**Nasal Length:**

**Facial Crest to Infra-Orbital Canal:** From the level of the most lateral bulging of the facial crest to the mid level of the infra-orbital canal.

**Infra-Orbital Canal to Root of Alveolar Tooth:** Measurement is taken vertically from the mid-level of the in infra-orbital canal to the root of the alveolar tooth.

**Mandibular Length:** From the level of the cranial extremity of the alveolar root of the incisor to the level of the caudal border of the mandible.

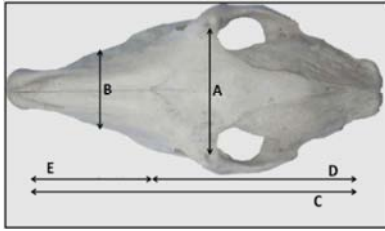


Fig. 1: Skull of the Iranian native horse; dorsal view. A: Supraorbital foramina distance, B: Infraorbital foramina distance, C: Skull length, D: Cranial length, E: Nasal length



Fig. 2: Skull of the Iranian native horse; lateral view. F: Facial crest to infra-orbital canal, G: Infra-orbital canal to root of alveolar tooth

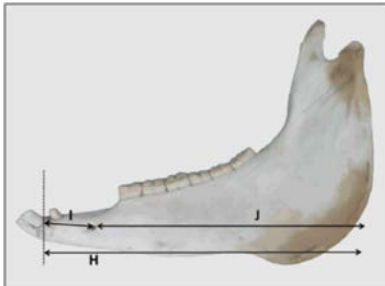


Fig. 3: Mandible of the Iranian native horse; lateral view. H: Mandibular length, I: Lateral alveolar root to mental foramen, J: Mental foramen to caudal mandibular border

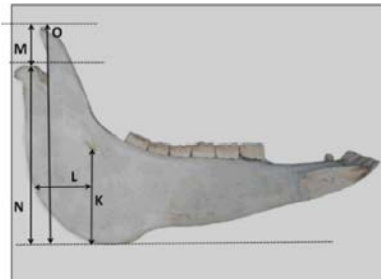


Fig. 4: Mandible of the Iranian native horse; medial view. K: Mandibular foramen to base of mandible, L: Caudal border of mandible to below of the mandibular foramen, M: Condyloid fossa to height of mandible, N: Condyloid fossa to the base of the mandible, O: Maximum mandibular height




Fig. 5: Mandible of the Iranian native horse; medial view. P: Caudal border of mandible to the level of mandibular foramen, Q: Mandibular foramen to mandibular angle

**Lateral Alveolar Root to Mental Foramen:** Shortest distance from the mental foramen to the lateral extent of the alveolar root of lower incisor.

**Mental Foramen to Caudal Mandibular Border:** From the level of the mental foramen to the extreme caudal border of the mandible.

**Mandibular Foramen to Base of Mandible:** Vertical line from the ventral limit of the mandibular foramen to the base of the mandible.

**Caudal Border of Mandible to below of the Mandibular Foramen:** Length from the caudal most border of the mandible to the vertical line produced by description of measurement of mandibular foramen to base of the mandible.

**Condyloid Fossa to Height of Mandible:** From the maximum height of mandible to the condyloid fossa.

**Condyloid Fossa to the Base of the Mandible:**

**Maximum Mandibular Height:** From the basal level of the mandible to the highest level of the coronoid process.

**Caudal Border of Mandible to the Level of Mandibular Foramen:**

**Mandibular Foramen to Mandibular Angle:** Shortest distance from the mandibular foramen to the extreme caudal border of the angle of the mandible.

## RESULTS

The supraorbital foramina distance, infraorbital foramina distance, skull length, cranial length and nasal length of the Iranian native horse were 21.4 cm, 12.7 cm,

50.7 cm, 29.9 cm and 20.8 cm, respectively (Figure 1, Table 1). In addition, the distances from facial crest to the infra-orbital canal and from the latter to the root of the alveolar tooth were 4.9 cm and 7.53 cm, respectively. (Figure 2, Table 1).

The length and height of the mandibles of the Iranian native horses were 28.5 cm and 17.1 cm, respectively. Furthermore, the distances from the lateral alveolar root to mental foramen and from the mental foramen to caudal mandibular border were 7.4 cm and 21.1 cm, respectively (Figure 3, Table 1). In the present study, the distances from mandibular foramen to the base of mandible as well as from caudal border of mandible to below of the mandibular foramen were 6.3 cm and 5.85 cm, respectively. Also, the distances from the base of mandible to condyloid fossa and from the latter to the maximum height of mandible were 3.7 cm and 13.4 cm, respectively (Figure 4, Table 1). Finally, the distance from caudal border of mandible to mandibular foramen and from the latter to mandibular angle were 4.8 cm and 6.4 cm, respectively (Figure 5, Table 1).

## DISCUSSION

The values of supraorbital foramina distance, skull length, cranial length and nasal length of the Iranian native horse were relatively different from the results on the thoroughbreds, standardbreds and Arabians breeds. It may be due to the existence of significant differences in the skull's morphometric indices between various horses breeds [9].

In the Iranian native horse; the distances from facial crest to the infra-orbital canal and from the latter to the root of the alveolar tooth were 4.9 cm and 7.53 cm, respectively. Since the facial crest is very prominent as a guide for tracking the infra-orbital nerve and necessary for the desensitization of the skin of the upper lip, nostril and face on that side of the level of the foramen [4], therefore; these data are of clinical importance. The injection of local anesthetic agents within the canal via the infra-orbital foramen will also lead to analgesia of the incisor, canine and first two premolars. Furthermore, the infra-orbital foramen is located directly dorsal to the second or third upper premolar tooth in Iranian native horses. This information would provide a major landmark to regional anesthesia involving the infra-orbital nerve in the Iranian native horse.

In the present study, the distance from the lateral alveolar root to mental foramen was 7.4 cm. This parameter is a vital guide that will detect the location of the mental nerve for this regional nerve block in the Iranian native

horse; especially for lower lip anesthesia. The injection of the local anesthetic drugs can be made in the rostral aspect of the mandibular canal through the mental foramen to mandibular nerve block in the mental zone. This will ensure the loss of sensation of the lower incisors, premolar and lower lip on the same side [6] during lower lip trauma, dental extraction and treatment of the tooth injuries.

The mandibular length and height in the Iranian native horses (Table 1) were higher than the data obtained for early medieval horses in Poland [12]. Similar results had been reported in the values of the distances between the mandibular foramen to base of mandible, the condyloid fossa to height of mandible and condyloid fossa to the base of the mandible [12].

The caudal border of the mandible to below of the mandibular foramen was 5.85 cm in the Iranian native horses. In addition, the distance from the caudal border of mandible to the level of mandibular foramen and from the latter to the border of mandibular angle was 4.8 cm and 6.4 cm, respectively. The anesthetic agents must to be injecting on the medial side of the mandible's ramus, thereby; a successful nerve block produces anesthesia of the lower jaw with its teeth and the lower lip. These data are necessary for achieving the regional anesthesia of the mandibular nerve and also have clinical importance for desensitization of all the teeth in lower jaw [6].

To best knowledge of the author, there is no literature data on the morphometric parameters of the head region in the Iranian native horse with which comparisons could be made. In conclusion, the morphometric values of the skull and clinical anatomy of the head region of the Iranian native horse provide an important baseline for further research in this field. Furthermore, these results are of clinical importance that will aid the regional anesthesia of the various nerves around the head especially during treating head injury and dental extraction.

## ACKNOWLEDGEMENTS

The author wish to acknowledge Mr. Aaref Nooraii for help with the preparation of heads and Mr. Ali Akbar Hosseinzadeh for his assistance with photographing the skulls.

## REFERENCES

1. Getty, R., 1975. Sisson and Grossman's The Anatomy of the Domestic Animals, ed 5. Philadelphia, WB Saunders.

2. Karimi, I., V. Onar, G. Pazvant, M. Hadipour and Y. Mazaheri, 2011. The cranial morphometric and morphologic characteristics of Mehraban sheep in western Iran. *Global Veterinaria*, 6(2): 111-117.
3. Wehausen, J.D. and R.R. Ramey, 2000. Cranial morphometric and evolutionary relationships in the northern range of *Ovis Canadensis*. *Journal of Mammalogy*, 81: 145-161.
4. Ommer, P.A. and K.R. Harshan, 1995. Applied anatomy of domestic animals, 1<sup>st</sup> Edition. Jaypee brother's medical publisher, India.
5. Dyce, K.M., W.O. Sack and C.J.G. Wensing, 2002. Textbook of Veterinary Anatomy, ed 3. Philadelphia, WB Saunders.
6. Hall, L.W., K.W. Clarke and C.M. Trim, 2000. Wright's Veterinary Anesthesia and Analgesia. 10. ed. London, ELBS and Bailliere Tindall.
7. Louei Monfared, A., H. Naji and M.T. Sheibani, 2013. Applied Anatomy of the Head Region of the Iranian Native Goats (*Capra hircus*). *Global Veterinaria*, 10(1): 60-64.
8. Radinsky, L., 1984. Ontogeny and phylogeny in horse skull evolution. *Evolution* 38: 1-15.
9. Evans, K.E. and P.D. McGreevy, 2006. Conformation of the Equine Skull: A Morphometric Study. *Anatomia, Histologia, Embryologia*, 35: 221-227.
10. Pérez, W. and E. Martin, 2001. An explanation of a groove found on the nasal process of the equine incisive bone. *Anatomia, Histologia, Embryologia*, 30(6): 357-358.
11. Simoens, R., R. Poles and H. Lauwers, 1994. Morphometric analysis of foramen magnum in pekingese dogs. *American Journal of Veterinary Research*, 55: 33-9.
12. Pasicka, E., A. Chroszcz, M. Janeczek and A. Mucha, 2012. Craniometric analysis of early medieval horses *Equus przewalskii* f. *caballus* (Linnaeus, 1758) from chosen areas in Poland. *Turkish Journal of Veterinary and Animal Sciences*, doi: 10.3906/vet-1107-39.