

Craniometrical and Gross Anatomical Studies on the Skull of the Iranian Buffaloes and Their Clinical Value for Regional Anesthesia

Ali Louei Monfared

Department of Anatomy, Faculty of Para-Veterinary Medicine, University of Ilam, Ilam, Iran

Abstract: In the current work some craniometrical and gross anatomical measurements of the skull of the Iranian buffaloes without any apparent skeletal disorders and their clinical value for regional anesthesia were determined. Eighteen Iranian buffaloes were used and a total of 15 anatomical measurements were done in the upper jaw and mandibles. The distance from the base of horn to caudal border of orbit, to mid-level of dorsal arch of orbit and to rostral border of orbit were 8.4 cm, 11.8 cm and 15.8 cm, respectively. The distances from facial tuberoses to the infra-orbital canal and from the latter to the root of the alveolar tooth were 2.9 cm and 2.7 cm, respectively. The length and height of the mandibles were 29.8 cm and 15.97 cm, respectively. The distances from the lateral alveolar root to mental foramen and from the mental foramen to caudal mandibular border were 6.0 cm and 24.1 cm, respectively. The distances from mandibular foramen to the base of mandible as well as from caudal border of mandible to below of the mandibular foramen were 5.5 cm and 2.97 cm, respectively. The distances from the base of mandible to condyloid fossa and from the latter to the maximum height of mandible were 11.9cm and 2.6 cm, respectively. The distance from caudal border of mandible to mandibular foramen and from the latter to mandibular angle were 1.8 cm and 5.04 cm, respectively. These findings as helpful landmarks are discussed with regard to their application to clinical maneuvers around the head of the Iranian buffaloes such as regional anesthesia during dehorning, treating horn injury and dental extraction.

Key words: Gross Anatomy • Skull • Iranian buffalo • Regional Anesthesia

INTRODUCTION

Iran Country has many areas that buffalo has potential superiority over cattle to reared there. Iranian buffaloes are used for many purposes including milk yield, meat production and draft power. Also, demands for beef have encouraged many farmers to raise them for slaughter [1]. The agriculture ministry of Iranian reported two main groups of buffaloes exist, the first group is centralized mainly in Mazandaran, Guilan and Azerbaijan and second group particularly are in Khuzestan province [2].

A basic knowledge of the skull anatomy is important in the practice of veterinary settings. It has been demonstrated that osteometric examination of bones provides significant insights into intra-species as well

as interspecies differences in the domestic animals [3]. In addition, the anatomical evaluations of animals show considerable variation with respect to breed, age, sex, nutritional situation and environmental factors among others [4].

Gross anatomical surveys on the head region are not only reflect contributions of genetic and environmental components to individual development and describe genetic and ecophenotypic variation, but also are foundations of the clinical and surgical practices [5, 6].

Furthermore, the applied anatomy of the head region is very important because of such vital organs and structures as the brain, tongue, eyes as well as ears, teeth, nose, lips, horn and skull. Thus the head is needed for coordinating the body as well as for deglutition, olfaction and defense [7, 8]. Similarly, the directions of the cranial

nerves and their passages from different foramina in the skull are of clinical importance in regional anesthesia around the head [7, 9].

There has been an increasing interest and necessity to have more information concerning the applied anatomy of the head region of domestic animals. Some previous studies had been done on the heads of livestock including the sheep, cow and goat [5, 8, 10]. However, data is very little about craniometrical and gross anatomical aspects of the head region in the Iranian buffaloes and its clinical importance in regional anesthesia. Therefore the current work was taken to provide information on clinically important parameters that may aid regional anesthesia of the head of Iranian buffaloes.

MATERIALS AND METHODS

To make the present work, a total of eighteen Iranian buffaloes aged between 5-7-year-old were used. The live animals were first selected during ante mortem examination at Ahwaz abattoir based on parameters of apparent good health and no skeletal disorders. After slaughter, the heads were severed at the occipito-atlantal joint, purchased and processed in the veterinary anatomy laboratory of Shahid Chamran University using the boiling maceration techniques for skeleton preparation that have been reported by Simoens *et al.* [11]. The main steps in skull skeleton preparing briefly are following:

- On the working day, frozen buffaloes head were allowed to thaw.
- Skin and most of the muscles were separated and eyes were enucleated.
- Heads were heated to over 80°C for at least 1 hour in solution of anionic surfactant (detergent) and soap chips.
- Muscles of boiled heads were separated with the aid of forceps and scalpel in running water.
- Further separation of muscles and ligaments from the skulls was done after left in detergent water at least 20-30 minutes.
- Separation of remaining muscles and ligaments from the skull was done after left in 1% sodium hypochlorite solution for at least 24 hours.
- After that, the skulls were left in the above solution, for 48-72 hours with solution, being changed at least twice and clean in running tap water.
- The skulls were then left to dry.

A total of fifteen gross anatomical measurements were done in the upper jaw and mandibles using scale, thread and digital calipers and the results were presented as means±SD in Table 1. These morphometric

Table 1: Mean±SD of the morphometric measurements of the mandibles and upper jaws of Iranian buffaloes (cm).

Morphometric parameter	Mean±SD
A	8.4±0.16
B	11.8±0.29
C	15.8±0.38
D	2.9±0.96
E	2.7±0.38
F	29.8±3.05
G	6.0±0.49
H	24.1±1.16
I	5.5±0.31
J	2.97± 0.26
K	2.6±0.04
L	11.9± 0.59
M	15.97±2.85
N	1.8±0.47
O	5.04±0.02

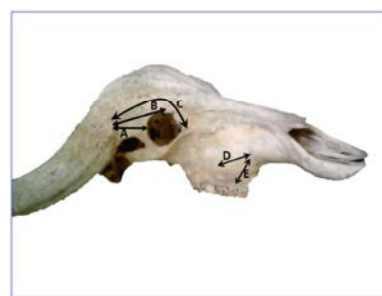

Fig. 1: Skull of the Iranian buffalo; lateral view. A: The base of horn to caudal border of orbit, B: The base of horn to mid-level of dorsal arch of orbit, C: The base of horn to rostral border of orbit. D: Facial tuberosities to infra-orbital canal, E: Infra-orbital canal to root of alveolar tooth.

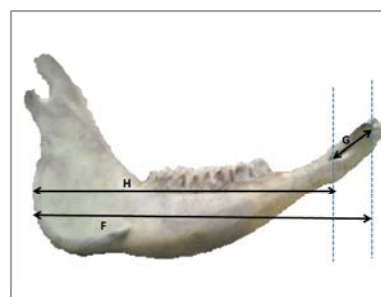


Fig. 2: Mandible of the Iranian buffalo; lateral view. F: Mandibular length, G: Lateral alveolar root to mental foramen, H: Mental foramen to caudal mandibular border.

parameters of the upper and lower jawbones of the Iranian buffalo's skulls are defined below and shown in Figs. 1-4.

The Base of Horn to Caudal Border of Orbit: The distance between the base of the horn to caudal most border of the orbit.

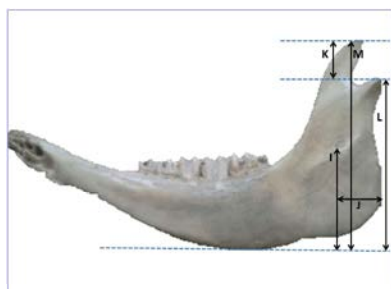


Fig. 3: Mandible of the Iranian buffalo; medial view. I: Mandibular foramen to base of mandible, J: Caudal border of mandible to below of the mandibular foramen, K: Condylod fossa to height of mandible, L: Condylod fossa to the base of the mandible, M: Maximum mandibular height.



Fig. 4: Mandible of the Iranian buffalo; medial view. N: Caudal border of mandible to the level of mandibular foramen, O: Mandibular foramen to mandibular angle.

The Base of Horn to Mid-level of Dorsal Arch of Orbit:

The distance between the bases of the horn to the mid-level of dorsal arch of the orbit.

The Base of Horn to Rostral Border of Orbit:

The distance between the base of the horn to rostral most border of the orbit.

Facial Tuberosity to Infra-Orbital Canal: From the level of the most lateral bulging of the facial tuberosity to the mid level of the infra-orbital canal.

Infra-Orbital Canal to Root of Alveolar Tooth:

Measurement is taken vertically from the mid-level of the in infra-orbital canal to the root of the alveolar tooth.

Mandibular Length: From the level of the cranial extremity of the alveolar root of the incisor to the level of the caudal border of the mandible.

Lateral Alveolar Root to Mental Foramen: Shortest distance from the mental foramen to the lateral extent of the alveolar root of lower incisor.

Mental Foramen to Caudal Mandibular Border: From the level of the mental foramen to the extreme caudal border of the mandible.

Mandibular Foramen to Base of Mandible: Vertical line from the ventral limit of the mandibular foramen to the base of the mandible.

Caudal Border of Mandible to below of the Mandibular Foramen: Length from the caudal most border of the mandible to the vertical line produced by description of measurement of mandibular foramen to base of the mandible.

Condylod Fossa to Height of Mandible: From the maximum height of mandible to the condylod fossa.

Condylod Fossa to the Base of the Mandible

Maximum Mandibular Height: From the basal level of the mandible to the highest level of the coronoid process.

Caudal Border of Mandible to the Level of Mandibular Foramen

Mandibular Foramen to Mandibular Angle: Shortest distance from the mandibular foramen to the extreme caudal border of the angle of the mandible.

RESULTS

In this study, the distance from the base of horn to caudal border of orbit, to mid-level of dorsal arch of orbit and to rostral border of orbit were 8.4 cm, 11.8 cm and 15.8 cm, respectively (Figure 1, Table 1). The distances from facial tuberoses to the infra-orbital canal and from the latter to the root of the alveolar tooth were 2.9 cm and 2.7 cm in the Iranian buffaloes (Figure 1, Table 1). The distances from the lateral alveolar root to mental foramen and from the mental foramen to caudal mandibular border were 6.0 cm and 24.1 cm, respectively (Figure 2, Table 1). The length and height of the mandibles in the Iranian buffaloes were 29.8 cm and 15.97 cm, respectively. The distances from mandibular foramen to the base of mandible as well as from caudal border of mandible to below of the mandibular foramen were 5.5 cm and 2.97 cm, respectively. The distances from the base of mandible to condylod fossa and from the latter to the maximum height of mandible were 11.9 cm and 2.6 cm, respectively. The distance from caudal border of mandible to mandibular foramen and from the latter to mandibular angle were 1.8 cm and 5.04 cm, respectively.

DISCUSSION

Dehorning of cows and buffaloes is carried out to make handling of animals safer and reduce the incidence of damage to other livestock. Alternatively, for animal dehorning and similar surgeries; the corneal nerve supply must be blocked. Although there was not literature data on the horn morphometric indices with which comparison

could be made but these data have clinical value in the nerve block purposes and also regional anesthesia during dehorning and treating of the horn injuries.

Literature review shows the nerve supply to the horn region in the buffaloes and cows is originated from the corneal branches of the lachrymal (zygomatiko-temporal) nerve and this must be blocked prior to dehorning [12]. As the corneal branch of the lachrymal nerve is course dorsal on the dorso-lateral aspect of the orbit and distributed in the root of the horn [13], therefore the value of distance from the base of horn to caudal border of orbit is most beneficial for determining the appropriate side for injection of local anesthetic agents.

The distance from the infra-orbital canal to the root of the alveolar tooth were 2.7 cm in the Iranian buffaloes (Figure 1, Table 1); while in the adult buffaloes from Pakistan were 3.81 cm [14].

The facial tuberoses is very prominent as a guide for tracking the infra-orbital nerve and necessary for the desensitization of the skin of the upper lip, nostril and face on that side of the level of the foramen, therefore the current findings are of clinical importance. The injection of local anesthetic agents within the canal via the infra-orbital foramen will also lead to analgesia of the incisor, canine and first two premolars. In the present work, the infra-orbital foramen was situated directly dorsal to the first upper premolar tooth in Iranian buffaloes where as in the adult buffaloes from Pakistan [14]. This information together with the observed distance of 2.7 cm between the root of the teeth and the foramen would provide a helpful landmark to regional anesthesia involving the infra-orbital nerve in the Iranian buffaloes.

The distance between lateral alveolar roots to mental foramen was 6.0 cm (Figure 2, Table 1) which is a vital guide that will detect the location of the mental nerve for this regional nerve block in the Iranian buffaloes. Although, there was not previous data on the alveolar root length with which comparison could be made. The injection of the local anesthetic drugs can be made in the rostral aspect of the mandibular canal through the mental foramen to mandibular nerve block in the mental zone. This will ensure the loss of sensation of the lower incisors, premolar and lower lip on the same side [9] during dental extraction and treatment of tooth injuries.

The mandibular length and height in the Iranian buffaloes (Table 1) were similar to the data reported for adult buffaloes from Pakistan [14]. By contrast, the mandibular length of 29.8 cm and maximum mandibular height of 15.97 cm in Iranian buffaloes were higher than the value obtained for adult cows from Pakistan [14].

The caudal border of the mandible to bellow of the mandibular foramen (Figure 3) was 2.97 cm in the Iranian buffaloes. Also, in the present study, the distance from the caudal border of mandible to the level of

mandibular foramen and from the latter to the border of mandibular angle were 1.8 cm and 5.04 cm, respectively (Figures 3 and 4, Table 1). These data are necessary for achieving the regional anesthesia of the mandibular nerve and also have clinical importance for desensitization of all the teeth in lower jaw [9].

Although, to best knowledge of the author, there is no literature data on the craniometrical and gross anatomical indices of the head region especially about horn's applied anatomy in the Iranian buffaloes with which comparisons could be made. The findings of the current work will find consideration as reference data for Iranian buffaloes and will thus contribute to craniometric investigations.

In conclusion, the present results are of clinical importance that will aid the regional anesthesia of the different nerves around the head especially during dehorning, treating horn injury and dental extraction.

ACKNOWLEDGEMENTS

The author would like to thank Ms. Dr. Hajar Azizian and Mr. Abdorrahman Fathi for their help with the preparation of heads.

REFERENCES

1. Shokrollahi, B., 2010. Isolation and characterization of microsatellite markers for Iranian buffalo. In: Department of animal science, PhD Dissertation, pp: 191. Tehran: Islamic Azad university-Science and Research branch.
2. Bagheri, S., C. Amirinia and M. Chamani, 2012. Identification of Factor XI Deficiency in Khuzestan Buffalo Population of Iran. *Global Veterinaria*, 8(6): 598-600.
3. Rowley-Conwy, P., 1998. Improved separation of neolithic metapodials of sheep (*Ovis*) and goats (*Capra*) from Arenne Candide Cave, Liguria, Italy. *Journal of Archaeological Science*, 25: 251-258.
4. Outram, A. and P. Rowley-Conwy, 1998. Meat and marrow utility indices for horse (*Equus*). *Journal of Archaeological Science*, 25: 839-849.
5. Karimi, I., V. Onar, G. Pazvant, M. Hadipour and Y. Mazaheri, 2011. The cranial morphometric and morphologic characteristics of Mehraban sheep in western Iran. *Global Veterinaria*, 6(2): 111-117.
6. Wehausen, J.D. and R.R. Ramey, 2000. Cranial morphometric and evolutionary relationships in the northern range of *Ovis Canadensis*. *Journal of Mammalogy*, 81: 145-161.
7. Dyce, K.M., W.O. Sack and C.J.G. Wensing, 2002. *Textbook of Veterinary Anatomy*, ed 3. Philadelphia, WB Saunders.

8. Olopade, J.O. and S.K. Onwuka, 2005. Some Aspects of the Clinical Anatomy of the Mandibular and Maxillofacial Regions of the West African Dwarf Goat in Nigeria. *International Journal of Morphology*, 23(1): 33-36.
9. Hall, L.W., K.W. Clarke and C.M. Trim, 2000. *Wright's Veterinary Anesthesia and Analgesia*. ed 10. London, ELBS and Baillierre Tindall.
10. Louei Monfared, A., H. Naji and M.T. Sheibani, 2013. Applied Anatomy of the Head Region of the Iranian Native Goats (*Capra hircus*). *Global Veterinaria*, 10(1): 60-64.
11. Simoens, R., R. Poles and H. Lauwers, 1994. Morphometric analysis of foramen magnum in pekingese dogs. *American Journal of Veterinary Research*, 55: 33-39.
12. Ommer, P.A. and K.R. Harshan, 1995. *Applied anatomy of domestic animals*, 1st Edition. Jaypee brother's medical publisher, India.
13. Getty, R., 1975. *Sisson and Grossman's The Anatomy of the Domestic Animals*, ed 5. Philadelphia, WB Saunders.
14. Shahid, R.U. and F. Muhammad, 2001. Comparative gross anatomical study of the axial skeletons of buffaloes and cows. *Pakistan Veterinary Journal*, 21(1): 55-56.