

## Hardware Disease in Bovine (Review Article)

*Mulugeta Anteneh and V. Ramswamy*

Department of Clinical Medicine, Faculty of Veterinary Medicine,  
University of Gondar, Gondar, P. O. Box 196, Ethiopia

---

**Abstract:** Hardware disease is the term used when complications occur after an animal consumes metallic objects such as nails, wires, needles, or even tin cans. This condition is particularly associated with bovine as they do not use their lips to discriminate between materials and they do not completely chew their feed before swallowing. A hardware disease is not limited to cattle and it is not restricted to animals simply grazing. Commercial food producers go to great lengths to keep foreign materials out of their products but objects have been known to slip in unknowingly including metallic materials. When hay is cut and baled, debris in hay fields can also be trapped in the bales and innocently fed to cattle. Once these penetrating sharp foreign bodies of the needle and fish hook type enter the animal, they may penetrate any part of the digestive tract. These may be the mouth, the esophagus, the pharynx, the stomach, the intestine, the diaphragm, the pericardium or any visceral organs, which can lead to death of the animal if not intervened. Surgical and conservative interventions are done to save the life of the animal. There are basically two ways to prevent hardware disease. One is to limit animals' access to small metallic objects. The second way is to place rumen magnets in all your animals.

**Key words:** Hardware disease • Metallic foreign bodies • Cattle

---

### INTRODUCTION

Cattle commonly ingest foreign objects because they do not discriminate against foreign bodies in feed and do not completely masticate feed before swallowing [1]. The presence of foreign bodies is not infrequently encountered in digestive tract of animals. Their progress through the canal or their retention at some point may cause only slight disturbance of health. On the other hand such objects may gravely threaten the life of the animal. Sharp foreign bodies of the needle and fish hook type may penetrate any part of the digestive tract. These may be lodged in the mouth, the esophagus, the stomach, the intestine, the diaphragm or the pericardium [2]. However, if sharp object is known to have reached the stomach safely, the feeding of the cotton-wool to the patient will result in the foreign body becoming entangled in the fibers as in a cocoon and it may then pass through the canal in safe manner [3].

The typical foreign body often encountered is metallic object, such as a piece of wire or nail, usually greater than 2.5cm in length [4]. Heavy foreign materials

(nails, wires) may remain in the reticulum for the life of the cow. If the foreign objects puncture the heart, which is in close proximity to the reticulum, sudden death occurs [5].

The nature of wire varies in a great deal and influences the likelihood or otherwise of its penetration. Straight, sharp, piece of baling wire and more particularly fragments of steel that may emanate from discarded wire ropes used in mining areas, are the most dangerous. Short length or bent wire or pieces of wire with rough and rusty surface, as well as soft wire which bends easily under pressure, are less likely to puncture the stomach wall [6]. On the other hand pieces of rusted and rotted wire netting only 0.5 inch length, thin and very sharp are exceedingly dangerous, although some of these pass through the stomach and has been found in the intestinal contents and discovered one length of wire derived from the netting which had rusted away from an old fence, which had penetrated the small intestine and riveted the two sides of the bowl together. One Veterinary assistant cut his arm badly while calving of a cow, up on a piece of steel wire which had penetrated the uterine wall [2].

---

**Corresponding Author:** Mulugeta Anteneh, Department of Clinical Medicine, Faculty of Veterinary Medicine, University of Gondar, Gondar, P. O. Box 196, Ethiopia.

Potential foreign bodies like wires, nails and needles may cause other complications apart from Traumatic reticulo-peritonitis (TRP). Sequels to potential Foreign bodies (FBs) may include traumatic sternabrae, traumatic pericarditis, vagal indigestion, pyothorax, abscessation of liver and spleen, diaphragmatic hernia, traumatic pneumonia and pleurisy. In most of instances, foreign bodies are found located in the abscess behind the shoulder, when it was lanced for drainage or may drop down themselves [7].

Wires account for approximately 70% of ingested foreign bodies. Nails and steel objects make up the other 30%. Most FBs are ferromagnetic which argues for therapeutic or prophylactic administration of magnets. The use of magnets placed in feeders or administered prophylactically to cattle explains why the prevalence of TRP has noticeably decreased in the last two decades [8].

Therefore, the objectives of this review article are:

- ▶ To review the occurrence of hardware diseases in cattle
- ▶ To discuss the risk factors and pathogenesis of hardware diseases in cattle
- ▶ To suggest possible treatment and preventive measures.

**Sources of Foreign Bodies:** Cattle acquire hardware disease most commonly when they feed green chop, silage and hay which are collected from fields that contain old rusting fences or balling wire, or when pastures are areas or sites where buildings have recently been constructed, burned or torn down. The grain ration may also be a source due to accidental contamination with metallic objects [1].

Metallic debris is encountered more commonly in processed feeds and forages rather than on pasture. Cattle can also acquire linear foreign material when they are exposed to construction sites or to deteriorating buildings and fences [9]. Balling or fencing wire passed through a chaff-cutter, feed chopper or forage harvester is a commonest source. The foreign bodies may be in the roughage or concentrate or may originate on the farm, when repairs made to fences, yards and in the vicinity of trough [10].

**Types of Metallic Foreign Bodies:** Cattle are very prone to pick up and swallow metallic foreign bodies of various kinds, including needles, nails staples, twine, wire, umbrella ribs and pieces of iron. Wires account for approximately 70% of ingested foreign bodies. Nails and steel objects make up other 30% [8].

### **Epidemiology**

**Occurrence:** Cattle are more likely to ingest foreign bodies than small ruminants since they do not use their lips for prehension and more likely to eat a chopped feed [11]. The majority of affected cattle are dairy and are older than two years of age [1]. Cattle are inquisitive and tend to consume all sorts of objects while foraging [3]. But small ruminants are selective feeders and ingest significantly less amount of foreign bodies compared to cattle [12].

The disease is usually sporadic but outbreaks have occurred when source of wire have become mixed in to feed supplies. Adult dairy cattle are most commonly affected because of their more frequent exposure [10].

**Risk Factors:** According to [13], there are a number of risk factors. These includes remodeling of live stock housing, careless handling of balling wires, pins, feed sack bags and wires, using old buildings, sites for hay fields, often occur in female shortly after calving or often occur in male shortly after or during extensive uses for breeding, field chopper pick up metal (baler), mineral deficiency, pica eating habits and those following pregnancy examination. Ingestion of foreign bodies is still extremely common in cattle and buffaloes especially in developing countries where the standard of animal management is unsatisfactory [14].

The disease is common when green chop, silage and hay are made from fields that contain old rusting fences or balling wire, or when pastures are on area or sites where buildings are recently constructed, burned or torn down. The grain ration may also be a source due to accidental addition of metal [1]. The disease is much more common in cattle fed on prepared feeds, especially those fed inside for part of the year. It is almost unknown in cattle fed entirely on pasture [10].

The indiscriminate feeding habits and mineral deficiency make them susceptible to inadvertent ingestion of foreign materials [7]. Industrialization and mechanization of agriculture have further increased the incidence of foreign bodies in these animals [14]. Cattle kept in close proximity to stable and usual farm steed activities often swallow discarded nails, bits of wire and similar hard ware [11].

**Economic Importance:** The hard ware disease contributes for the loss of major economies of the live stock industry as it causes of the severe loss of production and the high mortality rate[10]. The plastic bags along with other foreign bodies which are ingested along with feed in cattle affect the health and cause economic loss to the owner [15].

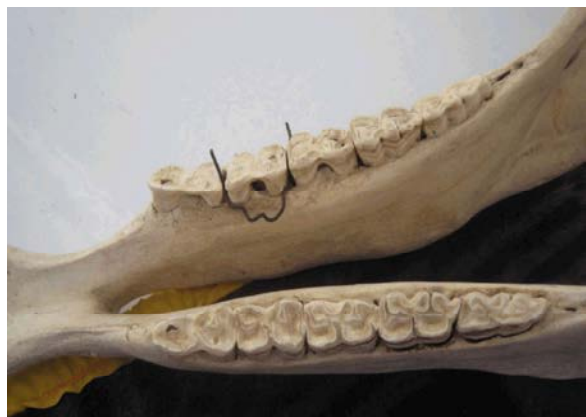

Fig. 1: Wire wedged between premolars (Source: [18]).

**Etiology:** Cattle commonly swallow foreign objects, because they do not use their lips to discriminate between materials and they do not completely chew their feed before swallowing. Sharp metallic objects, such as nails or wire, are the common causes of hardware disease. The object travels into the rumen and is then pushed into the reticulum along with the rest of the feed. In some cases, contractions of the reticulum can push the object through part of the reticulum wall into the peritoneal cavity, where it causes severe inflammation [16].

In rare cases, the metal object penetrates the entire wall of the reticulum, diaphragm and can pierce the heart sac, causing traumatic pericarditis (TP). Compression by the uterus in late pregnancy, straining during parturition and mounting during estrous can increase the likelihood of the object penetrating the abdominal wall or the heart sac [7].

**Metallic Foreign Bodies of Oral Cavity:** The lips of cattle are relatively immobile and insensitive, which presumably contribute to the indiscriminate eating habits of cattle [17].

**Pathogenesis:** Once the metal ingested, injury is always possible owing to incomplete mastication and the tendency of cattle to pick up metallic foreign materials, objects may wedge between posterior molars (Fig 1) and interfere with rumination [3].

Oral laceration in cattle is associated with the same indiscriminate eating habit which results in traumatic reticulo-pericarditis. Lacerations are more common in calves because of their oral prehension and suckling habits on objects in their environment such as barbed wire, needles, bones and thorns. The laceration may involve lips, buccal membranes, soft palate and tongue [17].

Size, shape, location, strength and degree of contamination govern the pathogenicity and clinical manifestation of the diseases. For instance if the animal ingests a twisted wire, first it will lodge between posterior molars and disturb mastication and if measures are not taken early, it will cause laceration of buccal cavity and leads to the formation of an abscess. If the cheek muscle is perforated it results in abscessation of mandible and cause osteomyelitis [7].

**Clinical Signs:** Animals usually present with excess salivation which may be mixed with blood, decreased appetite and various degree of dysphagia depending on the severity of laceration. The animal's tongue often protrudes past its lip [17].

**Diagnosis:** The diagnosis is based on clinical examination and physical examination of the animal after administration of sedatives or general anesthesia in non cooperative animals [17].

**Treatment:** Most lacerations heal without surgical intervention by using daily mouth lavage and systemic antibiotics and by feeding soft diet [8].

Severe tongue lacerations sometimes require a partial glossectomy. In preparation for surgery, the animal is anesthetized and placed in lateral recumbency. A tourniquet is applied proximal to the intended transection site. The tongue is transected so that the dorsal and the ventral aspect protrude beyond the center. The dorsal and ventral aspects are sutured together with an interrupted horizontal mattress pattern with a number one or two absorbable suture materials [17]. The animal should receive systemic antibiotics post operatively and should be fed a soft feed for best results [10].

**Metallic Foreign Bodies of Pharynx:** Due to foreign bodies like nails and pieces of wires, which get lodged in the pharynx, occurs occasionally in cattle to cause traumatic pharyngitis [19].

**Pathogenesis:** Pharyngeal or retro pharyngeal abscessation is commonly encountered. More frequently these are the result of trauma to the mucosa of pharynx from sharp objects. In fact a number of oropharyngeal trauma and retropharyngeal cellulitis [17], results from too vigorous use of balling guns or dose syringes, particularly during deworming [3].

**Clinical Signs:** Cattle become anorexic and have associated with reduced milk yield [17]. In most instances the animal will show little discomfort at the time of injury. Some days or even weeks latter a swelling will be noted in the pharyngeal area as an abscess develops. These abscesses are usually slow in developing, as in the case of a six month old calf presented for bloat because of the abscess enlarged internally, compressing the trachea and esophagus [3].

The affected animals keep their head extended and are reluctant to eat. There is acute pain. In a few cases with extensive injury or if the foreign body penetrates the lateral wall of the pharynx, diffuse swelling in the pharyngeal area is evident from the outside. Drooling of saliva is seen in most cases. The animal attempts to drink water due to thirst but is unable to swallow it with the resultant flow of water from the mouth [19].

**Diagnosis:** Diagnosis must be made based on the history and a good physical examination [3]. Endoscopic, or open mouthed, examination of the nasopharynx and oropharynx will reveal the laceration and/or abscess [17]. Lateral plain radiograph of the pharyngeal region helps to locate radiopaque foreign bodies [19].

**Treatment:** The treatment principle is to limit the extension of the cellulites with appropriate parenteral antimicrobials and surgical drainage [17]. In majority of the cases, it is possible to remove the foreign bodies after slight sedation and insertion of a mouth gag or on general anesthesia. Large artery forceps can be used to retrieve nails and wires. In cases where foreign bodies have penetrated the lateral wall of the pharynx and caused abscess formation, the abscess is opened from the outside to drain pus and also to retrieve the foreign body [19].

#### **Metallic Foreign Bodies of the Esophagus**

**Esophageal Obstruction (Choke):** Obstruction of the esophagus occurs in all animals, but it is most common in bovine, which are very prone to pick up foreign bodies and bolt them, especially during pregnancy. The cause of the lodgment of the obstruction may be its large size, its having sharp projections, which get fixed in the esophageal wall and stricture of the esophagus spasm of its muscle [20]. Even though complete obstruction of the esophagus is caused by non penetrating foreign bodies, metallic foreign bodies also produce partial obstruction of the esophagus [21]. In ruminants, obstruction occurs

mostly in the cervical region and obstruction of the thoracic esophagus is rare [19] because of its compression between the trachea and the first rib [20].

**Pathogenesis:** An esophageal obstruction results in a physical inability to swallow and, in cattle inability to eructate, with resulting bloat. Complication of esophageal obstruction includes laceration and rupture of the esophagus, esophagitis, stricture and stenosis and the development of diverticulum [10].

**Clinical Signs:** A farmer suspect this condition mostly by observing a swelling in the ventral neck region and inability of the animal to swallow feed and water. There is salivation and the animal keeps the neck stretched. The patient remains thirsty and makes attempts to drink water which often returns back through the nostril carrying food particles with it. Regurgitation of swallowed feed and water may cause aspiration pneumonia. Sever tympany occurs only if the obstruction is complete, due to inability of eructation of the gases produced by fermentation in the rumen [3]. If the obstruction persists for a longer duration and treatment is delayed, pressure necrosis of the mucosa may lead to perforation [19].

**Diagnosis:** Physical examination findings are used to diagnose esophageal disease along with endoscopy, radiology and ultrasound examination. Passage of a stomach tube through a Frick speculum used to localize intra luminal obstruction [17].

**Treatment:** In case of complete esophageal obstruction, relieving bloat is the first concern. Passage of stomach tube may be attempted if the animal is not in respiratory distress. Trocharization of the rumen or installation of a temporary fistula may be required [21]. One may pass a stomach tube and try to push the object in to the stomach. If the object lodges the cardia, a rumenotomy may have to be performed to allow the surgeon to reach through the cardia and retrieve the obstructing object, thereby allowing gas to escape [17].

Esophagotomy has been performed for those in the cervical region that are not relieved by conservative treatment [3].

For esophagotomy, the esophagus is occluded either by placing a tape around it or by atraumatic clamps placed proximal and distal to the foreign body. The operative field is suitably packed off to avoid any possible contamination. If the esophagus appears normal, a longitudinal incision is made directly over the foreign

body. If the esophagus wall is damaged but tissue is viable, the incision should be made in the healthy tissue either proximal or distal to the foreign body. The wound edges are swabbed and the obstructing mass is removed. To close the esophageal incision, two rows of sutures are preferred, first layer being Connell and second of either simple interrupted or Cushing. Absorbable suture material should be used while applying second layer, surrounding fascia should be included into the suture bites to strengthen the suture line [19].

Post operatively the animal should be withheld from feeding for 5 to 7 days. They should receive fluids as 5% dextrose intravenously. Broad spectrum antibiotic should be given systematically at least for 3 to 5 days [3].

**Esophageal Fistula:** Forceful introduction of a probang, trauma from outside or due to ingestion of foreign bodies may cause perforation and rupture of the esophagus. Escape of swallowed air from the esophagus in the cervical region results in subcutaneous emphysema. If rupture occurs in the thoracic area, unilateral pneumothorax may occur [19].

**Pathogenesis:** Saliva and feeds escape into the surrounding tissues to cause infection and severe cellulitis. An abscess may also form. These events cause edema of the ventral aspect of the neck and the extent of changes depend on the size of perforation and duration of leakage. Perforation of the thoracic esophagus may lead to mediastinitis and if communication with pleura exists, pleurisy may occur [19].

**Clinical Signs:** The signs are self evident. In complicated cases, there is pyrexia and hyperpnoea. Auscultation and percussion will show marked resonance on the affected side with faint lung sounds [19].

**Diagnosis:** Physical examination and plain radiographs are used in the diagnosis of esophageal fistula [17].

**Treatment:** The wounds of the esophagus should be treated on general principles keeping in view the complications involved. If the edges of the esophageal wound are extensively devitalized, sutures may not hold. In such a case, the wound is treated as an open wound with drainage tube inserted in to the space [19].

Application of moist heat or infrared rays accelerates the healing process. If mediastinitis or pleurisy occurs, a heavy dose of antibiotics will be required. In the case of valuable animals, if adequate facilities exist, thorax may be

opened in attempt to close the perforation of the thoracic esophagus. If necessary, fistula can be resected out and anastomosed [19].

**Esophago-tracheal Fistula:** Ingestion of sharp metallic foreign bodies is the usual cause. The leakage of esophageal contents into the trachea will cause cough while drinking water or during feeding. The animal may develop bronchitis or pneumonia, pyrexia and tympany are also recorded. A localized hard and pain full swelling may be palpated in the cervical region at the site of lodgment of foreign bodies [17].

**Diagnosis:** Plain and contrast radiographs along with clinical sign and history help to arrive at a diagnosis [3].

**Treatment:** Surgical treatment is possible in such cases. The area is exposed and foreign body removed, if possible, or otherwise esophagotomy may have to be done to remove the foreign body. The adhesion between the trachea and the esophagus are carefully separated and defects of the esophagus and trachea are corrected. Post operatively, food and water is with held for 3 to 5 days and the animal is given adequate fluid therapy along with heavy dose of antibiotics [19].

**Metallic Foreign Bodies of Reticulum:** When a foreign body is ingested, it gets lodged into the honey comb pattern of the reticulum after passing through the pharynx and esophagus. Non potential foreign bodies like nuts, coins and stones lie harmlessly and may be passed out ultimately through the faces. However, potential foreign bodies like nails, needles and sharp wires may cause other complications apart from reticulitis [19].

Once the ingested potential metallic foreign body reaches the stomach, it causes laceration and perforation of the reticular wall and then the visceral and parietal layers of the peritoneum to cause traumatic reticuloperitonitis[3].

**Pathogenesis:** Once swallowed metallic objects reach the stomach then fall directly into the reticulum or pass into the rumen and are subsequently carried over the rumenoreticular fold into the cranioventral part of the reticulum by ruminal contraction. The elevated reticulo-omasal orifice is above the floor, tends to retain heavy objects in the reticulum and the honey comb-like reticular mucosa traps sharp objects [1]. Increased intra abdominal pressure due to advanced gestation, tympany, intussusceptions, sudden fall, accident, parturition,



Fig. 2: Abscessation behind the elbow (source: [22]).

straining and mounting during estrus increase the likelihood of an initial penetration of the reticulum and may also disrupt adhesion caused by an earlier penetration [7].

Perforation of the wall of the reticulum allows leakage of ingesta and lead to bacterial infection and peritonitis which is generally localized and frequently results in adhesions. Less commonly, a more severe peritonitis develops [1]. Occasional cases have been reported in which the penetration of the reticular wall has been on its lateral face, this has resulted in penetration in to the thorax and abscess formation behind the elbow region (Fig 2) [19]. Although foreign bodies do not commonly enter the rumen, they have been known to penetrate its walls, pass to the exterior, usually along the abdominal floor and establish a rumen fistula [2].

**Clinical Signs:** The symptoms shown by animal affected with a foreign body puncture of the stomach may be quite be variable and depends on a number of factors, including size, shape and nature of the foreign body, location and degree of damage at the puncture site and degree of contamination at the time of and subsequent to puncture [3]. While some foreign bodies of metal and other heavy material are quite common in the reticulum of cattle, it is only when a sharp pointed object penetrates the wall of the compartment that signs of discomfort or ill health are shown [2].

The most common clinical manifestations in cattle and buffaloes are recurrent tympany, complete or partial anorexia, retarded or suspended rumination and sudden reduction in milk yield, stiffness of the fore limbs and abducted elbows may be seen in cattle and buffaloes [19].

Initially the cow exhibits an arched back, an anxious expression, reluctance to move and an uneasy, careful gait. Forced sudden movements as well as defecating, urinating, lying down, getting up and stepping over barriers may be accompanied by groaning [1].

The appetite of the patient is irregular there may be evidence of diarrhea or constipation, temperature and pulse will show a slight increase [2].

**Diagnosis:** This can be based on history (when available) and clinical findings if the cow is examined when signs initially appear. A grunt may be elicited by applying pressure to xiphoid or by evaluating this area firmly and then pinching the withers which causes extension of the thorax and lower abdomen. The grunt can be heard by placing a stethoscope over the trachea and apply pressure or pinching the withers at the end of an inspiration [1].

A lateral plain radiograph of the reticular area is useful diagnostic aid. Apart from locating foreign bodies, the radiograph also provides sufficient information concerning the nature and extent of the damage caused by potential foreign body [19]. Although always not necessary laboratory tests may be helpful. In many cases there is a neutrophilia with a left shift; increase in fibrinogen and, in chronic cases, total plasma protein concentration may be high. The acid base status and serum electrolyte levels are typically normal because abomasal and small intestinal absorption can remain normal. However, marked hypokalemic, hypochloremic metabolic alkalosis can be seen presumably, because a dynamic ileus from peritonitis can affect abomasal and GIT motility and resorption of abomasal secretions. Electronic metal detectors can identify metal in the reticulum but do not distinguish between perforating and non-perforating foreign bodies [1].

**Treatment:** Treatment of the typical case seen early in its course may be surgical or medical. Medical treatment involves administration of antibacterials to control and a magnet to prevent recurrence [1] and [19]. Rumenotomy is useful procedure both diagnostically and therapeutically [3]. Rumenotomy is indicated for the removal of metallic foreign bodies whose presence may cause reticulitis or traumatic reticulo peritonitis [23]. The site of incision in cattle is the left flank, in the paralumbar fossa equidistant from the tubercosae and last rib beginning 5 cm ventral to the lumbar transverse process [24].

The site of operation in the high left flank region is clipped, shaved, scrubbed and disinfected and local anesthesia is instituted by line block, inverted L block or paravertebral block [23]. A vertical incision of about 6-8 inches long is made commencing about 2 inches below the level of the lumbar transverse process. The abdominal muscle and the parietal peritoneum are traversed by a direct incision corresponding to the skin incision. The wound is kept retracted and the rumen wall is fixed to the skin edges by applying Weingarts' rumenotomy ring [25].

**Exploration:** Abdominal cavity should be thoroughly explored to examine the wall of the diaphragm, outer wall of the reticulum, spleen and liver for any pathological lesion [19]. A short incision is made on the rumen and this is extended enough to permit easy access by hand into the rumen and reticulum [25]. After the rumen has been stabilized and incised enough, contents should be emptied to permit a through transruminal exploration. If the content of the rumen are mostly fluid, it is possible to drain them by creating a siphon with large bore stomach tube. The position size and consistency of the reticulum, omasum and abomasum can be defined by transruminal exploration. The ruminoreticular fold, esophageal orifice and omasal orifice should be palpated for lesions. The reticulum is meticulously explored for foreign bodies [17]. The exploration inside the reticulum should be with light touch and honey comb cells should be explored with finger tips to find penetrating or coarse foreign bodies. Penetrating foreign bodies are gently removed [19].

The surgeon can also sweep the reticular wall with a magnet in an attempt to find ferromagnetic foreign bodies [17]. Moreover, while exploring the inside of the reticulum, one should also feel for abscesses. Abscesses are frequently found on the medial wall of the reticulum near the reticulo-omasal orifice [23]. Once the abscess has been positively identified, it can be lanced and drained into the reticulum, where the abscess is tightly adhered to the reticular wall. After the abscess is lanced, the abscess cavity is also searched for foreign body [17].

**Replenishing and Closure of Rumen:** The rumen can be inoculated with normal flora or some fresh coarse hay can be placed within the cavity [3]. Before closure of the rumen, rumen pH if disturbed should be corrected by placing the rumen cud from a healthy animal. It would be ideal to introduce symbiotic preparation (combination of probiotics and prebiotics) along with the cud. It will

increase the viability of ruminal flora, increase cellulolysis, establish the anaerobic environment, reduce the operative stress and restore early normalcy [19]. When the stomach has been cleared of its metallic content, closure of the ruminal wound is commenced [2].

The rumen incision is closed with a row of continuous inverting sutures of number 2 or 3 chromic catgut [23]. Cushing's sutures are used to close the rumen commencing slightly above and extending a little below the line of incision. A continuous Lembert's suture is also placed over this [25].

**Closure of Laparotomy Wound:** The abdominal musculature is usually closed in two or three layers by using a simple continuous pattern with number 3 or 2 chromic cat gut. The skin layer is closed with a continuous ford interlocking pattern. It is wise to close the ventral aspect of the skin incision with 2 or 3 simple interrupted sutures [17].

Post operatively, antibiotics are indicated following the removal of foreign bodies from the reticulum. Oral fluids can be administered following rumenotomy and mild osmotic laxatives, such as magnesium hydroxide often promote gut motility [23].

**Metallic Foreign Bodies and Vagal Indigestion:** The development of vagal indigestion may be another consequence of metallic foreign bodies [3]. Vagal indigestion is characterized by gradual development of rumeno-reticular and abdominal distention and thought to be the result of lesions affecting the vagus nerve. However, vagal nerve involvement is not present in all cases [1].

The syndrome of vagus indigestion is characterized by disturbance in the passage of ingesta through the reticulo-omasal orifice (failure of omasal transport) and disturbance in the passage of ingesta through the pylorus [10].

**Pathogenesis:** A foreign body that migrates from the reticulum leads to the formation of adhesion that physically interferes with vagal nerve, thus resulting in permanent forestomach dysfunction [17]. Examination of 42 dairy cows with complications of TRP, it was found that the primary mechanism was a disturbance in particle separation process in the reticulo-rumen attributable to mechanical inhibition of reticular motility associated with extensive inflammatory para-reticular adhesion [10].

There is impairment of the passage of food either through the reticulo-omasal orifice or across the pylorus. The disease may develop as a consequence of primary lesions involving gastro intestinal tract or secondary to a severe disease outside the tract. The lesions are located near the reticulo-omasal orifice or the pylorus. The lesions may include acute or chronic and local or diffused peritonitis, rumenitis, abscesses between different forestomachs or between fore stomachs and the abomasum and chronic TRP [19].

The lesions that are located near to reticulo-omasal orifice commonly due to inflammatory lesions in the vicinity of the vagus nerve, such as localized peritonitis, adhesions (usually after an episode of TRP), or chronic pneumonia, results free gas bloat due to failure eructation. The lesions that are located near to the pylorus, result in failure of omasal transport of ingesta into the abomasum. Adhesions and abscesses (reticular or single liver abscesses) are the most common causes [1].

Disturbance of the passage of the ingesta in cows with TRP develop in three phases. (a) Reticulo rumen motility is decreased because of immobilization of the reticulum caused by the inflammation, pain and fever that impair clearance function of the reticulum. (b) When adhesions are extensive enough, causes additional impairment of reticular motility (c) Change in the consistency of rumen contents resulting in a homogeneous pasty mass of relatively high viscosity [10].

**Clinical Signs:** The extent and location of the vagus nerve lesion (injury) determine the course of the disease and how rapidly it develops [10]. In all cases there is a gradual development (over days to weeks) of rumino-reticular and abdominal distention. Distention of the dorsal and ventral sacs of the rumen result in an 'L' shaped rumen on rectal examination. Left dorsal and right ventral distention of the abdomen cause a 'papple' (pear plus apple) shape [1].

Fecal output is reduced and often contains long hay particles and the rumen develops a 'splashy' fluid consistency. The feces are characteristically very scanty and sticky. Temperature and respiratory rate are usually normal; however, these can be increased depending on the cause. Bradycardia is present in 25-40% of cases. Because bradycardia is uncommonly associated with other conditions, vagal indigestion should be considered in the differential diagnosis in any case in which bradycardia is present [1].

**Diagnosis:** Diagnosis is based on the presence of subacute to chronic reticular and abdominal distention. Because vagal indigestion is by definition a subacute to chronic disease, this diagnosis should not be made in cattle that have not been sick for at least several days, which rules out acute rumen tympanites and acute frothy bloat [1].

Accumulation of fluid within the peritoneal cavity from ascites, peritonitis, or ruptured urinary bladder can be differentiated by paracentesis. Hydrops allantois or amini will also produce severe abdominal distention, but will be differentiated on rectal examination [26].

Physical examination, rectal examination, CBC, blood acid-base determination and serum chemistry values are often use full. Peritoneal fluid analysis can support the diagnosis of peritonitis if total protein or nucleated cells are increased. Radiography of the reticulum should be taken to identify a radiopaque linear foreign body or reticular abscess [1]. The confirmatory diagnosis of vagal indigestion often requires exploratory surgery (left paralumbar fossa laparotomy and rumenotomy[1] and [19].

**Treatment:** Treatment of vagal indigestion should be directed at the removal of the primary cause [19]. If the value of the animal justifies treatment, surgery is almost always needed to identify the underlying cause. Medical management alone is ineffective. A left paralumbar fossa laparotomy and rumenotomy provides the opportunity for definitive treatment in some cases [1].

Rumenotomy and emptying of the rumen is usually followed by slow recovery over a period of 7 to 10 days when there is ruminal hyper motility. The creation of a permanent rumen fistula is to permit the escape of gas, in case where gas retention is a problem and may lead to dramatic improvement [10].

**Metallic Foreign Bodies Penetrating Diaphragm:** Diaphragmatic hernia is defined as the passage of the abdominal viscera in to the thoracic cavity through a congenital or acquired opening in the diaphragm. The penetrating metallic foreign body that lodges in the reticulum may also be perforating the diaphragmatic muscle and cause diaphragmatic hernia and diaphragmatic abscessation, since the diaphragm and the reticulum are close enough [19].

Diaphragmatic hernia has occasionally been reported in cattle but the condition is rarely diagnosed and the incidence is probably less than 1per 100,000 per year [26].



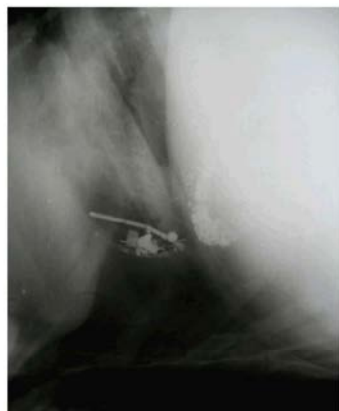

Fig. 3: Lateral radiograph of reticulum showing clearly demarkable diaphragmatic line and presence of potential and non-potential metallic densities cranial to diaphragm (Source: [18]).

Commonly it is the reticulum which herniates into the thorax, however the omasum, abomasum, loops of intestine, spleen or liver may also herniated without exhibiting additional specific clinical sign [19].

**Pathogenesis:** During the process of reticular contractions, the foreign body that penetrates the reticulum, pricks the diaphragm constantly and may make perforation. Sometimes infected foreign bodies may lead abscess formation in the diaphragm [19]. Often adhesions are formed between the reticulum and hernia ring, pleura, lung, pericardium or thoracic wall [3].

**Clinical Signs:** Most affected animals develop recurrent tympany not responding to medical treatment. Adhesion of the esophageal groove and ventral fixation of reticular floor lead to derangement in the normal alignment of the cardia, esophageal groove and reticulo-omasal opening [19].

More severe syndrome is recorded in cases where viscera other than a portion of the reticulum are herniated. Peristaltic sounds may be audible in the thorax and there may be interference with respiration and sign of pain with each reticular contraction [10].

Other signs include abrupt fall in milk yield and scanty defecation or diarrhea with foul smell, Occasional cases may show slight degree of melena [19]. Rumination does not occur, but occasionally animals regurgitate when a stomach tube is passed [10]. In advanced cases regurgitation may lead to aspiration pneumonia. Similarly, brisket edema with or without jugular pulsation and abduction of the limbs may be observed [19].

**Diagnosis:** Diagnosis is based on history (recently parturition, advanced pregnancy) and clinical signs [24]. Physical examination may indicate muffled thoracic auscultation sounds audible from the thorax. Palpation per rectum may indicate a forward position of abdominal viscera and an empty feel to the caudal abdomen in general [8]. For confirmatory diagnosis, plain and contrast radiograph or left flank laparotomy is required [19].

#### **Treatment**

**Stage-I:** The first step in the treatment is laparo-rumenotomy. Almost three fourth contents of the rumen is evacuated. If contents foul smell, a complete evacuation may be necessary. Foreign bodies if present in the rumen and reticulum are removed. Before closure of the rumen, fresh rumen fluid from healthy animal should be transplanted to revive the rumen flora [19].

**Stage-II:** The common approaches for diaphragmatic herniorrhaphy are transabdominal and transthoracic approach. Irrespective of the approach, prior evacuation of the rumen and assisted ventilation during herniorrhaphy are required for the successful outcome of surgery. Some clinicians prefer to wait for 3-4 days after laparo-rumenotomy before undertaking diaphragmatic hernia repair. After the animal is sedated, an endotracheal tube with positive pressure ventilator is secured to the animal [27].

**Transabdominal Approach:** For transabdominal approach, the animal is shifted to supine position and the right cranial quadrant of the abdomen is prepared for surgery. The abdomen is entered through an incision of 25 to 35cm in length, about 5cm caudal to the xiphoid cartilage and running parallel to the costal arch. The adhesions between the reticulum and diaphragmatic ring are severed by blunt dissection. The palm of hand is glided through the ring to carefully break the adhesions between herniated part of the reticulum and thoracic organs. The reticulum is then with drawn into the abdominal cavity and the ring is closed with continuous lock suture, using non absorbable suture material. The suture starts from the lower part of the ring and finally the abdominal wound is closed in two or three layers [28].

**Transthoracic Approach:** For transthoracic approach, right or left lateral thoracotomy is done as per location of the hernia. A cutaneous incision of about 2.5cm in length is made midway on the seventh rib and extended ventrally

to the costo-chondral junction. After the pleura have been incised, the herniated reticulum comes in to view. Adhesions of the reticulum with the lungs, pericardium and pleura are separated carefully by blunt dissection. The reticulum is freed from the ring by breaking the adhesions with a gentle blunt dissection. The reticulum is then pushed in to the abdominal cavity and the ring is closed the same way as in the abdominal approach. The surgical wound is closed in layers i.e. the pleura and the periosteum together, intercostals muscles and then superficial muscles and facials together, by continuous lock stitch sutures using heavy chromic catgut. The skin is sutured routinely [28].

Irrespective of the approach, negative pressure within the chest cavity is created by suction if the air under water seal. The endotracheal tube is removed after swallowing reflex has returned [27]. Post operatively, animals should receive broad spectrum antibiotics for 5 to 7 days and analgesics for 3 to 5 days in addition to adequate fluid therapy [1].

Diaphragmatic hernias even after successful repair can recur in a few cases at a fresh spot in the vicinity of the earlier rupture. This occurs more often in animals which were either in advanced pregnancy at the time of previous surgery or became pregnant soon after repair. Therefore, it is recommended that the operation in case of advanced pregnancy should be postponed to a date after parturition. A rumen fistula can be made to provide relief to the animal till then. Hernioplasty may be done in animals in initial stage of gestation to further strengthen the suture line on the diaphragm. A breeding rest of at least 3 to 4 months should be allowed in pregnant animals after surgery [28].

#### **Metallic Foreign Bodies of Pericardium and Heart:**

Traumatic pericarditis is either an acute, subacute or chronic inflammation of the pericardium often recorded in cattle and buffaloes as a result of penetration of the pericardium by a sharp foreign body [24]. Since the distance from the reticulum to the pericardium is only a few centimeters, a sharp contaminated foreign body easily pierce the diaphragm and enter the pericardium [8]. Perforation of the pericardial sac by a sharp foreign body originating in the reticulum causes pericarditis with the development of toxemia and congestive heart failure [10].

**Pathogenesis:** The penetration of the pericardial sac may occur with the initial perforation of the reticular wall [3]. However, the animal may have had the history of TRP




Fig. 3: Brisket edema due to traumatic pericarditis (Source: [18].

some times previously, followed by pericarditis, usually during late pregnancy or at parturition [10]. The increased intra abdominal pressure pushes the foreign body towards the thorax [24].

The pericardium may be pierced at one or more places and in few cases; the object may either pierce the myocardium or may come out through the thoracic wall. In the later cases an abscess usually forms on either side of the chest, just behind the elbow. In few cases, the object may fall back in to the reticulum and rarely may come out with feces or may get disintegrated [24]. Physical penetration of the pericardial sac is not essential to the development of pericarditis, infection sometimes be penetrating through the pericardium from a traumatic mediastinitis [10].

Formation of adhesion between the epicardium and pericardium and fluid accumulation in the pericardial sac impairs the ability of the heart to act as a pump (pericardial tamponade). At this stage the animal exhibits sign of congestive heart failure [24], as a result of toxemia due to infection and the pressure on the heart from the fluid which accumulates in the sac [10].

**Clinical Signs:** Generally there is a history of complete anorexia, drop in milk yield and reluctance to walk. The animal walks with short steps and stiff gait, pyrexia, increased pulse rate, abdominal respiration, arched back, abducted elbows, grunting while walking and brisket edema are other clinical signs visible in advanced cases, indicating congestive heart failure (Fig 3). The jugular veins are engorged. When digital pressure is applied in the jugular furrow to occlude the vein, the vessel may be seen filling from the cardiac end [1].

Table 1: Sites for surgical approach to the thoracic cavity in bovines (Source:[24].

Procedure	Site
Thoracocentesis	5 <sup>th</sup> to 7 <sup>th</sup> intercostal space
Pericardiocentesis	5 <sup>th</sup> intercostals space or 5 <sup>th</sup> rib
Pericardiotomy/Pericardiectomy	5 <sup>th</sup> rib
Diaphragmatic herniorrhaphy	6 <sup>th</sup> rib to 7 <sup>th</sup> rib
Diaphragmatic abscess	7 <sup>th</sup> rib
Transthoracic Esophagotomy	8 <sup>th</sup> rib
Pneumonectomy	5 <sup>th</sup> rib

In initial stages, pericardial friction sounds are heard on auscultation as the inflamed parietal and visceral layers of the pericardium rub each other due to minimal fluid and increased fibrin in the pericardial sac. Sounds may become faint or muffled later on due to accumulation of more fluid in the pericardium [10].

**Diagnosis:** Diagnosis of traumatic pericarditis is mainly based on clinical signs, pericardiocentesis and radiological observations [1]. Pericardiocentesis through the fifth or sixth intercostal space shows offensive odor fluid in cases of suppurative pericarditis [28].

**Treatment:** Treatment of TP can be conservative or surgical. Conservative treatment includes administration of diuretics to reduce edema, although of limited value and appropriate antimicrobial therapy [24]. The surgical treatment consists of pericardiocentesis, pericardiotomy, or pericardiectomy with or without pericardial graft.

**Pericardiocentesis:** Pericardiocentesis is draining of fluid from the pericardial sac using long, large bore hypodermic needle. The main objectives of pericardiocentesis are to drain fluid from the pericardial sac and to inject antibiotics and proteolytic enzymes. Pericardiocentesis is best done in the standing animal with the forelimb drawn forward. After local infiltration anesthesia, a large bore needle is inserted between 4<sup>th</sup> or 5<sup>th</sup> right intercostals space above the external vein to a depth of 6cm which will drain out the pericardial effusions (Table 1) [28].

**Pericardiotomy:** Pericardiotomy involves incising the pericardium and drainage the fluid. For pericardiotomy, due care should be given to preoperative preparations. A laparo-rumenotomy must be done before pericardiotomy. Foreign bodies present in the reticulum or penetrating the diaphragm or the pericardium with an end in the reticulum should be removed [28]. Since, most candidates for pericardiotomy are poor anesthetic risks, the surgery is

generally performed with the animal under local anesthesia [27].

Prior to casting, a large area over the left thorax and elbow region is clipped, shaved and aseptically prepared. The surgery is performed with the animal placed in right lateral recumbency[23].

The skin incision extends from the costochondral junction to a point 20cm dorsally on a line over the 5<sup>th</sup> rib. The latissimusdorsi and serratusventralis muscle are incised to expose the rib. The periosteum is incised and reflected from the rib. Following exposure of 12to14cm of the fifth rib, a wire saw (Gigli or obstetric) is inserted under the rib with forceps and positioned at the dorsal commissure of the incision. The rib is transected dorsally and then grasped and broken at the costochondral junction. This portion of the rib is discarded. Some surgeons prefer to let the patient stand at this point in the operation before the parietal pleura is opened, to assist drainage. If the animal is restrained on a tilt table, it can be positioned at a steeper angle to aid drainage of the exudates. The incision is then continued through the exposed periosteum and parietal pleura for about 12cm. using a pair of blunt-tipped scissors [29].

The initial opening of the pleura should be small because a sudden influx of air may cause respiratory distress. Usually however, the pericardium is adherent to the parietal pleura and pneumothorax does not occur. To avoid opening the pleural cavity, some surgeons suture the periosteum, the parietal pleura and the pericardium together using number 3 chromic cat gut in a simple continuous patten prior to opening the pleura. If the pericardium is not adherent to the parietal pleura, or if suturing is not performed, leakage of pus in to the pleural cavity will result in contamination and pleuritis. An incision is then made between the suture lines. Once the pericardium is visible, it is opened sufficiently to allow the introduction of the surgical hand. A variable amount of pus will escape from the incision. Suction, if available, should be used to aid evacuation of the exudates. The pericardial sac should be explored for a foreign body and if present, it should be removed [23] and the cavity is thoroughly irrigated with warm sterile isotonic saline solution containing antibiotics [24].

Afterwards, the pericardial and pleural incisions are closed with continuous sutures using absorbable suture material [24]. Closure consists of simple continuous of number 2 or 3 chromic cat gut. The parietal pleura, adherent pericardium and deep periosteal layer are included in the first row and non absorbable suture material is used for the skin closure [23].

Some clinicians prefer pericardiotomy without suturing the pericardial wound but with provision for thoracic drainage where as others prefer to keeps a drainage tube inside the pericardial sac to prevent recurrence of the disease by daily flushing with mild antiseptic solution containing proteolytic enzyme [24].

If the wound is left open, the combined edges of the periosteum, parietal pleura and pericardium are everted and are sutured to the sub cutaneous tissue, to create a pericardial fistula [23].

**Pericardiectomy:** Pericardiectomy is the surgical removal of the pericardium. It is indicated in constrictive pericarditis in which the mediastinal adhesions are thick and the rigid pericardium and epicardium interfere with the cardiac filling and leads to congestive heart failure. Usually partial pericardiectomy is done to free the ventricular compression so as to prevent pulmonary and passive venous congestion. However, this technique is very rarely used in clinical situations [30].

Post operative antibiotics are administered [23] and continued for several days until there is no discharge from the pericardial sac [24]. If drains have been placed in the wound, they are flushed daily with a mixed antibiotic-isotonic solution [23].

**Miscellaneous Diseases Caused by Metallic Foreign Bodies:** In both cattle and buffaloes, sequelae to potential foreign bodies may include traumatic sternabrae, pyothorax, abscessation of spleen and liver, traumatic pneumonia and pleurisy. Rarely, a foreign body may get lodged in to the omasal orifice or the intestine [24] and in many cases a foreign body penetrates lateral or ventral abdominal wall to form an abscess [8].

Traumatic splenitis and hepatitis occur relatively uncommonly as sequelae to TRP and manifested either by continuation of the illness caused by the initial perforation or by apparent recovery followed by relapse several weeks later [10].

Animals may also possess one or more encapsulated abscesses in the liver containing inspissated pus, quite frequently with a wire or nail embedded in the interior of each abscess. The lung may contain one or more similar encapsulated abscesses, each of which contained a short piece of balling wire [2].

In all probability, a cow exhibiting all these lesions may die due to some other conditions in no way connected with traumatic reticulitis [2] and [10].

**Prevention:** There are basically two ways to prevent hardware disease. One is to limit animals' access to small metallic objects. The biggest culprit is often fencing supplies such as wires or nails dropped on the ground. The second way is to place rumen magnets in all your animals. A rumen magnet is like a very large pill that animal is forced to swallow with a pill gun. The magnet stays in the cow's rumen for the life of the animal and traps any metal the animal may swallow. This is most effective if done to the entire herd before the age of one. In smaller operations, some farmers pass metal detectors or magnets over the feed [31].

Prevention of hardware disease in cattle revolves around managing animal feed and animal areas to avoid ingestion of heavy sharp foreign objects. Magnets are typically installed in feed milles and forage harvesting equipment. [10]. Metal that is ingested will find its way to the magnet and prevented from working its way through the stomach wall. The magnet simply keeps foreign metallic objects adhered together in a ball, reducing the chance of penetrating the reticulum. Of course, the best preventive measure is keeping feed bunks, pastures, cowlots, etc free of potentially hazardous objects [32].

Prevention consists of external vigilance in picking up all pieces of wire, nails, or other metals that might get in to the feed. Most feed companies pass feed over a magnet in order to remove any pieces of metal and some farm mills have a magnet build in to chute [32].

Eliminating source of sharp foreign objects in the feed supply prevents TRP. Installation of large magnets on feed handling equipments and prophylactic administration of the fore stomach magnets to all animals prevent almost all cases caused by magnetizable object [21]. These are used to prevent the diseases but are also used in acute cases to minimize penetration of the foreign body [33].

There is good evidence that giving magnets to all herd replacement heifers and bulls at one year of age minimize incidence of TRP. The incidence of this condition has been significantly reduced by the increased use of twine rather than wire to bind bales of hay [11]. Keeping cattle away from sites of new construction and completely removing old buildings and fences are preventive measures [1].

## CONCLUSION AND RECOMMENDATIONS

Hardware disease is more common in animals having nutritional deficiencies. Cattle acquire hardware disease

most commonly when they feed green chop, silage and hay which are collected from fields that contain old rusting fence or balling wire, or when pastures are on areas or sites where buildings have recently been constructed, burned, or torn down. Once cattle contract the metallic foreign bodies, it causes several pathological diseases such as traumatic stomatitis, pharyngitis, esophagitis and esophageal obstruction, rumenitis, reticulitis, TRP, vagal indigestion, diaphragmatic hernia, TP, splenic, liver and pleumony abscesses. High mortality and reduced production in dairy cows is another consequence of hardware disease. Placing reticular magnets have dual function: in prevention and treatment of hardware disease. Specialized and trained surgeons in the presence of good facilities are responsible for saving of animals that are affected by hardware diseases. Based on these conclusive remarks, the following recommendations can be forwarded:

- Animal owners should be educated about hard ware diseases
- Animal owners should include adequate minerals and vitamins in animals feed
- Animals have to be reared and /or grazed away from areas of building construction
- Owners should use magnets to screen for metallic foreign bodies in animals feed
- Owners may be encouraged to put magnet pills into the rumen to all heifers and young bulls.
- Veterinarians should be trained to diagnose, treat and do surgical interventions for hardware diseases

#### REFERENCES

1. Kahn, M.C., 2005. The Merck Veterinary Manual. 8<sup>th</sup>ed, Merck and Co., INC. White house station, USA, pp: 98: 185-192.
2. Shuttleworth, A.C. and R.H. Smyth, 2000. Clinical Veterinary Surgery. Volume 2, Green World Publishers, pp: 179-203.
3. Jennings, P.B., 1984. The Practice of Large Animal Surgery. Volume 1, USA, Saunders Company, pp: 498-523.
4. Cavado, A.M., K.S. Latimer, H.L. Tarply and P.J. Bain, 2004. Veterinary Clinical Pathology Clerkship Program. University of Georgia, College of Veterinary Medicine, Department of Pathology, Greek, Athens, pp: 306-318.
5. Bath, D.L., F.N. Dickinson, H.A. Tucker and R.D. Appleman, 1985. Dairy cattle principle, practice problems and profit. 3<sup>rd</sup> ed. Philadelphia: Lea and Febiger, pp: 349-350.
6. Moseley, B.L., 1993. Hardware Disease of Cattle. University of Missouri Extension, College of Veterinary Medicine, Columbia, pp: 12-15.
7. Rajendran, N., 2014. Professor of veterinary surgery. Gondar University, Personal communication.
8. Fubini, S.L. and N.G. Ducharme, 2004. Farm Animal Surgery. 1<sup>st</sup> ed. USA: Elsevier, pp: 156: 189-195.
9. Howard, J.L., 1986. Current Veterinary Therapy. 3<sup>rd</sup> ed. London: W, pp: 712-722.
10. Radostits, O.M., C.C. Gay, K.W. Hinchcliff and P.O. Constable, 2007. Veterinary Medicine, a text book of the diseases of Cattle, Horses, Sheep, Pigs and Goats. 10<sup>th</sup>ed, Elsevier Limited, pp: 337-352.
11. Jones, T.C., R.D. Hunt and N.W. King, 1997. Veterinary pathology. 6<sup>th</sup> ed. USA, pp: 1060-1062.
12. Hailat, N., S. South, A. Al-Darraj and A. Al Majali, 1996. Prevalence and pathology of foreign bodies in Awassi sheep. Jordan Small Ruminant Research, 24: 43-48.
13. Schipper, I.A., 2000. Lecture out line of preventive veterinary medicine. 6<sup>th</sup> ed. Surgeetpublishing, pp: 166-167.
14. Misk, N.A., J.M. Nigam and J.F. Rifati, 1984. Management of foreign body syndrome in Iraqi cattle. Agripractice, 5: 19-21.
15. Ramaswamy, V. and H. Rai Sharma, 2011. Plastic Bags-Threat to Environment and Cattle Health: A Retrospective Study from Gondar City of Ethiopia. The IIOAB Journal, 2: 7-11.
16. Spaulding, C.E. and J. Clay, 2013. Veterinary Guide for Animal Owners. Hardware Disease in Cattle, causes and Treatments. [http:// www.critters360.com/index.php/hardware-disease-in-cattle-causes-and-treatments-18331/](http://www.critters360.com/index.php/hardware-disease-in-cattle-causes-and-treatments-18331/) (Accessed on: 20 June 1993 at 04:30).
17. Ducharme, N.G., 2004. Surgery of bovine digestive system. In: Fubini, S.L. and Ducharme, N.G. (eds.): Farm Animal Surgery. 1<sup>st</sup> ed. USA: Elsevier, Pp.161-190.
18. Ramaswamy, V., 2014. Professor of veterinary surgery. Gondar University, personal communication.
19. Singh, J., A.P. Singh and D.B. Patil, 1993. The digestive system of ruminants. In: Tyagi, R.P.S. and Singh, J. (eds.): Ruminant Surgery. 1<sup>st</sup>ed. New Delhi: CBS Publishers and Distributers, pp: 200-202.

20. O'Connor, J.J., 2005. *Veterinary Surgery*. 4<sup>th</sup> ed. London: CBS Publishers and Distributers, pp: 573: 681-686.
21. Simth, B.P., 2009. *Large animal internal medicine*. 4<sup>th</sup> ed. USA. Mosby Elsevier, pp: 849-852.
22. Gondar university veterinary clinic. Clinical presentation of a cow having abscessation behind the elbow, 2014.
23. Turner, A.S. and C.W. McIlwraith, 1989. *Techniques in Large Animal Surgery*. 2<sup>nd</sup> ed. London: Lea and Febiger, pp: 268-271: 345-349.
24. Tyagi, R.P.S. and J. Singh, 2013. *Ruminant Surgery, a text book of Surgical Diseases of Cattle, Buffaloes, Camels, Sheep and Goats*. 12<sup>th</sup>ed. New Delhi: CBS Publishers and Distributers, pp: 187-202: 230-236.
25. Venugopalan, A., 2000. *Essentials of Veterinary Surgery*. 8<sup>th</sup>ed. New Delhi: Oxford and IBH Publishing co., pp: 485-486.
26. Andrews, A.H., R.W. Blowey, H. Boyd and R.G. Eddy, 2004. *Bovine Medicine, Disease and Husbandry of Cattle*. 2<sup>nd</sup> ed. USA: Black well Science, pp: 837-839.
27. Gaughan, M., J. Provo-Klimek and N.G. Duchrame, 2004. *Surgery of bovine respiratory and cardiovascular system*. In: Fubini, S.L. and Ducharme, N.G. (eds.): *Farm Animal Surgery*. 1<sup>st</sup> ed. USA: Elsevier, pp: 141-158.
28. Krishnamurthy, D., 2008. *The respiratory and cardiovascular system of ruminants*. In: Tyagi, R.P.S. and Singh, J. (eds.): *Ruminant Surgery*. 1<sup>st</sup>ed. New Delhi: CBS Publishers and Distributers, pp: 183-197.
29. Knecht, C.D., A.R. Allen, D.J. Williams and D.H. Johnson, 1987. *Fundamental techniques in Veterinary surgery*. 3<sup>rd</sup>ed. London: W.B. Saunders Company, pp: 310-312.
30. Ramakrishna, O., 2008. *Bovine cardiovascular system*. In: Tyagi, R.P.S. and Singh, J. (eds.): *Ruminant Surgery*. 1<sup>st</sup>ed. New Delhi: CBS Publishers and Distributers, pp: 255-259.
31. Rebhun, W.C., 1995. *Diseases of Dairy Cattle*. 1<sup>st</sup> ed. Philadelphia: Williams and Wilkins Publisher, pp: 113-116.
32. Etgen, W.M. and M. Reaves, 1978. *Dairy Cattle Feeding and Management*. 6<sup>th</sup> ed. Virginia: Jon Wiley and Son, pp: 305-306.
33. Wikipedia, 2014. *Diseases of the ruminants. Hardware disease*. Retrieved from: [http:// en.wikipedia.org/ w/ index.php?title=Hardware\\_disease&oldid=604408210](http://en.wikipedia.org/w/index.php?title=Hardware_disease&oldid=604408210)(Accessed on: 16 April 2014 at 05:50).