

Prevalence of Anaemia in Decompensated Chronic Liver Disease

E. Halleys Kumar and A. Radhakrishnan

Sree Balaji Medical College And Hospital, No 7,
Clc Works Road, Chromepet, Chennai- 600044, Tamilnadu, India

Abstract: Aim of the study: To assess the prevalence of anaemia in decompensated chronic liver disease patients. Objectives: 1) To detect the abnormalities of rbc's in a cirrhotic patient. 2) To find the type of anaemia in a patient with decompensated chronic liver disease. Materials and methods: 1) To assess the prevalence of anaemia in decompensated chronic liver disease. The study was conducted in Sree Balaji Medical College and Hospital from 2011 to 2013. 2) About 100 patients were selected in random from patients coming to department of general medicine OPD and ward patients. **CONCLUSION** The study revealed 86 percent had anaemia helping in early diagnosis of anaemia in decompensated chronic liver disease patients and could play a role in treatment of patients earlier and prevent morbidity and mortality

Key words: Anaemia • Decompensated chronic liver disease

INTRODUCTION

Liver is the largest organ of the body, weighing 1-1.5kg and representing 1.5-2.5 percentage of the lean body mass. The liver is located in the right upper quadrant of the abdomen under the right lower rib cage against the diaphragm and projects for a variable extent into the left upper quadrant.

The liver is held in place by ligamentous attachments to the diaphragm, peritoneal, great vessels and upper gastrointestinal organs. It receives a dual blood supply 20 percent of the blood flow is oxygen rich blood from hepatic artery and 80 percent is nutrient rich blood from portal vein arising from the stomach, intestines, pancreas and spleen.

The majority of cells in the liver are hepatocytes, which constitute $2/3^{\text{rd}}$ of the mass of the liver. Remaining cell types are Kupffer cells, stellate cells, endothelial cells and blood vessels, bile ductular cells and supporting structures.

Liver performs numerous and vital roles in maintaining homeostasis and health. It plays a major role in carbohydrate, lipid and protein metabolism.

Liver is the major storage site for iron, vit B12 and folic acid. The liver is involved in or is responsible for

various hematological abnormalities due to its unique portal circulation and its synthetic (clotting factors, thrombopoietin) and immune functions. Primary liver problems like cirrhosis can lead to hematological abnormalities and primary hematological diseases can in turn affect the liver and its functioning.

Cirrhosis is a condition that is defined histopathologically and has a variety of clinical manifestations and complications, some of which can be life threatening. Liver fibrosis is characterized by the accumulation of extracellular matrix, resulting from its increased production and decreased degradation and leading to distorted reconstruction of the liver parenchyma that accompanies liver function impairment during most chronic liver disease [1]. Abnormalities in hematological indices are frequently encountered in cirrhosis. Multiple causes contribute to the occurrence of hematological abnormalities. Recent studies suggest that the presence of hematological cytopenias is associated with a poor prognosis in cirrhosis. Anaemia is the most common health problem in the world [2].

The study was conducted to assess the prevalence of anaemia and nature of rbc's, so that treatment can be initiated towards reducing the morbidity and mortality.

MATERIALS AND METHODS

Study Population:

- To assess the prevalence of anaemia in decompensated chronic liver disease, the prevalence study was conducted in Sree Balaji Medical College and Hospital from 2011 to 2013.
- About hundred patients were selected in random for this study, from patients coming to department of general medicine OPD and ward patients.

Inclusion Criteria:

- All liver disease patients whose symptoms and signs persist more than six months.
- Alcoholic, post-infective, metabolic causes of liver diseases are taken in consideration.

Exclusion Criteria:

- Patients with known primary hepatocellular carcinoma or GI malignancies.
- Acute liver cell failure.

Description of Study:

- Blood investigations such as complete blood count, liver function test, UGI scopy and ultrasound abdomen were done for all the patients. Once the patients were confirmed as a case of decompensated chronic liver disease then the patients were said to undergo other tests such as Rbc, Hb, reticulocyte count and peripheral smear to find the type of anaemia.
- Oral and written consent of the patients got for the clinical examination and for the lab investigations.
- A detailed history was taken such as abdominal pain, abdominal distension, decreased urine output, yellowish discoloration of urine and eyes, loss of appetite, loss of weight, early satiety and fever.

Ultrasonography: Abdominal ultrasonography with Doppler is a noninvasive, widely available modality that provides valuable information regarding the gross appearance of the liver and blood flow in the portal and hepatic veins in patients suspected to have cirrhosis.

Ultrasonography should be the first radiographic study performed in the evaluation of cirrhosis because it is the least expensive and does not pose a radiation

exposure risk or involve intravenous contrast with the potential for nephrotoxicity as does computed tomography (CT).

Nodularity, irregularity, increased echogenicity and atrophy are ultrasonographic hallmarks of cirrhosis.

In advanced disease, the gross liver appears small and multinodular, ascites may be detected and Doppler flow can be significantly decreased in the portal circulation.

RBC Count: RBC count was done in Neubauer's chamber using Hayem's fluid or auto analyser. Normal value: 4.5 to 5.5 million per cu mm.

Hemoglobin Estimation: Done by Sahli's method, based on the conversion of hemoglobin to acid hematin or acid analyser. Normal values: male 14 to 18 gm/dl female 12 to 16 gm/dl

Peripheral Smear for Blood Picture:

- Low power field examination
- High power field examination
- Oil immersion examination

RESULTS

Table 1 shows hemoglobin abnormalities in decompensated chronic liver disease patients.

(70 males and 30 females).

- In this study we found that 10 males (14.3 percent), 6 (20 percent) of the patients had severe anemia.
- 30 males (42.9 percent), 12 females (40.0 percent) had moderate anemia and 20 males (28.6 percent), 8 females (26.7 percent) had mild anemia.
- About 10 males and 4 females had normal hemoglobin levels. iv) female patients had a greater proportion of severe anemia in other studies contrary to our study in which male patients have severe anemia compared to females.
- Female patients had a greater proportion of severe anemia in other studies contrary to our study in which male patients have severe anemia compared to females.

TABLE 2 showing type of anemia more prevalent in decompensated chronic liver disease patients.

(70 males and 30 females)

Table 1: Hemoglobin (Anaemia In Chronic Liver Disease Patients)

Hemoglobin (gm/dl)	Gender					
	Male		Female		Total	
	N	%	N	%	N	%
SEVERE (<6gm/dl)	10	14.3	6	20.0	16	16.0
MODERATE (6 TO 8.9/dl)	30	42.9	12	40.0	42	42.0
MILD (9 TO 12.9gm/dl)	20	28.6	8	26.7	28	28.0
NORMAL	10	14.3	4	13.3	14	14.0
Total	70	100.0	30	100.0	100	100.0

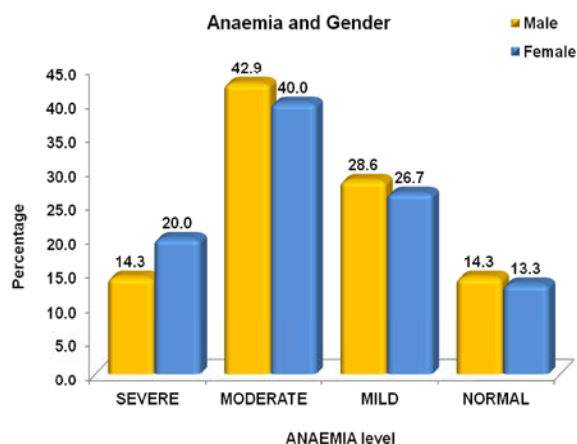
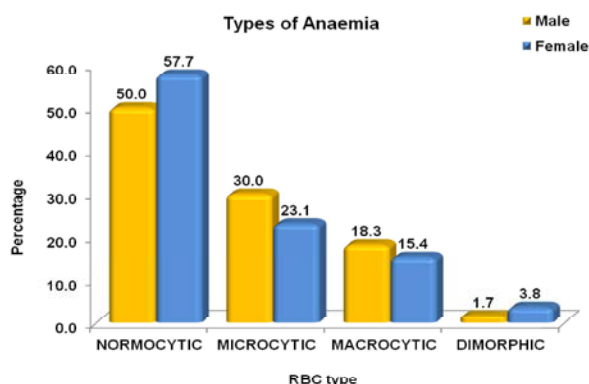


Table 2: Type Of Anaemia In Chronic Liver Disease Patients

Type of Rbcs	Patients with Anaemia					
	Male		Female		Total	
	N	%	N	%	N	%
NORMOCYTIC	30	50.0	15	57.7	45	16.0
MICROCYTIC	18	30.0	6	23.1	24	42.0
MACROCYTIC	11	18.3	4	15.4	15	28.0
DIMORPHIC	1	1.7	1	3.8	2	14.0
Total	60	100.0	26	100.0	86	100.0



- In my study, normocytic normochromic anaemia is more prevalent than other type of anaemias, about 30 males (50 percent) and 15 females (57.7 percent) had normocytic normochromic anaemia.

- Which is followed by microcytic hypochromic and macrocytic.
- Microcytic hypochromic anaemia is more prevalent in men than women.
- Macrocytic anaemia is more common among alcoholics.
- About 18 males (30 percent) and 6 females (23 percent) had microcytic hypochromic anaemia.
- About 11 males (18.3 percent) and 4 females (15.4 percent) had macrocytic anaemia. All 11 males gave history of alcoholism.
- 1 male (1.7 percent) and 1 female (3.8 percent) had dimorphic anaemia.
- About 10 males and 4 females had normal hemoglobin level (14 patients).

DISCUSSION

Anaemia in Cirrhosis:

Anaemia in Cirrhosis Is Mostly Due To:

- Hemodilution
- Decreased erythropoietin level as per study sicilianohepatol 1995 who showed decreased erythropoietin level in cirrhotic patients with anaemia.
- Cirrhosis without anaemia is not associated with low erythropoietin levels (pirsi,jhepatol 1994)
- Where as Yang *et al* [3] investigated the significance of erythropoietin in 67 patients with varying severity of cirrhosis and reported that plasma erythropoietin levels were significantly higher in cirrhotic patients than in controls. They also found levels to be higher in patients with anemia.
- Inflammatory cytokines suppressing the bone marrow (chronic inflammation)
- Folic acid and vitamin B12 deficiencies and iron deficiency develop frequently in patients with cirrhosis producing severe anaemia.
- Spur cell anaemia - seen in advanced chronic liver disease especially in alcoholics and has a poor prognosis. It is related to abnormal cholesterol loading of the red cell membrane and reduced deformability of the red cells. In the presence of hyperlipidemia, it is referred to as Zieve's syndrome.[4]
- Wilson's disease may be associated with a hemolytic anaemia in 1-12%. Hepatic necrosis leads to release of copper, which in turn has an oxidative action on RBC cell membrane phospholipids leading to their breakdown. These patients typically present as fulminant hepatic failure with hemolysis [5].

- Ribavirin-induced hemolytic anaemia Ribavirin is used for treatment of hepatitis C along with interferon or pegylated interferon. It can cause significant dose-dependent hemolytic anaemia in about 10% of patients on interferon and ribavirin therapy [6]. There are clear recommendations on dose reduction depending on the fall in haemoglobin. Alternatively, erythropoietin growth factor up to a dose of 40,000 units s.c. weekly can be given. Newer growth factors with longer half-lives such as darbopoietin and pegylated erythropoietin are convenient for the lesser number of doses required. CERA (continuous erythropoietin receptor activator), a pegylated erythropoietin is one such agent with once monthly dosing [7].

Characteristics of Anaemia: Anemia of diverse etiology occurs in about 75% of patients with chronic liver disease[8]

- According to sheilasherlock and oxford text book of hepatology. most common anaemia seen in cirrhotic patients is normochromic and normocytic anaemia[9,10]
- According to study done by malhotra,1951 incidence was 90 percentage.in studies done by bhatia(1961)and mishra *et al* (1982), incidence were 59 and 79 percentage respectively.
- In study done by kimber *et al* reported 43 percent of macrocytosis supported by bingham *et al*.
- Macrocytic Anemia in an alcoholic arise as a consequence of the direct toxic effects of alcohol on erythrocyte precursors in the bone marrow.
- Folic acid and vitamin B12 deficiencies develop frequently in patients with cirrhosis. These deficiencies may be related to inadequate food intake or intestinal malabsorption. They are suspected when examination of a blood film reveals hypersegmented cells and oval macrocytes, in addition to round macrocytes characteristic of chronic liver disease. When anemia is caused by these deficiencies, the mean corpuscular volume is increased and bone marrow shows megaloblastic erythropoiesis.
- Consumption of alcohol appears to be associated with an approximately 40% reduction in the risk of development of iron deficiency anemia.
- Acute gastrointestinal hemorrhage is a common and potentially serious complication of portal hypertension[11-14].Acute hemorrhage may induce severe hypovolemia and subsequently secondary iron deficiency anemia.

- Esophageal and gastric varices and/or portal hypertensive gastropathy may be associated with slow chronic loss of blood into the gut and development of chronic iron deficiency anemia.The most important approach to management is prevention of variceal hemorrhage [11,13,14].
- serum iron is bound to beta globulin transferrin and total iron bindingcapacity largely depends on transferrin concentration.
- TIBC is often low.

Abnormalities of rbc's:

- Target cells are particularly prominent in cholestasis where a rise in bile acids may contribute LCAT activity [15].
- It is seen in 2 percentage of the patients in our study.
- Acanthocytosis or spur cells can refer generally to the presence of this type of crenated red blood cells, may be found in severe cirrhosis or pancreatitis[16], they are a bad prognostic indicator.these abnormal rbc's are not found in our study.

CONCLUSION

- 86 percentage of patients had anaemia in some forms.
- Normocytic normochromic anaemia is most common type of anaemia present in our study in patients having cirrhosis.
- Microcytic anaemia is more common in men than women in my study.
- Macrocytic anaemia patients gave history of alcoholism.
- 2% of target cells are found in my study.
- In my study 86 percent had anaemia, which indicates that earlier diagnosis of hematological abnormalities in decompensated chronic liver disease patients would help us to treat patients earlier and prevent morbidity and mortality.

REFERENCES

1. Middle-East Journal of Scientific Research 7(6):1001-1007,2011 ISSN 1990-9233 ©idosi publications, 2011.
2. Middle-East Journal of Scientific Research 14 (4): 461-470, 2013 ISSN 1990-9233, © IDOSI Publications, 2013 DOI: 10.5829/idosi.mejsr.2013.14.4.7321.
3. Yang, Y.Y., H.C. Lin, W.C. Lee Wc, Huang, Y.T. Hou, M.C. Lee, F.Y. Chang and F.Y. Lee Sd, 2003. Plasma erythropoietin level in patients with cirrhosis and its relationship to the severity of cirrhosis and renal function. J. Gastroenterol. Hepatol., 18: 1156-61.

4. Zieve L. Jaundice, 1958. Hyperlipidemia and hemolytic anaemia: a heretofore unrecognized syndrome associated with alcoholic liver cirrhosis. *Ann. Intern Med.*, 48: 471-96.
5. Roberts, E.A. and M.L.Schilsky, 2003. American Association for Study of Liver Diseases (AASLD). Practice guidelines on Wilson disease. *Hepatology*, 37: 1475-92.
6. Manns, M.P., J.G. McHutchison, S.C. Gordon, V.K. Rustgi, M. Shiffman and R. Reindollar, Good Man Zd, Koury K, Ling M, Albrecht Jk. 2001. Peginterferon alfa-2b plus ribavirin compared with interferon alfa-2b plus ribavirin for initial treatment of chronic hepatitis C: a randomised trial. *Lancet*. 358: 958-65.
7. Macdougall, I.C., CERA (Continuous Erythropoietin Receptor Activator), 2005. A new erythropoiesis-stimulating agent for the treatment of anemia. *Curr. Hematol. Rep.*, 4: 436-40.
8. McHutchison, J.G., M.P. Mannsand and D.L. Longo, 2006. Definition and management of anemia in patients infected with hepatitis C virus. *Liver Int.*, 26: 389-398.
9. Schmidt, Sca J. *Hematol*, 1983. 30: 465
10. Rubiee, *Cry Med*, 1977. 40: 338.
11. Garcia-Pagan, J.C., A. De Gottardiand J.Bosch,2008. Review article: the modern management of portal hypertension--primary and secondary prophylaxis of variceal bleeding in cirrhotic patients. *Aliment Pharmacol Ther.*, 28: 178-186 [PubMed].
12. Abraldes, J.G. and J. Bosch, 2007. The treatment of acute variceal bleeding. *J. Clin Gastroenterol.*, 41(Suppl 3): S312-S317 [PubMed].
13. Kravetz, D., 2007. Prevention of recurrent esophageal variceal hemorrhage: review and current recommendations. *J. Clin Gastroenterol.*, 41(Suppl 3): S318-S322 [PubMed].
14. Albillos, A., 2007. Preventing first variceal hemorrhage in cirrhosis. *J. Clin Gastroenterol.*, 41(Suppl 3): S305-S311 [PubMed].
15. Carr, J.M., 1989. Disseminated intravascular coagulation in cirrhosis. *Hepatology*, 10: 103-10.
16. ^a b Hillman, R.S.K.A. Ault, M. Leporrier and H.M. Rinder, 2011. *Hematology in Clinical Practice*.