

## Hepatoprotective Effect of Soapworts (*Saponaria officinalis*), Pomegranate Peel (*Punica granatum L*) and Cloves (*Syzygium aromaticum linn*) on Mice with CCl<sub>4</sub> Hepatic Intoxication

Manal K Abdel-Rahman and Ashraf A. Abd El-Megeid

Department of Nutrition and Food Science, Faculty of Home Economics,  
65 Elmatbaea El-Ahlia St., Boulak, P.O. Box 11611, Cairo, Egypt

**Abstract:** Soapworts, pomegranate peel and cloves are widely used in Egypt as a herbal medicine. However, their action as hepatoprotective agents still remains to be elucidated. To clarify its effect on liver functions, Eight-week-old male mice were injected with carbon tetrachloride (CCl<sub>4</sub>) at the single dose of 0.5 ml/kg body weight intraperitoneally for 30 days, 3 groups of mice were fed on herbal diets and the remaining groups were negative and positive control. The hepatoprotective effect of herbs was evaluated by measuring levels of serum marker enzymes such as alkaline phosphatase (ALP), alanine aminotransferase (ALT), aspartate aminotransferase (AST), albumin and bilirubin levels in mice serum. The histological studies were also carried out to support the above parameters. The study found that the supplementation of soapworts and pomegranate peel significantly ( $p < 0.05$ ) reduced the damaging effects on the liver by CCl<sub>4</sub>. Albumin levels declined in positive control diet group due to the hepatic damage induced and levels were found to be enhanced following treatment with soapworts, pomegranate peel and cloves consecutively. A comparative histopathological study of the liver exhibit between different groups showed that in particular the soapworts and pomegranate peel led to normal liver architecture suggesting they may act as hepatoprotective food supplements. Meanwhile cloves ameliorated the histopathological alteration of liver structure.

**Key words:** Liver % carbon tetrachloride % soapwort % pomegranate peel % cloves % liver function tests

### INTRODUCTION

The liver is the main organ responsible for multitude of essential functions and plays an essential role in the metabolism of foreign compounds entering the body. Human beings are exposed to these compounds through environmental exposure, consumption of contaminated food or during exposure to chemical substances in the occupational environment. All these compounds produce a variety of toxic manifestations [1]. In Egypt, liver diseases are one of the most prominent killers specifically hepatitis C virus (HCV) and cirrhosis that alter the metabolism of the liver [2]. Conventional drugs used in the treatment of liver diseases are often inadequate. It is therefore necessary to search for alternative drugs for the treatment of liver diseases to replace the currently used drugs of doubtful efficacy and safety. The enzymes L-alanine aminotransferase (L-ALT), L-aspartate amino transferase (L-AST), alkaline phosphatase (ALP) and

lactate dehydrogenase (LDH), are often used in assessing the integrity of the liver [3].

Administration of carbon tetrachloride (CCl<sub>4</sub>) to rodents is a widely used model to study mechanisms of hepatic injury. CCl<sub>4</sub> causes hepatocyte injury that is characterized by centrilobular necrosis followed by hepatic fibrosis.

Liver fibrosis occurs as a result of a variety of pathological factors, including viral hepatitis (especially hepatitis B and C), alcohol and drug abuse, metabolic diseases due to overload of iron or copper, autoimmunity against hepatocytes or bile duct epithelium and congenital abnormalities [4].

Herbs have recently attracted attention as health beneficial foods and as source materials for drug

development. Herbal medicines derived from plant extracts are being increasingly utilized to treat a wide variety of clinical conditions including liver diseases [5], ischemia, reperfusion injury, atherosclerosis, acute

hypertension, haemorrhagic shock, diabetes mellitus and cancer [6] with relatively little knowledge regarding their modes of action [7].

Soapwort (*Saponaria Officinalis*) contains saponins, a soap like substance. Soapwort is tonic, diaphoretic and alterative; and forms a remedy in the treatment of syphilitic, scrofulous and cutaneous diseases, also in jaundice, liver infections, rheumatism and gonorrhoea.

A widespread root for "pomegranate" comes from the Ancient Egyptian *rmn*, from which derive the Hebrew *rimmôn* and Arabic *rummân*. Pomegranate is a small tree, belonging to the Punicaceae family. Pomegranate juice has become increasingly popular because of the attribution to them of important biological actions [8,9] including cardiovascular protection [10]. Pomegranate juice has recently been demonstrated to improve lipid profiles in type II diabetic patients with hyperlipidemia [11]. Despite the popularity of pomegranate juice little research has been carried out on pomegranate peel.

Cloves are dried unopened floral buds of an evergreen tree *Syzygium aromaticum*(*Gaertn*) *Linn*. Belonging to the family Myrtaceae. They are esteemed as flavouring agents and also used as a spice for scenting and chewing tobacco. They are aromatic, stimulant and carminative, used for dyspepsia and gastric irritation [12].

There is paucity of information regarding the effect of soapworts, pomegranate peel and cloves in combating liver damage in mice due  $\text{CCl}_4$ -intoxication.

**Objective:** To evaluate the potential efficacy of soapwort, pomegranate and cloves in protecting liver tissues from damage in  $\text{CCl}_4$ -intoxicated mice.

## MATERIALS AND METHODS

**Plant Material:** The dried plant material of soapworts, pomegranate and cloves of were collected from local Egyptian herbal shops. They were ground into a fine powder with a mechanical grinder before mixing with mice diets. The powdered plant material was then passed through a fine sieve and stored in an airtight container.

**Animals:** Adult male mice (8 weeks old), weighing 35-40g, received humane care in compliance with the guidelines approved by Ophthalmology Institute, Giza, Egypt. They were housed in clean polypropylene cages and were fed with standard diet, Ain 93 diet [13] and were provided with supply of water *ad libitum*. Light and dark alternated at 12 h intervals.

**Inducing Liver Damage and its Markers:** Acute  $\text{CCl}_4$ -induced liver damage, a single dose of 0.5 ml/kg of body weight (2:5 v/v in paraffin oil) was administered by intraperitoneal (IP) injection. Livers were excised for histology. Positive control mice exhibited overt symptoms but no mortality from the single dose of  $\text{CCl}_4$  was recorded.

**Experimental Protocol:** The following experimental protocol was followed for the present investigation. The animals were divided into five groups (n=9).

**Group I:** control mice without treatment and fed on basal diet only (C-).

**Group II:** comprised of hepatically injured mice by  $\text{CCl}_4$  which received basal diet (C+).

**Group III:** comprised of hepatically injured group which received basal diet and 10% grounded cloves (BCD).

**Group IV:** comprised of hepatically injured group which received basal diet and 10% grounded soapworts (BSD).

**Group IIV:** comprised of hepatically injured group which received basal diet and 10% grounded pomegranate peel (BPD).

All diets were administered daily at the same time between 9.00-9.30 a.m. Weight of the animals was recorded weekly for 4 weeks. In groups III, IV and IIV the respective ingredients were mixed with basal diet, made into a pellet and given as lab feed. At the end of the experimental period, the mice were deprived of food overnight and then sacrificed by cervical dislocation followed by decapitation. Blood was collected from the retro orbital venous plexus under  $\text{CO}_2$  anesthesia.

The blood samples were allowed to clot and the serum was separated by centrifugation at  $37^\circ\text{C}$  and used for the assay of biochemical marker enzymes.

**Liver Function Tests:** Liver function was examined after sacrificing the rodents. Blood parameters were used since they were useful to assess liver functions in mice. Serum bilirubin levels were measured by following Oser method [14].

Serum albumin was measured by the bromcrezol green method, using Alb Jisseiken (Jisseiken, Japan).

Serum aspartate aminotransferase (AST) and alanine aminotransferase (ALT) were measured by the ultraviolet spectrometry method, using Quickauto II.

Serum alkaline phosphatase (ALP) was also measured [15]. These were analyzed using a Biochemical Autoanalyzer (AU5232; Olympus, Tokyo, Japan).

**Histology:** The morphology of hepatocellular changes was classified using a scale ranging from 0 to 4 according to severity of histological sections. 0 shows no histopathological changes, 1 shows light degree of severity, 2 mild, 3 moderate and 4 severe histopathological alterations. Two independent investigators performed the histological assessment in a blind manner. The liver sections from the five groups were randomly shown to the investigators. Specimen from liver was fixed in 10% neutral buffered formalin. Sections were routinely prepared for light microscopy with formalin fixation, embedded in paraffin and stained with H&E according to [16].

**Statistics:** Experimental results were expressed as mean±S.D. Analysis of variance was performed by ANOVA procedures (SPSS 9.0 for Windows). Significant differences between means were determined by Dunnett's post hoc test.  $p < 0.05$  implies statistically significance.

## RESULTS

**Body weight:** Due to the acute liver damage, loss of appetite has been observed in mice intoxicated using  $\text{CCl}_4$ . The changes in body weight are shown in Table (1), body weights increased with time except that the body weight in the (C+) had decreased 6% relative to initial weight after 30 days feeding time. Body weights of the soapworts and pomegranate peel mice groups had similar body weights and were greater than the rest of treated groups ( $P < 0.05$ ).

**Markers of Hepatic Injury:** Twelve hours after a single injection of  $\text{CCl}_4$ , liver damage monitored by blood plasma ALT levels in mice which were three times that of positive control groups (data not shown).

Table 1: Mean weight (g) changes in intoxicated mice treated with and without  $\text{CCl}_4$

Group	Initial weight	Final weight	Weight gain (g)	% Weight gain
(C-)	33±2.30	40 ±2.74	7	21.20
(C+)	35 ±2.59	33±2.90	-2	-6.00
(BSD)	35±0.35	40±4.63	5	14.30
(BPD)	33 ±0.55	37±1.23	4	12.10
(BCD)	34 ±0.87	37 ± 4.50	3	8.80

n=9 (values are the mean of 9 results), Mean ± SEM (Standard Error of Mean). (C-) negative control fed on basal diet only. (C+) positive control= mice treated with  $\text{CCl}_4$  and fed on basal diet only. (BSD) mice treated with  $\text{CCl}_4$  and fed on basal diet+10% soapworts. (BPD) mice treated with  $\text{CCl}_4$  and fed on basal diet + 10% pomegranate peel. (BCD) mice treated with  $\text{CCl}_4$  and fed on basal diet+10% cloves.

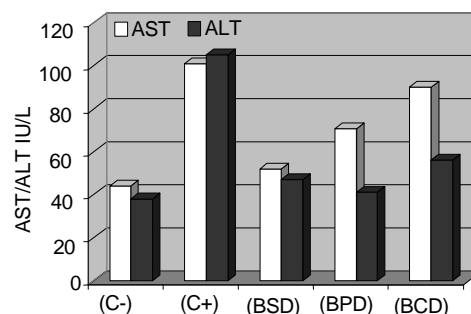


Fig. 1: Effects of soapworts, pomegranate peel and cloves, on liver enzymes of  $\text{CCl}_4$  intoxicated-mice.

**Liver function tests:** Serum bilirubin levels in the (C+), group at 4 weeks were higher than those in other groups ( $P < 0.05$ ) (Table 2). However, little differences were observed between (BSD), (BPD) and (BCD) diet groups, respectively. Serum albumin levels gradually increased in (BSD), (BPD) and (BCD) groups. However, the albumin decreased in the (C+) group compared to the (C-) group. Serum albumin in the (BSD) group was significantly higher ( $P < 0.05$ ) than in other groups.

Serum (AST) in the (BSD) group was significantly lower ( $P < 0.05$ ) than other groups. Changes in serum (ALT) were similar to those of (AST). Serum ALT levels were slightly higher in (BCD), compared with the (BSD) and (BPD) groups. Similarly, alkaline phosphatase (ALP) results have been observed in Table 2.

Table 2: Effect of soapworts, pomegranate peel and cloves, on liver enzymes of  $\text{CCl}_4$  intoxicated-mice

Tests	(C-)	(C+)	(BSD)	(BPD)	(BCD)
Bilirubin (mg/ml)	0.1±0.030	0.18±0.08	0.11±0.05	0.13±0.01	0.15±0.07
Albumin (g/dl)	3.50±0.06	1.82±0.04 <sup>a</sup>	3.01±0.09 <sup>b</sup>	2.50±0.07 <sup>b</sup>	1.98±0.05 <sup>a</sup>
AST (IU/l)	44.00±1.50	101.00±2.30 <sup>a</sup>	52.00±1.60 <sup>b</sup>	70.60±1.30 <sup>ab</sup>	90.00±3.07 <sup>a</sup>
ALT (IU/l)	38.00±1.40	105.00±1.60 <sup>a</sup>	47.00±3.40 <sup>b</sup>	41.00±3.20 <sup>b</sup>	56.00±2.50 <sup>ab</sup>
ALP (IU/l)	189.00±0.90	354.00±0.70 <sup>a</sup>	207.00±0.40 <sup>b</sup>	215.00±0.50 <sup>b</sup>	245.00±0.30 <sup>b</sup>

P values calculated by one way ANOVA followed by Dunnett's post hoc test of significance. \* $p < 0.05$  implies (Each value represents the mean±SEM, (Standard Error of Mean), n=9 in each group) <sup>a</sup> statistically significant compare to (C-), <sup>b</sup> statistically significant compare to (C+)

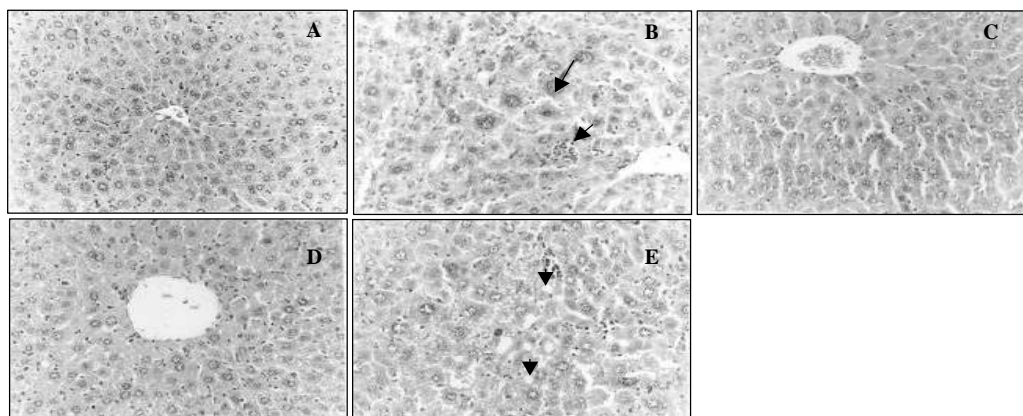


Fig. 2: Liver of mice of (C-) group showing normal hepatic structure (Hand EX 200) (A) (Grade 0). Liver of mice of (C+) group showing vacuolations of hepatocytes, karyomegaly and sinusoidal leucocytosis (B) (Grade 4). Liver of mice of (BSD) group showing no histopathological changes (C) (Grade 0). Liver of mice from (BPD) group showing no histopathological changes (D) (Grade 0). Liver of mice of (BCD) group showing vacuolization of hepatocytes (E) (Grade 1.5)

The morphological examinations above indicate that  $\text{CCl}_4$  can induce histopathological alterations in mice livers such as vacuolations of hepatocytes Fig. 2B.

However, soapworts (BSD) and pomegranate peel (BPD) supplementation in mice diets at 10% suppressed the overt histopathological alterations and led to normal liver tissues. In addition cloves (BCD) in mice diets reduced moderately the histopathological alterations in liver tissues as shown in Fig. 2E.

## DISCUSSION

**Hepatotoxic Effects of Carbon Tetrachloride:** Carbon tetrachloride is usually used to induce hepatotoxins in the animal studies of liver diseases [17]. It was found that chronic administration of  $\text{CCl}_4$  produced liver cirrhosis in rodents [18].

As expected, positive control (C+) mice group revealed a higher increase of liver functions indices such as bilirubin, ALT, AST and ALP and decreased albumin concentrations than negative controls (C-). Elevated levels of serum marker enzymes may explain cell membrane break down and death [19].  $\text{CCl}_4$  intoxication also produced a significant rise in serum bilirubin thereby indicating hepatic damage [20].  $\text{CCl}_4$  intoxication produced significant depletion of GSH and imbalance of GSH/GSSG ratio [21].

**Hepatoprotective Effect of Examined Herbs and Pomegranate Peel:** In the present study, we used soapworts, pomegranate peel and cloves as a target to

investigate their hepatoprotection in mice intoxicated by  $\text{CCl}_4$ . The investigators were interested in this approach because of no side effects and relative cost effectiveness.

Intoxication significantly lowered albumin and increased bilirubin levels (Table 2). Lipid peroxidation has been postulated to be the destructive process of liver damage due to  $\text{CCl}_4$  intoxication [22].

Some studies showed the presence of flavonoids, steroids, terpenoids and tannins in these herbs and pomegranate peel. It is known that some flavonoids are able to reduce xenobiotic-induced hepatotoxicity in animals and counteract the damaging effects of oxidative stress, cooperating with natural systems like glutathione and other endogenous protective enzymes [23-25].

The current study found a marked effect of herbs and pomegranate peel on intoxicated mice liver that decreased AST by 1.5-fold compare to (C+); soapworts was an example. This may be explained by inhibition of oxidative insults by natural antioxidants and high levels of iron and Manganese were found in soapworts [26].

Administration of  $\text{CCl}_4$  enhances lipid peroxidation thus the examined herbs may act to induce the detoxifying liver enzymes and these enzymes might detoxify the free radicals produced following carbon tetrachloride intoxication [27].

Therefore herbs may restore the activities of liver enzymes such as catalase in  $\text{CCl}_4$  intoxicated mice. A study showed that the presence of elevated levels of serum enzymes indicate cellular leakages and loss of functional integrity of cell membrane of liver cells. Serum (ALP) and bilirubin levels on the other hand are related to

the function of hepatic cells [28]. The examined herbs and pomegranate peel has significantly decreased the serum (ALT) and (AST) towards normal level. These indicate that herbs preserved the structural integrity of the hepatocellular membrane and liver cell architecture which is confirmed by histopathological studies. However, after switching to 10% herbal supplementation and pomegranate peel to mice diets these parameters declined approaching from normal levels specifically in the presence of soapworts (BSD) and pomegranate peel (BPD) diets. This was in line with other researches as follows: [29] aimed to assess the effect of chronic administration of pomegranate peel extract on liver fibrosis induced by bile duct ligation (BDL) in rats and found that serum (AST) and (ALT) was significantly decreased by pomegranate peel extract treatment. Toklu and co-workers concluded that results may indicate that the pomegranate flowers possess potent antioxidants that have hepatoprotective properties.

Our results are in agreement with El-Segaey *et al.* [30] who studied the antioxidant effects of cardamom and cloves on intoxicated rats by ethanol and found that both additives reduced significantly liver enzymes [31] found the same results.

No literature, however has reviewed the effect of soapworts as a hepatoprotective herb on the liver.

**Liver Histology:** It is well known that necrotizing agents such as  $\text{CCl}_4$  produce sufficient injury to hepatic parenchyma to cause elevation in bilirubin content in plasma [32]. These were confirmed by this study's chemical and histological results (Table 1 and Fig. 1). Hepatotoxic effects induced by  $\text{CCl}_4$  and were improved by the used herbs at 10% for thirty days. Soapworts and pomegranate supplementation completely prevented the replacement of vacuolations of hepatocytes and sinusoidal leucocytes (Fig. 2C).

These results substantiate the use of moderate quantities of soapworts, pomegranate peel and cloves in diet as agents that offer protection against liver injury. Antioxidant activity of these herbs may be responsible for the protective effect of Soapworts, Pomegranate Peel and Cloves in carbon tetrachloride intoxicated mice.

## CONCLUSION

The present study examined the protective effect of soapwort, pomegranate peel and cloves to combat the effect of tetrachloride administration on mice. This investigation was executed in the presence of 10% of soapworts, pomegranate peel and cloves in diet. Liver function tests have been carried out to examine the effect of herbs and pomegranate peel on bilirubin, albumin

(AST), (ALT) and (ALP) in the serum. The effect of diet supplementation with previous herbs and pomegranate peel on intoxicated mice liver had evidenced by an increment in the values of albumin, lowering AST and ALT, ALP and bilirubin. In addition the suppression of the overt histopathological alterations had led to normal liver tissues. For the first time it was found that addition of soapworts in mice diet at a 10% ratio, improved these parameters that have a tendency to retrieve liver functions towards normalcy.

## ACKNOWLEDGMENT

The authors would like to thank Helwan University; Faculty of Home Economics staff for their technical assistance in feeding experiment and staff from Pathology Department for histology examination, Faculty of Veterinary, Cairo University. We gratefully acknowledge the technical assistance from Prof. Hany Hassan, for assistance in biochemical analyses; Institute of Animal Reproduction, Giza, Egypt.

## REFERENCES

1. Athar, M., Z.S. Hussain and N. Hassan, 1997. Drug metabolizing enzymes in the liver. In: Rana SVS, Taketa K, editors. Liver and Environmental Xenobiotics. New Delhi: Narosa Publishing House.
2. Habib, M., M.K. Mohamed, F. Abdel-Aziz, L.S. Magder, M. Abdel-Hamid, F. Gamil, S. Madkour, N.N. Mikhail, W. Anwar, G.T. Strickl, A.D. Fix and I. Sallam, 2001. Hepatitis C virus infection in a community in the Nile Delta: risk factors for seropositivity. *Hepatology*, 33: 248-253.
3. Medhat, A., M. Shehata and S. Magder, 2002. Hepatitis C in a community in Upper Egypt: Risk factors for infection. *Am. J. Trop. Med. Hyg.*, 66: 633-638.
4. Friedman, S.L., 2000. Molecular regulation of hepatic fibrosis, an integrated cellular response to tissue injury. *J. Biol. Chem.*, 275: 2247-2250.
5. Chattopadhyay, R.R., 2003. Possible mechanism of hepatoprotective activity of *Azadirachta indica* leaf extract: Part II. *J. Ethnophar. Macol.*, 89: 217-219.
6. Hemnani, T. and M.S. Parihar, 1998. Reactive oxygen species and oxidative DNA damage. *Indian J. Physiol. Pharmacol.*, 42: 440-452.
7. Jeong, H.G., H.J. You, S.J. Park, A.R. Moon, Y.C. Chung, S.K. Kang and H.K. Chun, 2002. Hepatoprotective effects of Gly- cyrrheticinic acid on carbon tetrachloride induced liver injury: Inhibition of cytochrome P450 2E1 expression. *Pharm. Res.*, 46(3): 221-227.

8. Gil, M.I., F.A. Tomas-Barberan, B. Hess-Pierce, D.M. Holcroft and A.A. Kader, 2000. Antioxidant activity of pomegranate juice and its relationship with phenolic composition and processing. *J. Agric. Food. Chem.*, 48: 4581-4589.
9. Schubert, S.Y., I. Neeman and N. Resnick, 2002. A novel mechanism for the inhibition of NF-kappaB activation in vascular endothelial cells by natural antioxidants. *FASEB J.*, 16: 1931-1933.
10. Aviram, M., M. Dornfeld, R. Kaplan, D. Gaitini and B. Fuhrman, 2002. Pomegranate juice flavonoids inhibit low-density lipoprotein oxidation and cardiovascular diseases: studies in atherosclerotic mice and in humans. *Drugs. Exp. Clin. Res.*, 28: 49-62.
11. Esmailzadeh, A., F. Tahbaz, I. Gaieni, H. Alavi-majd and I. Azadbakht, 2004. Concentrated pomegranate juice improves lipid profiles in diabetic patients with hyperlipidemia. *J. Med. Food*, 7: 305-308.
12. Ambasta, S.P., 1986. The useful plants of India. New Delhi: Publications and Information Directorate, CSIR.
13. Reeves, P.G., Nielsen, F.H. and F.G.C. Jr, 1993. AIN-93 purified diets for laboratory rodents: final report of the American institute of nutrition ad hoc writing committee on the reformulation of the AIN-76a rodent diet. *J. Nutr.*, 123, 1939-1951.
14. Oser, B.L., 1965. Hawk's Physiological Chemistry, 14th ed. Tata Mc-Graw Hill Publishing Company Ltd, New Delhi, India, pp: 1052-1053, 1071-1073.
15. Bergmeyer, H.U. and E. Brent, 1974. Methods of Enzymatic Analysis vol.2. Bergmeyer, H. U. (Ed.) Verlag Chemie Weinheim, Academic Press, New York, 735, 760.
16. Bancroft, D., A. Stevens and R. Turner, 1996. Theory practice of histological Techniques, 4<sup>th</sup> edition, Churchill livingstone, Edinburgh, London, Melbourne.
17. Johnston, D.E., C. Kroening, 1998. Mechanism of early carbon tetra-chloride toxicity in cultured rat hepatocytes. *Pharmacol. Toxicol.*, 83: 231-239.
18. Brent, J.A. and B.H. Rumack, 1993b Mechanisms. Role of free radicals in toxic hepatic injury. II. Free radical biochemistry. *Clin. Toxicol.*, 31: 173-196.
19. Kaplowitz, N., T.Y. Aw, F.R. Simon and A. Stolz, 1986. Drug-induced hepatotoxicity. *Ann. Intern. Med.*, 104: 826-839.
20. Plaa, G.L. and W.R. Hewitt, 1982. Detection and evaluation of chemical induced liver injury. In: Hayes, A.W. (Ed.), Principles and Methods of Toxicology, Raven Press, New York, 407.
21. IP, S.P., M.K. T, C.T. PoonChe, K.H. Ng, Y.C., KO, K.M. Kong and B. Schisandrin, 1996. Protects against carbon tetrachloride toxicity by enhancing the mitochondrial glutathione redox status in mouse liver. *Free Radic. Biol. Med.*, 21(5): 709-712.
22. Muriel, P., 1997. Peroxidation of lipids and liver damage. In: Baskin, S.I., Salem, H. (Ed.), Antioxidants, Oxidants and Free radicals. Taylor and Francis, Washington, DC, 237.
23. Carini, R., A. Comoglio, E. Albano and G. Poli, 1992. Lipid peroxidation and irreversible damage in the rat hepatocyte model. Protection by the silybin-phospholipid complex IdB. *Biochem. Pharmacol.*, 43: 2111-2115.
24. Paya, M., M.L. Ferrandiz, M.J. Sanz and M.J. Alcaraz, 1993. Effects of phenolic compounds on bromobenzene-mediated hepatotoxicity in mice. *Xenobiotica*, 23: 327-333.
25. Kadarian, C., A.M. Broussalis, J. MinoLopez, P. Gor-zalcany, S. Ferraro and G. Acevedo, 2002. Hepatoprotective activity of Achyrocline satureioides (Lam) D.C. *Pharm. Res.*, 45(1): 57-61.
26. Abdel-Moemin, A.R., 2004. To investigate the antioxidant properties of dietary flavonoids in human metabolism. PhD Thesis, The Queen's University of Belfast.
27. Malaya, G., V. mazumder, I. thamilselvan, S.R. manikandan and B.K. kakotti, 2007. Potential Hepatoprotective Effect and Antioxidant Role of Methanol Extract of Oldenlandia umbellata in Carbon Tetrachloride Induced Hepatotoxicity in Wistar Rats 1735-2657/07/61-5-9 IJPT., 6: 5-9.
28. Drotman, R.B. and G.T. Lawhorn, 1978. Serum enzymes are indicators of chemical induced liver damage. *Drug Chem. Toxicol.*, 1: 163-171.
29. Toklu, H.Z., M.U. Dumlu, Ö. Sehirli, F. Ercan, N. Gedik, V. Gökmen and G. Sener, 2007. Pomegranate peel extract prevents liver fibrosis in biliary-obstructed rats. *J. Pharmacy and Pharmacology*, 59(9): 1287-1295.
30. Segae, O., A. Ab-Allah and S. AbuAl-Nooman, 2007. Experimental study of antioxidant and hepatoprotective effects of cloves and cardamon in ethanol induced hepatotoxicity. *Tanta Medical Sciences Journal*, 2(1): 27-36.
31. Wahhab, A. and M. Aly, 2005. Antioxidant property of nigella sativa (black cumin) and syzgium aromaticum (clove) in rats during aflatoxicosis. *Journal of Applied Toxicology*, 25(3): 218-228.
32. I.P.C.S. Environmental health criteria, 2008. Carbon tetrachloride. World Health Organization, Geneva, 1999, pp: 50.