World Applied Sciences Journal 33 (11): 1779-1783, 2015
ISSN 1818-4952

DOI: 10.5829/idosi.wasj.2015.33.11.15628

Histopathological Studies on Albino Rats Liver Exposed to Abakaliki Rice Husks Dust

[1]M.E. Ogbanshi, [1]C.O. Ogbu, [1]K.N. Agbafor, [2]J.N. Idenyi, [2]L.N. Ebenyi, [2]F.O. Orinya and [3]F.U. Ali

[1]Biochemistry Department, Ebonyi State University, Abakaliki, Nigeria
[2]Department of Biotechnology, Ebonyi State University, Abakaliki, Nigeria
[3]Department of Medical Biochemistry, Ebonyi State University, Abakaliki Nigeria

Abstract: The aim of this study was to evaluate the total protein and albumin levels and the probable histopathological changes in the liver of albino rats following the inhalation of the husks dust from Abakaliki rice mill during processing. A total of 100 albino rats were used in the study. The rats were classified randomly into four groups A, B, C and D (25 per group), with groups B, C and D as experimental groups which were exposed to the husks dust while group A was left as a control group. After the exposure, both the experimental and the control groups were sacrificed and subjected to necropsy and their liver were examined histopathologically. The present study indicated structural and functional alterations in liver of the rats like severe deposit of necrotic tissues with great distortion and widening of the central vein; moderate infiltration of inflammatory cells was also noticed in experimental groups contrary to the control which showed normal liver histoarchitecture. The investigations further showed significant alteration in the levels of serum total protein and albumin. The histopathologic observations and altered liver function test indicated that hepatic tissue injury was caused by rice husks dust and associated endotoxins and other working stresses in the milling environment, which act synergistically to produce toxic stress. Thus, making the rice husks dust a potential harmful substance to the inhabitants of the rice milling environment.

Key words: Histopathological changes · Rice husk · Toxicity · Inhalation and pollutants

INTRODUCTION

Rice husk dust (also called rice hull) are the coatings of seeds or grains of rice in addition to protecting the seed during the growing season. The husk is formed from hard materials including opaline, silica [1] and lignin and is mostly indigestible to humans. In Abakaliki rice mill industry, rice husks is removed by winnowing which involve throwing the rice with its husks on the air for wind to blow away the husks while the heavy rice grain remain in the pan. Occupational health hazards among people exposed to different organic and inorganic dusts have been known for many centuries. Industrialization resulted in a different kind of microenvironment with high dust, particulate matter concentration, noise, vibration and other stressful workplace situations. Inhalational dusts undergo biotransformation in varying rates and as a result, metabolic products are formed and some of these products are excreted through kidneys, whereas others are retained and cause hepatic injury by immunological reactions of reactive metabolites. These metabolites produce serious microsomal lesions by raising lipid peroxidation and malonyaldehyde [2-4].

Since Ramzzini's observations in 1713, health hazards resulting from exposure to different organic dusts like, hay dust, wood dust, sugar cane dust, grain dust and dust of compost, exposure induced health hazards have also been reported in workers in industrial fermentation facilities and sewage treatment [5-9]. It has been well established that exposure to cotton, hemp or flax also results in chest tightness, mill fever and on chronic exposure results in byssinosis [10-14].

Corresponding Author: M.E. Ogbanshi, Biochemistry Department, Ebonyi State University, Abakaliki, Nigeria.

Although milling industry constitutes the single largest industry employing lots of workers, very little attention is paid to comfort, health and safety facilities of the works [15]. The high cotton dust and endotoxin(s) concentration, noise vibrations, heat, poor illumination and ventilation, high humidity, old outdated machines, faulty workplace layout and long hours of work act synergistically to produce toxic stress on the workers [16]. The industry has been subjected to various investigations pertaining to socio-economic aspects. The working conditions of milling industries are very poor [17]. The present study has been carried out to observe the histopathologic alterations in liver under the influence of rice husks dust inhalation and other occupational stresses in Abakaliki rice mill environment.

Methodology

Source of Experimental Animals: A total of one hundred albino rats were obtained from the school of veterinary Medicine, Nnamdi Azikiwe University Awka, Anambra State, Nigeria.

Experimental Plan: The animals used for this study were adult albino rats weighing about 190-210 grams. The rats were kept in metallic cages with enough space for free movement inside the department's animal house away from the rice mill industry. The cages were cleaned every day and all the animals were acclimatized for 7days before the commencement of this study. The animals were fed with standard pellet feed and water *ad libitium.* After the first week, the animals were grouped into four; A, B, C and D groups. Each group contains 25 rats, group A served as the control and was never exposed to the rice husks dust. Whereas, groups B, C and D were exposed for 14, 21 and 28 days respectively from morning till evening before they are returned to the animal house located around the rice mill area. Physical examinations such as posture activity, fur texture, weight etc. were checked throughout the periods of exposure.

Sacrifice Procedure: The rats of control and exposed groups were sacrificed by cervical dislocation in conformity with the animal welfare law. The liver was removed, washed and then used for further studies.

Histological Study: The liver was cut into pieces and fixed in neutral buffered formalin over night. Thereafter, it was washed and dehydrated in ethanol, cleared in xylene and embedded in paraffin wax. 7 microns sections were stained with hematoxylin and eosin and examined under light microspy.

Total Serum Protein Determination: This was analyzed by modified Doumas *et al*., (2005) [5] method, using diagnostic MERCK-0499 test kits. The colour developed were read using filter 546 on kinetic mode of multianalyser "Express plus". The total proteins were calculated in g/dl.

Determination of Plasma Albumin: Albumin was analysed by Rietman and Frankel modified method (7), using diagnostic MERCK-0499 test kit. The albumin level was measure at 546 on kinetic mode of multianalyser "Express plus". The total proteins were calculated in g/dl.

RESULTS

Weight Change: Table 1 shows the mean and standard deviation of the weight of rats. In group A (control group) there was a tremendous increase in the weight of rats. While in group B (exposed for 14-days), group C (exposed for 21-days) and group D (exposed for 28-days) there was a successive decrease in the weight of rats.The decrease in the weights of rats may not be due to the inhalation of the rice husk dust but stress. In figure 5 below group A is the control group, group B were exposed for 7-days, group C were exposed 14-days, while group D were exposed for 21-days.

Table 1: Weight change in grams of mean ± standard deviation of both control and exposed rats

S/N	Groups A	Groups B	Groups C	Groups D
1	204.28±4.49	193.57±6.26	192.5±7.78	180.95±17.14
2	192.14±11.49	201.42±5.94	182.5±11.05	183.33±19.05
3	206.78±11.00	187.85±2.67	197.5±11.56	200±19.05
4	210.71±7.80	186.42±4.75	186.78±10.3	180.47±12.75
5	184.76±11.58	196.42±3.77	188.57±10.08	180.47±17.16
6	210.47±11.16	175.71±5.34	168.57±9.88	169.76±14.27

Fig.1 (control)

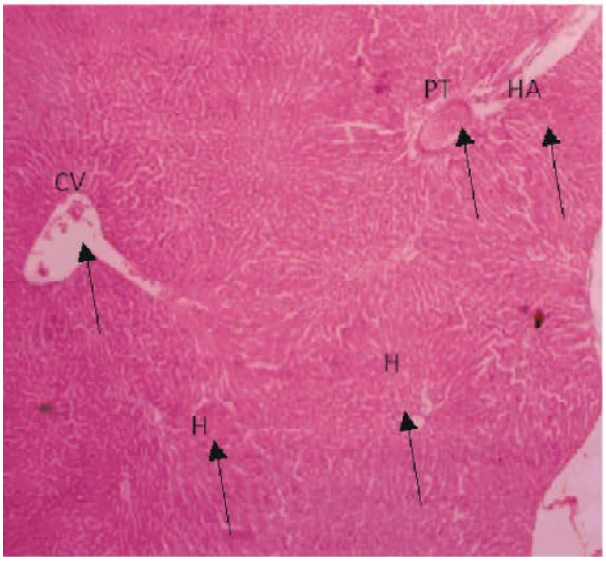

Fig.3 (exposed for 21 days)

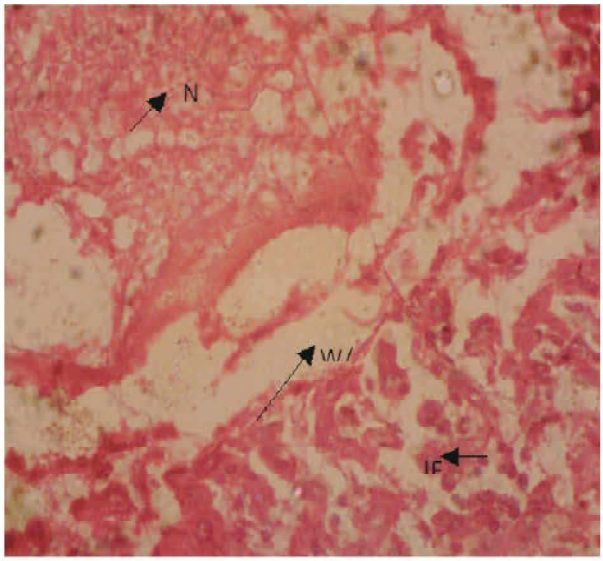

Fig.2 (exposed for 14 days)

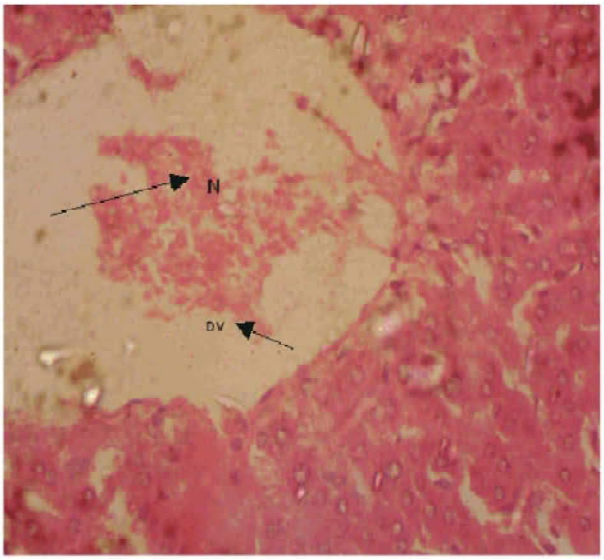

Fig.4 (exposed for 28 days)

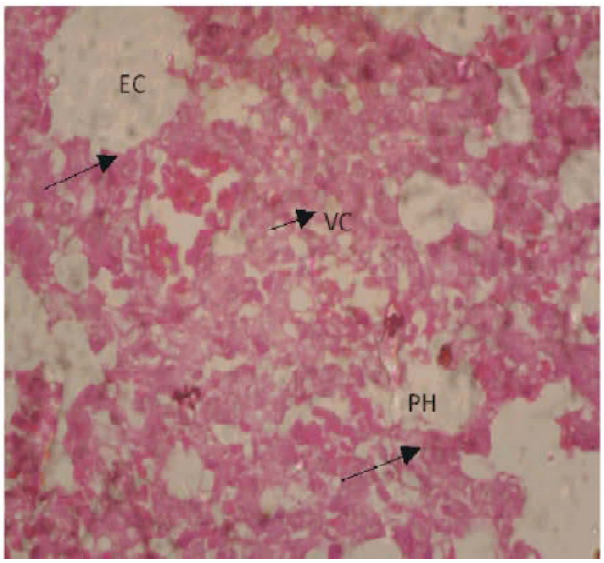

Fig. 1: The photomicrography of unexposed (control) rats liver revealed normal central vein, normal portal track, normal hepatic cells and normal hepatic sinusoid. Method of staining (H and E). Magnification X4. CV-central vein HS-hepatic sinusoid PT-portal tracks HC- hepatic cells HA- hepatic arteries.

Fig. 2: The photomicrography of exposed liver shows severe deposit of necrotic tissue, distortion and widening of central vein and moderate infiltrate of inflammatory cells. The cytological components are represented using arrows. Method of staining (H and S). magnification X4. IFC- inflammatory cell, W/DV- widening/distorted vein, NT-necrotic tissue

Fig. 3: The photomicrography of exposed liver shows NC-Necrotic Tissue, DCV-Dilated Central Vein, IFC-Inflammatory Cell. Method of staining (H and E). Magnification X4.

Fig. 4: The photomicrography of exposed liver shows EC-eosinophilic cytoplasm in hepathocytes,VC-vacuolated cytoplasm of hepathocytes, PH-polyploidy of some hepathocytes. Method of staining (H and E) magnification X4.

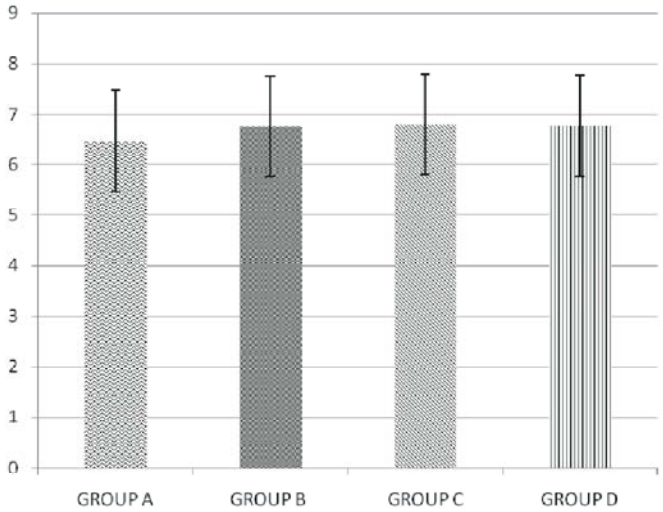

Fig. 5: Bar chart of total protein levels (g/dl).

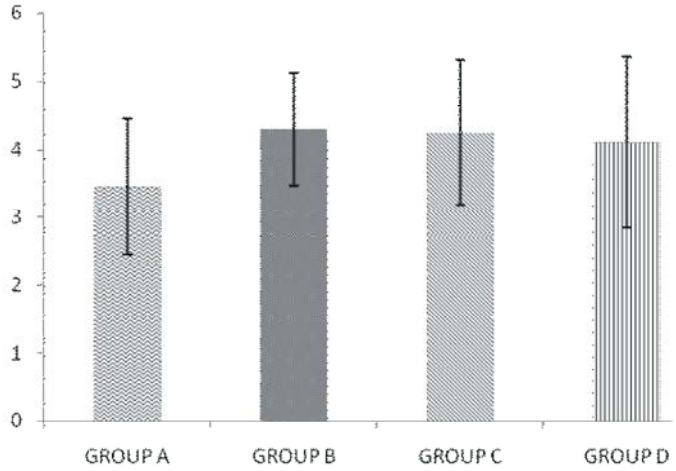

Fig. 6: Bar chart of albumin levels (g/dl)

DISCUSSION

The rats on exposure to rice husks dust and its associated endotoxin(s) in the milling environment generally showed significant histological and physiological alterations (figs. 1-4). The study also showed markedly enlarged reddish brown coloured liver in rats from the exposed groups.

The liver histology sections showed normal central vein, normal portal track, normal hepatic cells, arteries and normal hepatic sinusoid for liver in group A (control) as evidenced in fig. 1. The histoarchitecture of the rat liver in group A conforms to that of [16].

Group B (exposed for 14 days) showed severe deposit of necrotic tissue, distortion and widening of central vein and moderate infiltrate of inflammatory cells as seen in fig. 2.

Group C (exposed for 21 days) rat liver showed mild infiltrate of inflammatory cells, special lymphocytes and dilated central vein that is containing necrotic tissues as contained in fig 3. Group D (exposed for 28 days) showed eosinophilic cytoplasm in hepathocytes, vacuolated cytoplasm of hepathocytes and polyploidy of some hepathocytes. Rice husk from this work has proved to be one of the pollutants that affects the liver negatively thereby resulting in liver damages like deposit of necrotic tissue, infiltrate of inflammatory cells, distortion and widening of central vein and in general, disruption of hepatic architecture seen in figs. 2 and 3 above. Rozainee *et al*., 2008 made a similar observation in his study that liver and the kidneys are the major organs affected by inhalational pollutants. From this experiment, result reveals greater widening of the central vein with more infiltration of inflammatory cells in fig. 2 compare to fig. 3.

This is so because the albino rats of fig. 3 were in very close contact to the pollutant (rice husk) and were also exposed for a longer period and this evidently reflects greater toxic effect as observed in their photomicrography shown in fig. 3. This is also in accordance with study repoted by [12].

The result of some biochemical parameters showed a significant alteration in levels of total protein and albumin. Fig.5 shows that the albumin level increased in groups B, C and D than the level seen in group A, with group B having the highest level of increase followed by group C then D. Total protein level increased in group B, C and D than seen in control group as shown above in fig.6. However, this is in strong agreement with the study of Karnik *et al.,* (2007) [8]; who reported a significant alteration in the levels of total protein and albumin as a result of exposure of rats to cotton dust, whereas both beta and gama globulin were increased. The hepatopathologic observations and altered liver functions test values as indicated in this present study shows that hepatic tissue injury was caused as a result of rats exposure to rice husks dust and associated endotoxin(s) in the milling environment. (Dubal, 2002) [7] observed in his study that rice husks and cotton dust fibers are contaminated with gram negative bacteria, gram positive bacteria and allergic fungal spores. Stress can also induce increase in serum transaminases (SGOT and SGPT), this is also found in sound/noise stressed rat [11].

Table 1 showed a general decrease in the body weight of all the exposed group as compared to the control. This reduction in weight of the exposed rats reflect a decline in the health condition of the exposed animals. Moreso, the weight decrease seen in the experimental animals could be as a result of sound/noised stress around the milling environment as reported by [11].

Based on the results of our present study, we assert that the prevalence of hepatotoxicity due to rice husks dust inhalation and associated endotoxin(s) seems to exert marked effect on secretory and excretory efficiency of liver. The changes in the levels of albumin and total protein as we observed in this present study are a good indication of these effects. Secondly, the weight decrease seen in the experimental animals could be as a result of sound/noise and other stress conditions around the milling environment.

REFERENCES

1. Faiziev, S., 2003. Synthesis of ceramic compounds utilizing woody waste material and rice husk construction and building materials. Material Science Forum, 21: 2059-2065.
2. Adylov, G.T., S.A. Faiziev and M.S. Paizullakhanov, 2003. Silicon carbide material obtained from rice husk. Technical physics letters, 29: 221-223.
3. Agus, S.M., 2002. Utilization of uncontrolled burnt rice husk ash in soil improvement. *Dimensi teknil sipil*, 4: 100-105.
4. Shi, J., K. Asiaki, Y. Ikawa and K. Wake, 2003. Evidence of Hepatocyte Apoptosis in Rat Liver after the Administration of Carbon Tetrachloride. J. Med Res., 4: 1-8.
5. Doumas, T.B., T.J. peters and Bio-mocule, 2005. Protein (total protein) in serum, urineand cerebrospinal fluid. In: selected method of clinical chemistry (W.R. Faulkner and S. Meites, eds) 9. Washington D.C., pp: 822-828.
6. Dubal, R.S., 1995. physiological studies on textile workers: M. phil thesis, shivaji university, Kolhapur, 5: 18-23.
7. Dubal, R.S., 2002. physiological reactions to cotton dust; development of animal model. Ph. D thesis, shivaji university, Kolhapur.
8. Karnik, A.B., Parikh, H.H. patel, B.C. lakkad, P.K. kulkarni and S.K. nigam, 2007. ind. Med. Res., pharmacology, 85: 22-26.
9. Lott, J.A. and J.M. Stang, 1978. Serum Enzyme and Isoenzyme in the diagnosis of Myocardial Ischemia and necrosis. Clin. Chem., 24: 832-834.
10. Merchant, J.A., G.M. Harpin, A.R. Hudson, K.H. Kilburn, W.L. mckenzie, J.D. Hurtz and Bermazohlp, 1975. Histo-architectural studies on rat liver and kidney. Environmental health, 30: 222-229.
11. Nagaraja, H.S. and P.S. jeganathan, 2009. industrial journal of physiology. Pharmacology, 43(3): 296-304.
12. Ndukwe, G.U., 2001. Fundamental Histology. 1st Edition. Chinedum Publ., pp: 178-181.
13. Ramzzini, B., 2004. De morbis, Aritificum Diatriba. Chicago University press, 5th edition; pp: 232-234.
14. Rozainee, M., S.P. Ngo and A.A. Salema, 2008. Effect of fluidizing velocity on the combustion of rice husk in a bench-scale fluidised bed combustor foe the production of amorphous rice husk ash. Bioresource Technology, 99: 703-713.
15. Rylander, R., 1990. Physiological studies on rats exposed to husks. American Journal of industrial toxicology, 17: 1-2.
16. Sadler, T.W., 2008. Langman's Medical Embryology. 10th Edit. Wolters Kluwer (India) Pvt Ltd. New Delhi, pp: 213-215.
17. Sanandam, M.R., 2002. Physiological studies of rat exposed to cotton dust. Ph. D thesis, shivaji university, Kolhapur, 39(5): 332-338.