World Applied Sciences Journal 26 (4): 438-448, 2013
ISSN 1818-4952

DOI: 10.5829/idosi.wasj.2013.26.04.76159

Effect of Water Quality Changes on Gills and Kidney Histology of *Oreochromis niloticus* Fish Inhabiting the Water of Rosetta Branch, River Nile, Egypt

Seham Ahmed Ibrahim

Department of Zoology, Faculty of Science,
Benha University, Benha, Qalyubia Governorate, Egypt

Submitted: Oct 11, 2013; **Accepted:** Nov 10, 2013; **Published:** Nov 19, 2013

Abstract: Some physicochemical parameters of water at three selected stations (Kafr El-Zyat, Tamalay on Rosetta branch of the River Nile and Shanawan drainage canal at Shanawan village, Egypt) were studied. Also, the effect of water quality changes on histology of gill and kidney obtained from *Oreochromis niloticus* fish living in these three stations were studied. The results revealed noticeable changes in water quality at the three studied regions but in different degrees. Also, the collected fish from the three regions suffered from several histopathological signs in their gills and kidney including: necrosis, degeneration, hemorrhage, hemolysis, hemosidrin, fibrosis, hyperplasia and fussion.

Key words: Water Pollution · Histopathology · Gills · Kidney · *Oreochromis niloticus*

INTRODUCTION

River Nile, the artery of life in Egypt, is one of the very long rivers in the world. It is approximately 6700 km long, the length of River Nile inside Egypt is approximately 1352 km [1].

River Nile travels 940 km behind the High Dam; it divided into two branches, the western Rosetta branch and the eastern Damietta branch, where they suffer from many types of wastes including, industrial, agricultural and sewage [2]. The term water quality includes all physical, chemical that influence the beneficial use of water [3].

Aquatic animal particularly fish could serve as biological indicators for environmental degradation and pollutants in aquatic habitats [4].

Fish are important members of aquatic ecosystems and an important source of human food. However, fish distribution data in Egypt indicate a reduction in the commercially desirable fish species as the water conditions deteriorate. The agricultural, waste municipal and industrial effluents discharged directly to the natural water resources have been found to cause heavy fish mortality due to hypoxia, high levels of organic substances, inorganic salt and heavy metals [5].

Freshwater fish are the most vertebrate groups exploited by humans [6]. About 160 species are endangered and about one species per year becomes extinct. The threats include water reduction, pollution, over-fishing and impacts of exotic species [7].

Fish likewise other aquatic organisms, are greatly affected with chemical pollutants present in the ecosystem [8]. It is recommended that the developed histopathological changes in fish can be used as bioindicators for environmental pollution [9].

Gills of teleosts, representing a large part of the body surface, are not only important as respiratory organ but also as a main site of water and salts fluxes. Gills have several vital functions such as gas exchange [10], ionic regulation [11, 12], nitrogen excretion and acid-base regulation [13] and detoxification [14]. It is basically and logically the gill tissue, which undergo pathological changes resulting in complex physiological problems [15].

In addition to excretory function of kidney, it also releases three substances, renin, erythropoietin and 1, 25 dihydroxy cholecolciferol, directly into the blood stream. Renin plays an important role in regulating sodium ion concentration whereas erythropoietin influences hemopoietic activity [16].

So this study aimed to find out the present status of water quality in River Nile and a drainage canal due to the discharge of untreated wastes and the effect of these wastes on histology of gills and kidney of *O. niloticus* fish.

Corresponding Author: Seham Ahmed Ibrahim, Department of Zoology, Faculty of Science, Benha University, Benha, Qalyubia Governorate, Egypt.

MATERIALS AND METHODS

Water and fish samples were collected during summer of 2012 from three stations. The first station is in front of Kafr El-Zyat soap factory which discharge industrial wastes into Rosetta branch of River Nile, the second one is at Tamalay village which discharge agricultural wastes into Rosetta branch of River Nile and the third station in Shanawan drainage canal at Shanawan village which receives drainage water from adjacent fields besides runoff of sewage from adjacent villages (Fig. 1). The fish of the control group were collected from El-Kanater El-Khyria fish farm, Egypt.

Water Sample Analysis

Field Measurements: Air and water temperature (°C) was determined by dry mercury thermometer, pH value by Orion Research Ion Analyzer 399 A pH meter, transparency (cm) was determined by using Secchi-disc and electric conductivity (µmohs/cm) by using conductivity meter model (YSI SCT-33, USA).

Laboratory Analysis: Water samples were kept into a one liter polyethylene bottle in ice box and analyzed in the laboratory. The procedures used are specified in APHA [17].

The dissolved oxygen content was performed by azide modification. Total dissolved solids were determined by filtration a volume of sample with glass microfiber filter (GF/C) and a known volume of filtrate was evaporated at 105°C. Chloride was determined by argentometric method. Concentration of ammonia, nitrite and nitrate were determined by using the colorimetric techniques with nessterization, formation of reddish purple azodye and Cd reduction, respectively. Carbonate and bi-carbonate alkalinity was measured analytically.

Fig. 1: Map showing Kafr El-Zayt, Tamaly and Shanawan stations.

Fish Samples: The collected fish samples were dissected. Gills and kidneys were carefully removed and fixed in 10% formalin, dehydrated in ascending grades of alcohol and cleared in xylene. The fixed tissues were embedded in paraffin wax and sections of five micrometers thick were cut, using Euromex Holland microtome and the paraffin sections were stained with hematoxylin and eosin (H and E) method according to Bucke [18]. The sections were examined histopathologically by light microscope and photographed by using a microscopic camera.

Statistical Analysis: The means and standard deviations of the measured parameters were estimated using the Microsoft Excel 2010 computer program.

RESULTS

Water Quality: Physicochemical characteristics of water collected from the three studied stations along the Rosetta branch, including Kafr El-Zyat, Tamalay and Shanawan are shown in Table (1).

Physical Parameters

Air and Water Temperature: The results showed a descending order of air temperature as follows: Shanawan (31.8 °C) > Kafr El-Zyat (30.30 °C) > Tamalay (27.60 °C). While the water temperature as follows: Kafr El-Zayat and Shanawan (28.73°C) > Tamalay (25.75°C).

Transparency: The results showed a descending order of transparency as follows: Kafr El-Zyat (66.93 cm) > Tamalay (64.30 cm) > Shanawan (56.47 cm).

Electrical Conductivity: In present study the highest conductivity value (486 µmohs/cm) was recorded at Shanawan station while the lowest value was (399.33 µmohs/cm) recorded at Kafr El-Zyat station.

Chemical parameters

pH value: The results of pH clarified that the area under study lies in alkaline side. The values ranged from 8.15 at Tamalay to 8.32 at Kafr El-Zyat

Carbonate and Bicarbonate Alkalinity: In present results the highest carbonate alkalinity (17.87 mg/L) recorded at Kafr El-Zyat station and bicarbonate alkalinity (430 mg/L) recorded at Shanawan station.

Total Dissolved Solids: In present study the higher value of (TS) recorded at Shanawan station (249.7 mg/L).

Table 1: Physicochemical characteristics of water (mean ± standard deviation) at different stations of the study area

Parameters	Stations		
	Shanawan	Tamalay	Kafr El-Zyat
A) Physical			
1-Air temperature (°C)	31.800±0.200	27.600±0.141	30.300±0.100
2-Water temperature (°C)	28.733±0.404	25.750±1.909	28.733±0.153
3-Transparency (cm)	56.467±1.747	64.300±1.131	66.933±1.721
4-Electrical conductivity (µmohs/cm)	486.000±8.544	426.000±1.414	401.000±5.568
B) Chemical			
5-pH value	8.223±0.068	8.150±0.071	8.317±0.076
6-Carbonate alkalinity (mg/L)	15.000±0.200	7.950±0.071	17.867±0.306
7-Bicarbonate alkalinity (mg/L)	430.000±2.000	432.500±3.536	390.500±4.093
8-Total dissolved solids (mg/L)	249.667±4.041	249.000±1.414	196.067±2.101
9-Dissolved oxygen (mg/L)	5.680±0.052	6.505±0.035	6.367±0.153
10-Chloride (mg/L)	40.333±0.611	36.100±0.424	40.933±0.115
11-Ammonia (mg/L)	0.993±0.012	0.685±0.049	0.810±0.030
12-Nitrite (µg/L)	119.400±2.722	126.100±0.424	49.900±0.361
13-Nitrate (µg/L)	479.567±4.366	572.900±6.930	230.100±1.769

Dissolved Oxygen: In the present study, the values of dissolved oxygen were 5.68 mg/L, 6.37 mg/L and 6.51 mg/L at Shanawan, Kafr El-Zyat and Tamalay Stations, respectively.

Chloride Content: The highest value of chloride in present study (40.93 mg/L) was recorded at Kafr El-Zyat station.

Ammonia, Nitrite and Nitrate: In present study the highest ammonia value (0.993 mg/L) was recorded at Shanawan station and the lowest value (0.685 mg/L) was recorded at Tamalay station. The higher value (126.1 µg/L) of nitrite was recorded at Tamalay station and the lowest value (49.900 µg/L) was recorded at Kafr El-Zyat station. The highest nitrate value (572.911 µg/L) was recorded at Tamalay station and the lowest value (230.100 µg/L) was recorded at Kafr El-Zyat station.

Histological Studies: The normal gill consists of cartilaginous arch holding rows of filaments (Fig. 2). The filament consists of primary and secondary lamellae. The secondary lamellae include branchial epithelium consisting of a layer of one or two cells of interdigitating squamous epithelial cells.

In present study, the sections of gills specimens of *Oreochromis niloticus* from Kafr El-Zyat station exhibited hyperplasia (Figs. 3, 4, 8) progressed to complete fusion of secondary lamellae (Figs. 3, 6, 7). The fish gills showed telangiectasis (congestion with blood cells in the tips of secondary lamellae) (Fig. 5). The fish gills also suffered from severe hemorrhage in primary lamellae (Figs. 3, 8), degeneration (Fig. 8), necrosis (Fig. 4) and separation (Figs. 3, 7, 8) and curling (Figs. 5, 6) in secondary lamellae.

While the specimens obtained from Shanawan station showed hemorrhage (Figs. 9, 10, 12, 13, 14), hemolysis (Fig. 12), hyperplasia (Figs. 9, 10, 11, 12), separation (Figs. 9, 11, 12, 13, 14), curling (Figs. 9, 12, 13, 14), degeneration (Figs. 10, 12, 13) and necrosis (Fig. 10) in primary and secondary lamellae.

However, gills obtained from Tamalay station suffered from hemorrhage (Fig. 15), telangiectasis (Figs. 15, 18), curling (Figs. 15, 17, 18, 20), separation (Figs. 15, 16, 17, 19), hyperplasia (Figs. 17, 18, 19, 20), necrosis (Fig. 19) and degeneration (Fig. 20).

Normal kidney of *Oreochromis niloticus* fish is composed of identical nephrons. Each nephron contains renal corpuscle that leads to renal tubule. The renal corpuscle contains vascular capillary glomerulus that is enclosed by Bawman's corpuscle. Within the nephron, the kidney contains hematopoietic tissue and blood vessels. The renal tubules have various segmentation and accordingly appear in different shapes (Fig. 21).

Changes in water quality induced pathological changes in fish. The kidney of *Oreochromis niloticus* fish collected from Kafr El-Zyat station revealed degeneration in renal tubules (Figs. 22, 23, 24, 25), necrosis in renal and Malpighian tubules (Figs. 22, 23, 25). Hemorrhage (Figs. 23, 24, 25, 26, 27), hemolysis (Fig. 25), hemosidrin (Figs. 22, 27) and Fibrosis (Fig. 27) in hematopoietic tissue.

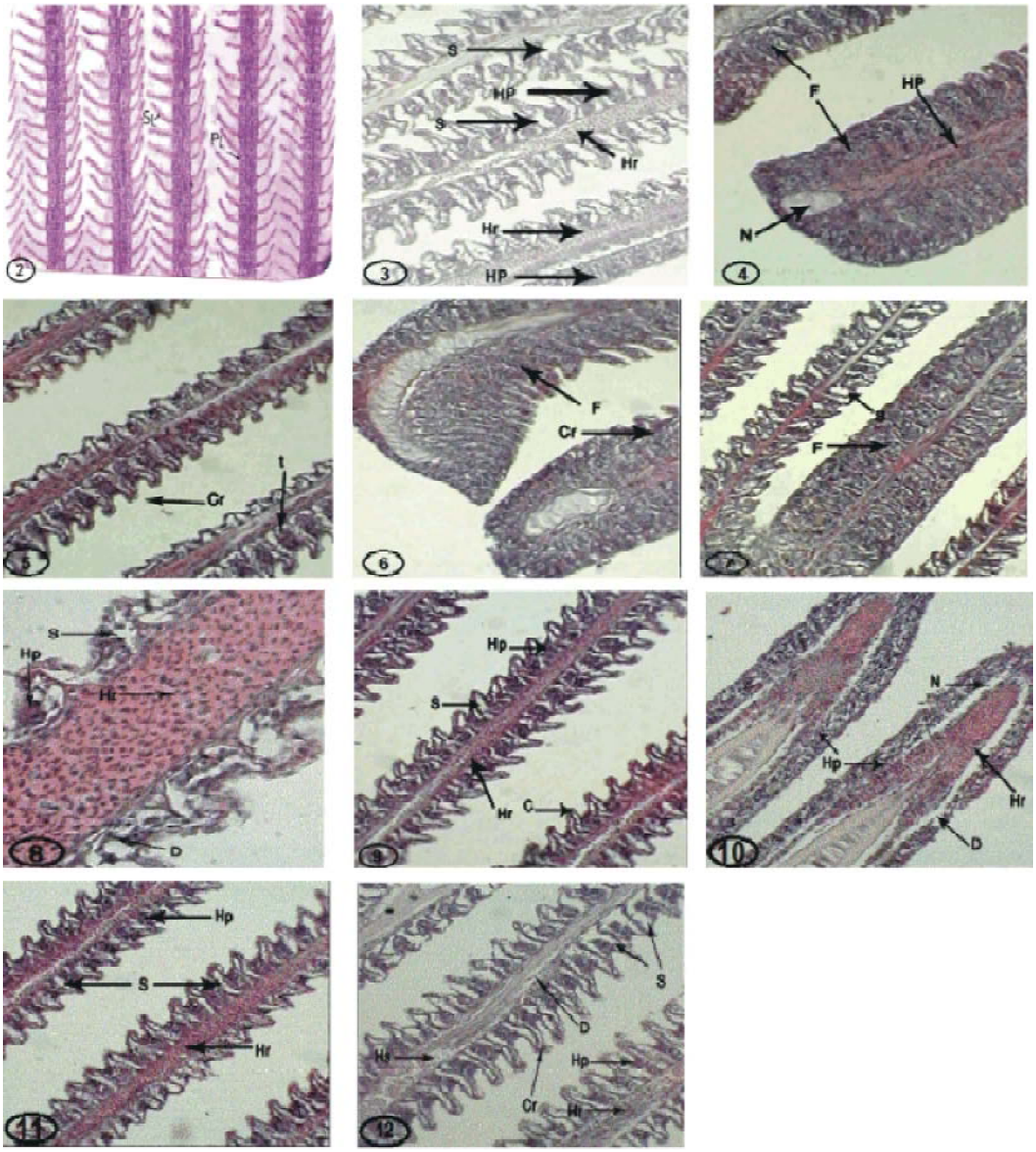

Figs. (2-12): Histological section in gills of *Oreochromis niloticus* stained with H and E, X400. (2). Normal structure of gill showing primary (PL) and secondary (SL) lamellae. (3) L.S. of fish gills of *O. niloticus* obtained from Kafr El-Zyat station showing hemorrhage (Hr) in center of primary lamellae, hyperplasia (Hp) and separation (S) in epithelia cells of secondary Lamellae. (4) Severe hyperplasia (Hp) in primary and secondary lamellae leads to complete fusion (F) of primary and secondary lamellae and necrosis (N) in top of fused lamellae. (5) Curling (Cr) and Telangiectasis (t) at the tips of secondary lamellae. (6) Complete fusion (F) of primary and secondary lamellae in addition curling (Cr) of fused filament. (7) Fusion (F) of primary and secondary lamellae. (8) Severe hemorrhage (Hr) in center of primary lamellae and hyperplasia (Hp) separation (S). (9) L.S. of fish gills of *O. niloticus* obtained from Shanawan station showing hemorrhage (Hr) in center of primary lamellae, hyperplasia (Hp) separation (S) and curling (Cr) in secondary lamellae. (10) Severe hyperplasia (Hp) in primary and secondary lamellae lead to fusion of two lamellae, degeneration (D) and necrosis (N) in cells of fused lamellae in addition to severe hemorrhage (hr) in center of filament. (11) Hemorrhage (hr) in center of primary lamellae, hyperplasia (Hp) and separation (S) in epithelial cell of secondary lamellae. (12) Hemorrhage (Hr), degeneration (D) and hemolysis (Hs) in primary lamellae, hyperplasia (Hp), separation (S) and curling (Cr) in secondary lamellae.



Figs. (13-20): (13, 14 and 15) Severe hemorrhage (Hr) in centers of primary lamellae and curling (Cr) and separation (S) in secondary lamellae. (16, 17 and 18) L.S. of fish gills of *O. niloticus* obtained from Tamalay station showing severe hemorrhage (Hr) in primary lamellae and curling (Cr) and separation (S) of secondary lamellae. (19) Hyperplasia (Hp), separation (S) and severe necrosis (N) in epithelial cells of secondary lamellae. (20) Severe hyperplasia (Hp), curling (Cr) and degeneration (D) in epithelial cells of primary and secondary lamellae.

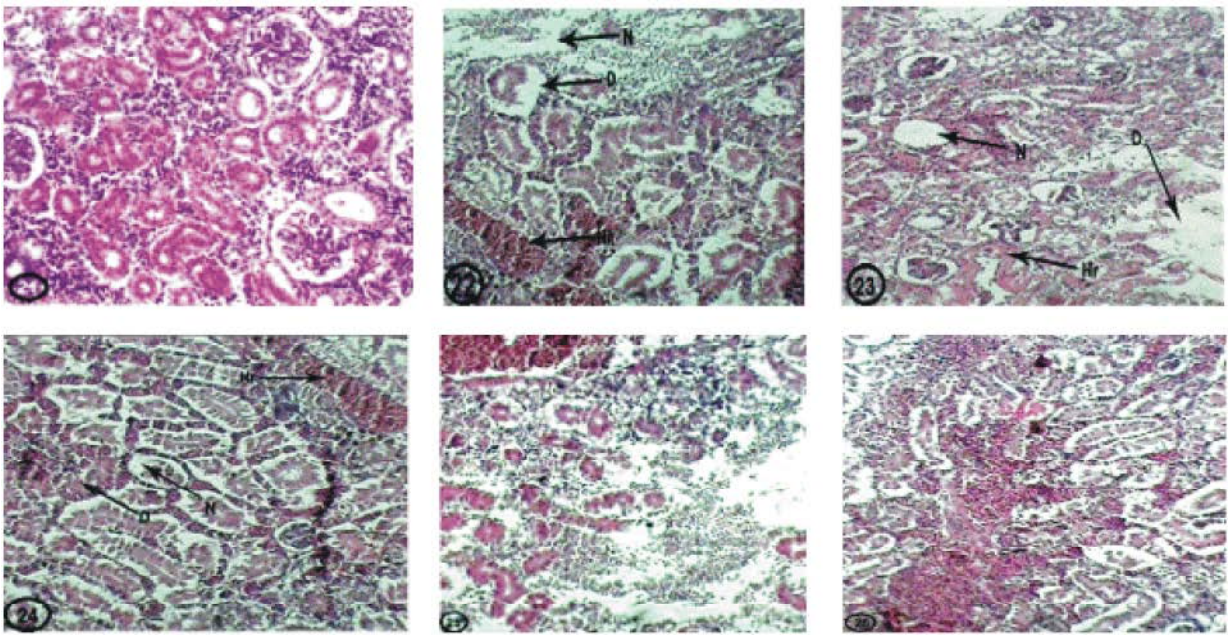

Figs. (21-26): Histological section in kidney of *Oreochromis niloticus* stained with H and E, X400. (21) Normal structure of kidney showing identical nephrons, hematopoietic tissue and blood vessels. (22) Kidney section of *O. niloticus* obtained from Kafr El-Zyat station showing degeneration (D) and necrosis in renal tubule, hemosiderin (Hn) and Haematopoietic tissue. (23) Necrosis (N) in malpighian corpuscles, hemorrhage (Hr) in tissue and degeneration (D) in haematopoietic in renal tissue. (24) Degeneration (D) and necrosis (N) in renal tubules and hemorrhage (Hr) in hematopoietic tissue. (25 and 26) Severe degeneration (D), necrosis (N) with remaining of nuclei, hemorrhage (Hr) and hemolysis (Hs) in renal tissue.

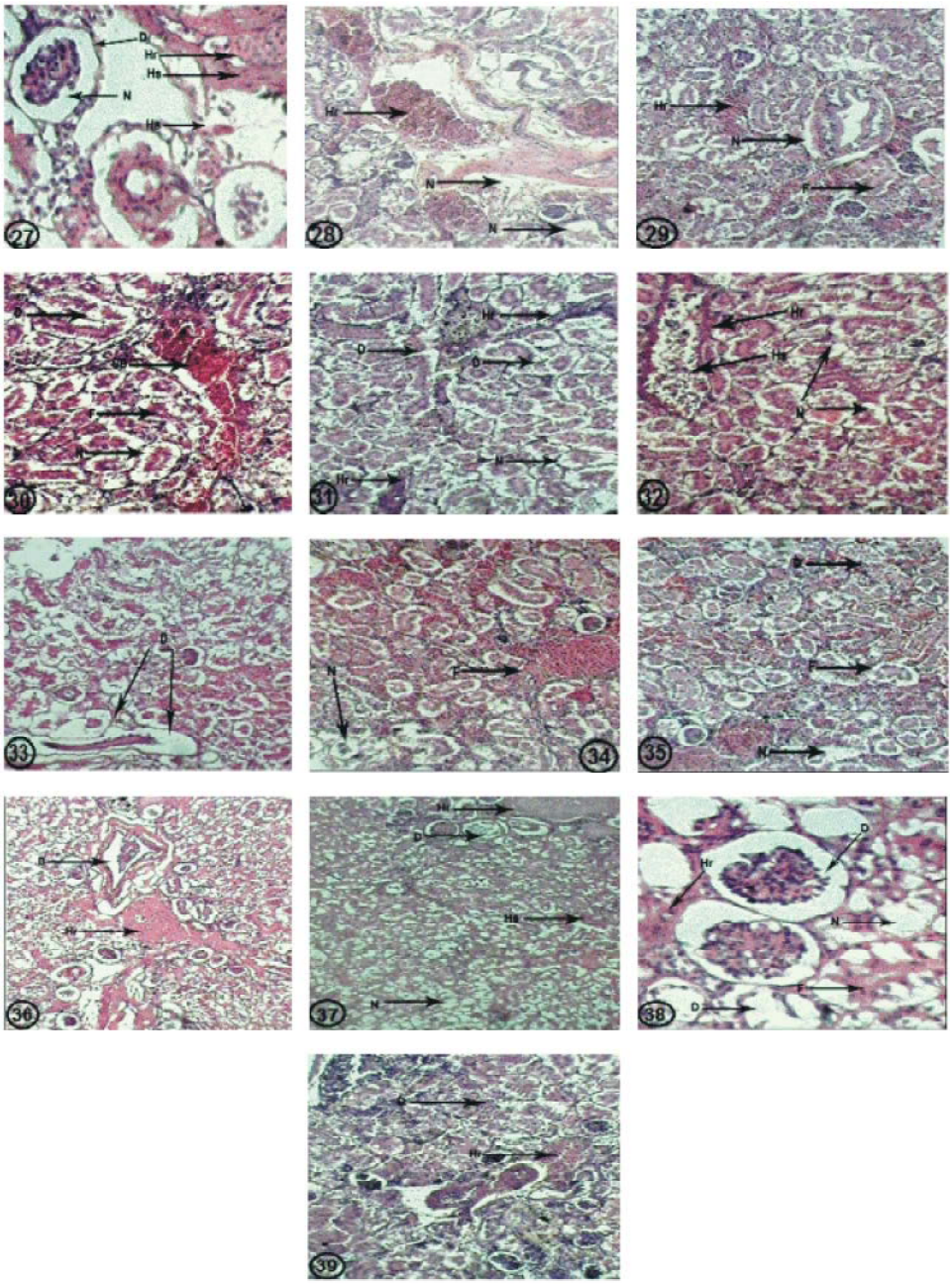

Figs. (27-39): (27) Kidney section of *O. niloticus* fish obtained from Shanawan station showing stagnant blood (SB), fibrosis (F), degeneration (D) and necrosis (N) in renal tissue. (28) Stagnant blood (SB), fibrosis (F), degeneration (D) and necrosis (N) in renal tissue. (29) Degeneration (D), necrosis (N) and hemorrhage (Hr) in renal tubules and Malpighian corpuscles. (30 and 31) Necrosis (N) in renal tubules, hemorrhage (Hr) and hemolysis (Hs) in hematopoietic tissue. (32 and 33) Fibrosis (F) and necrosis (N) with remaining of cytoplasm and nuclei. (34) Kidney section of *O. niloticus* fish obtained from Tamalay station showing severe hemorrhage (Hr) in hematopoietic tissue and degeneration (D) in renal tubules. (35) Hemorrhage (Hr) and hemolysis (Hs) in hematopoietic tissue, degeneration (D) and necrosis (N) in renal tubules and malpighian corpuscles. (36 and 37) Hemorrhage (Hr) in renal tubules and malpighian corpuscles, necrosis (N) and degeneration (D) in renal tubule. (38 and 39) Severe degeneration (D), necrosis (N) and hemorrhage (Hr) in renal tissue, renal tubules and malpighian corpuscles.

However, kidney samples collected from Shanawan station suffered from stagnant blood (Sb) (Fig. 28), fibrosis (Figs. 28, 32, 33), degeneration (D) (Figs. 28, 29, 33), necrosis (N) (Figs. 28, 29, 30, 31, 32, 33), hemorrhage (Hr) (Figs. 29, 30) and hemolysis (Hs) (Fig. 30). At Tamalay station fish kidney suffered from hemorrhage (Figs. 34, 35, 36, 37, 39), degeneration (Figs. 34, 35, 36, 37, 38, 39), hemolysis (Fig. 35), necrosis (Figs. 35, 36, 38, 39) and fibrosis (Fig. 36).

In present study, kidneys were found to be most affected by changes in water quality. This may be due to the fact that it is one of the principal sites of detoxification in fish body.

DISCUSSION

Physical Parameters

Air and Water Temperature: Temperature is a critical control parameter in aquatic system and it is a key parameter which influences the physical, chemical and biological transformation in the aquatic environment [19].

The changes of water temperature may depend on the variation in meterological condition, time of sampling, air temperature, back radiation and latent heat of evaporation as recorded by Awad [20], Al-Afify [21] and Mahmoud *et al.* [22].

Transparency: It is controlled by depth and turbidity of the water and is affected by particulate content of the river water of suspended matter and floating substances [23]. Also, it is influenced by abundance of phytoplankton and zooplankton in water column. The decrease in transparency at Shanawan station may be due to sewage and domestic wastes. The present results agree with that obtained by Mahmoud *et al.* [22] and Ahmed [24].

Electrical Conductivity: According to APHA [17], electrical conductivity is a measure of the ability of aqueous solution to carry an electric current. This ability depends on the presence of ions, their total concentration, mobility, valance and temperature of the medium. Solutions of most inorganic compounds are relatively good conductors. Conversely, molecules of organic compounds that don't dissociate in aqueous solution conduct current very poorly. Thus, the more abundant the ions, the higher is the conductivity and vice versa. In the present study, the higher values of EC may be attributed to the presence of domestic and agricultural wastes discharged containing high amount of inorganic constitutes [21].

Chemical Parameters

pH value: The pH of natural water affects biological and chemical reactions, controls the solubility of metal ions and affects natural aquatic life. For aquatic life the desirable pH value for freshwater is in the range of 6.5-9.0. In the present study, the measured pH values for freshwater are within the desirable range reported by Mahmoud *et al.* [22] and Chin [25].

Carbonate and Bicarbonate Alkalinity: Certain freshwater fish species affected by more alkaline conditions. Strong alkalis in certain polluting effluents probably produce asphyxiation by the coagulation of gill secretions [26]. The highest alkalinity may be attributed to the lower dissolved oxygen content of studied water. The lower oxygen content is indicative of higher content of (CO_3) and hence greater solubility of $CaCO_3$. The change in alkalinity is analogous to variation in calcium content of water [26, 27].

Total Dissolved Solids: Total dissolved solids (TS) are very useful parameter describing the chemical constituents of the water and can be considered as a general parameter measure of edaphic relationships that contribute to productivity within the body of water [28]. The high value of TS in this study especially at Shanawan station may be attributed to discharge of domestic and agricultural wastes in this branch [21].

Dissolved Oxygen: Dissolved oxygen is very important factor to the aquatic organisms, because it affects their biological processes, respiration and oxidation of the organic matter in water. It is one of the most important water quality characteristic in the aquatic environment.

The depletion in dissolved oxygen at Shanawan may be due to agriculture and sewage runoff. While at Kafr El-Zyat may be due to industrial wastes. However at Tamalay may be due to agricultural wastes. These results agree with that obtained by Mahmoud *et al*. [22] and Tayel [29], who revealed that depletion to decomposition of suspended organic matter of sewage wastes.

Chloride Content: Chloride ion is an essential element for the photosynthesis process, photolysis of water releasing oxygen, ATP formation and for certain phosphorylation reactions [30]. The increasing in chloride content at Kafr El-Zyat station resulting from the influence of the industrial wastes and increase in agricultural runoff to the Rosetta branch [31] and also may be due to sewage which contain human urine as a result of sodium chloride which widely used in human diet [32].

Ammonia, Nitrite and Nitrate: Dissolved inorganic nitrogen is the summation of the ammonia, nitrite and nitrate. Ammonia is considered one of the most important parameters that must be studied in pollution of water ecosystem [33]. The term ammonia includes the non-ionized (NH_3) and ionized (NH_4) species. The increase in the concentration of ammonium ions (NH_4^+) have no effect on the aquatic organisms or fish [34]. So, ammonia in water is an indicator of possible bacterial, sewage and animal waste pollution. Natural levels in ground and surface water are usually below 0.2 mg/L [35].

Ammonia toxicity causes osmoregulatory imbalance kidney failure and suppressed excretion of endogenous ammonia, resulting in neurological and cytological failure. The increase in concentration of ammonia in the present study results in agreement with Mahmoud *et al.* [22], Tayel [29] and Ali [36].

Nitrites play an important role in the nitrogen cycle of aquatic environment because it is the intermediate oxidation state between ammonia and nitrate [37], its oxidation produce nitrate while its reduction produces ammonia. The higher values of nitrite in the present study may be attributed to phytoplankton resulting of organic and inorganic fertilizers [38]. The European Economic Community standard shows a maximum admissible limit of nitrite as 100 µg/L.

Nitrate provide an interesting as polluting under special circumstances and their presence in river water can arise from sewage effluents, drainage from agricultural land drained with artificial nitrogenous fertilizers and effluent from certain industries [27]. This increase of nitrate in present study may be attributed to agricultural and sewage effluents as recorded by Mahmoud *et al.* [22] and Tayel [26].

Histological Studies: Histology has been used as a test for evaluating toxic effects of water pollutants on fish [39]. Results from the histological studies are useful in establishing water quality criteria [40].

The fish gill is a multifunctional organ involved in respiration and homeostatic activities such as osmoregulation, metabolism, circulation of hormones nitrogen excretion and acid base balance [41]. They are among the most delicate structures of the teleost body and they have an external location so they are subjected to damage by irritant whether dissolved or suspended in the water. External irritant are the most frequent causes of significant gill pathological changes [42].

The filament consists of primary and secondary lamellae. The secondary lamellae include branchial epithelium consisting of a layer of one or two cells of interdigitating squamous epithelial cells. Also, mucous secreting cells and chloride cells are found scattered between the lamellae [43].

Gill hyperplasia may increase epithelial thickness, so as to prevent the entry of toxic ions into the blood stream. These cellular proliferations in respiratory lamellar epithelium may lead to great disturbance of gas exchange and ion regulation for osmoregulation performed by the gills [44].

Gill lamellar telangiectasis is primarily caused by disruption of pillar cells, capillary distension occurs and blood accumulation may lead to further fibrosis [45].

These results are similar to those obtained by Yacoub [46], Ibrahim and Tayel [47] and Yacoub *et al.* [48], who revealed these results to change of water quality as a results to industrial, agricultural and sewage wastes.

Capkin *et al*. [49] found necrotic areas scattered throughout the hematopoietic tissue and renal tubules of the rainbow trout as result of changes in water quality such as increase in pH, temperature, alkalinity and hardness.

The histopathological changes that observed in kidney of the selected species which were collected from the three studied area as a result of water quality changes recorded in the present study and by many earlier authors [22, 50-52].

Exposure to unionized ammonia caused pathological alternations in renal tubules of trout kidney [53]. Kadry *et al*. [54] found injuries in kidney tissue of *Liza ramada* fish obtained from water polluted with industrial and agricultural wastes in Lake Manzalah. The kidney injuries included degeneration and necrosis of renal tubules and malpighian corpuscles.

Finally, it can be concluded that the pollution along the River Nile induces toxic tensions in gill and kidney of *O. niloticus*, i.e., altering their fine structure and affecting their functions. It is recommended to treat the waste water before it has been discharged into the River Nile to protect the aquatic animals and humans from dangers of pollution.

REFERENCES

1. El-Shayeb, M., 1996. Evaluation of the Nile Raw Water. Proceedings of the 6th International Conference: Environmental Protection is A Must, Alexandria, Egypt, pp: 122-127.
2. Zyadah, M., 1997. A study on levels of some heavy metals in River Nile Estuary Damietta Branch, Egypt. Journal of the Egyptian German Society of Zoology, 23(A): 149-160.

3. Salah El-Deen, M.A., H.K. Zaghloul, G.O. El-Naggar and S. Abo-Hegab, 1999. Concentrations of heavy metals in water, sediment and fish in the River Nile in the industrial area of Helwan. Egyptian Journal of Zoology, 32: 373-395.
4. Balasundaram, C., 2001. Histopathological screening of the tissues of the finish and shellfish harvested from the Valaichennai and Morgottanchemai Lagoon. Sri Lanka 6th Asian Fisheries Forum Book of Abstracts, Unit. A, Mayaman Townhomes 25 Mayaman St. Village, Quezan City, Philippinean Asian Fisheries Society 2001, pp: 20.
5. Zaghloul, K.H., M.I. Hanna and M.M. Zaki, 2007b. Assessment and control of nitrite toxicity in *Clarias gariepinus*. Egyptian Journal of Aquatic Biology and Fisheries, 11(3): 1047-1068.
6. Moralee, R.D., F.H. Vander Bank and B.C.W. Vander Waal, 2000. Biochemical genetic markers to identify hybrids between the endemic *Oreochromis mossambicus* and alien species, *O. niloticus* Pisces: Cichlidae. Water S.A., 26(2): 263-268.
7. Pullin, R.S.V., 1997. Characterization of Ghaniam Tilapia genetic resources of use in fisheries and aquaculture. In: R.S.V. Pullin, C.M.V. Casal, E.K. Abban and T.M. Fack (Eds.), ICLARM Conference Proceedings, pp: 52-55.
8. Salama, E.S.N., 1995. Histopathological, histochemical and electron microscopic studies on a sewage polluted freshwater fish. Ph.D. Thesis, Zoology Department, Faculty of Science, Zagazig University, Egypt.
9. Zaghloul, K.H., W.S. Hasheesh, I.A. Zahran and M.A.S. Marie, 2007a. Ecological and biological studies on the Nile tilapia; *Oreochromis niloticus* along different sites of Lake Burullus. Egyptian Journal of Aquatic Biology and Fisheries, 11(3): 57-88.
10. Randall, D.J., S.F. Perry and T.A. Heming, 1982. Gas Transfer and acid base regulation in salmonids. Comparative Biochemistry and Physiology, 73(B): 93-103.
11. Auperin, B., F. Rentier-Deltue, T.A. Martial and P. Prunet, 1994. Characterization of a single prolactin (PRL) receptor in tilapia (*Oreochromis niloticus*) which binds both PRLI and PRL II. Journal of Molecular Endocrinology, 13(3): 241-251.
12. Evans, D.H., 2002. Cell signaling and ion transport across the fish gill epithelium. Journal of Experimental Zoology, 293(3): 336-347.
13. Haswell, M.S., D.J. Kandall and S.F. Perry, 1980. Fish gill carbonic anhydrous: Acid-base regulation or salt transport. American Journal of Physiology, 238(R2): 40-50.
14. Munshi, J.S.D. and G.M. Hughes, 1991. Structure of respiratory islets of accessory respiratory organs and their relationship with the gills in the climbing perch, *Anobas testudineus* (Teleostei, Perciformes), Journal of Morphology, 209: 241-256.
15. Dutta, H.M., J.S.V. Munchi, P.K. Roy, S. Singh and J. Killius, 1996. Ultrastructural changes in the respiratory lamellae of the catfish, *Heteropneustes fossilis* after sublethal exposure to Malathion. Environmental Pollution, 92(3): 329-341.
16. Leeson, T.S., C.R. Leeson and A.A. Paparo, 1988. Text/Atlas of histology. W.B. Saunders Co. Philadelphia, USA, pp: 15-18.
17. APHA, 1995. Standard Methods for the Examination of Water and Wastewater, American Public Health Association, New York, pp: 1193.
18. Bucke, D., 1972. Some Histological techniques applicable to fish tissues. In: L.E. Mawdesley-Thomas, (ed), Diseases of fish, Symposium of Zoology Society, London, Academic Press New York, No., 30: 153-189.
19. Delince, G., 1992. The Ecology of fish pond Ecosystem with special reference to Africa. Textbook, Kluwer Academic Publications, Kluwer, pp: 230.
20. Awad, F.K., 1993. Distribution of some trace elements in the River Nile from Isna to El-Kanater, Egypt. M.Sc. Thesis, Faculty of Science, Alexandria University, Egypt.
21. Al-Afify, A.D.G., 2006. Biochemical studies on River Nile pollution. M.Sc. Thesis, Faculty of Agriculture, Cairo University, Egypt.
22. Mahmoud, S.A., S.I. Tayel and A.M. Yacoub, 2008. Histopathological changes in kidneys of the fish *Tilapia zillii* and *Clarias gariepinus* under the effect of several pollutants along the River Nile. Journal of the Egyptian German Society of Zoology, 56(C): 219-246.
23. Talling, J.F., 1976. Water characteristics in the Nile biology of an ancient river. (J. Rzoska, ed.), Junk Publisher, The Hague, pp: 357-384.
24. Ahmed, N.A.M., 2007. Effect of River Nile Pollution on *Clarias gariepinus* located between El-Kanater El-Khyria and Helwan. M.Sc. Thesis, Faculty of Agriculture, Zagazig University, Egypt, pp: 223.
25. Chin, D.A., 2000. Water Resources Engineering. Prentice Hall Inc. Upper Saddle River, New Jersey, pp: 585-635.

26. Tayel, S.I.M., 2003. Histopathological, biochemical and hematological studies on *Tilapia zillii* and *Clarias gariepinus* in relation to water quality criteria at different localities in Delta Barrage. Ph.D. Thesis, Faculty of Science, Benha branch, Zagazig University, Egypt.
27. Siliem, T.A.E., 1984. Chemical studies on pollution in the Damietta Nile branch between Faraskour Dam and Ras El Bar Outlet. Ph.D. Thesis, Faculty of Science, Alexandria University, Egypt, pp: 253.
28. Sayed, M.F., 2003. Chemical studies on pollution in Rosetta branch of River Nile between Kafr El-Zayat and Rosetta outlet. Ph.D. Thesis, Faculty of Science, Cairo University, Egypt.
29. Tayel, S.I.M., 2007. Histopathological and biochemical seasonal changes of *Oreochromis niloticus* in relation to water quality at Zefta and El Mansoura Cities, Damietta branch River Nile, Egypt. Journal of Egyptian Academic Society for Environmental Development, 8(2): 81-92.
30. Oser, B.L., 1979. Hawk's physiological chemistry. 14ed, Tata McHill Publishing Company Ltd., New Delhi.
31. Elewa, A.A. and M.H. Ali, 1999. Studies of some physicochemical conditions of River Nile at Damietta branch. Bulletin of Faculty of Science, Zagazig University, Egypt, 21(2): 89-113.
32. Jordao, C.P., M.G. Pereiral, C.R. Bellato, J.L. Pereira and A.T. Matos, 2002. Assessment of water systems for contaminants from domestic and industrial sewages. Environmental Monitoring and Assessment, 79: 75-100.
33. Emerson, K., R.C. Russo, R.E. Lund and R.V. Thurston, 1975. Aqueous ammonia equilibrium calculations: Effects of pH and temperature. Journal of the Fisheries Research Board of Canada, 32: 2379-2383.
34. Siliem, T.A.E., 1993. Impact of drainage water on the water quality of Qarun Saline Lake: 1-Environmental salts. Bulletin of Faculty of Science, Zagazig University, Egypt, 15(2): 122-146.
35. WHO, 1993. Guidelines for drinking water quality. 2nd ed. Contents: VI. Recommendations WHO Library Cataloguing in publication Data, Genera, pp: 1-129.
36. Ali, M.H.H., 1998. Chemical and physical studies on the River Nile at Damietta branch region. M.Sc. Thesis, Faculty of Science, Menofiya University, Egypt.
37. Ebeid, M.H., 1993. Study of some heavy metals and micro constituents in fresh and saline waters. M.Sc. Thesis, Faculty of Science, Alexandria University, Egypt.
38. Sayed, M.F., 1998. Evaluation of pollution on *Mugil* species in Damietta branch between Faraskour Barrage and Ras El Bar Outlet. M.Sc. Thesis, Faculty of Science, Helwan University, Cairo, Egypt.
39. EIFA, 1983. Working party on toxic testing procedures, revised report on fish toxicity testing procedures. EIFAC Technical paper, 24: 1-37.
40. FAO, 1981. Manual de metodos de investigation media ambients accatico, part 4: bases para la eleccion de ensagas biologices para evaluar la contaminaccion arina-FAO. Documentois tocnicos de pesca, 164: 1-31.
41. Haaparanta, A., E.T. Voltomen and R.W. Haffman, 1997. Gill anomalies of perch and roach from lakes differing in water quality. Journal of Fish Biology, 50: 575-591.
42. Zaki, M.I. and S.G. Saad, 1987. Pathological changes in different species and embryological stages of fish induced by urea fertilizer waste water. Bulletin of Institute of Oceanography and Fisheries ARE, 13(1): 43-57.
43. Groman, G.B., 1982. Histology of the striped bass. American Fisheries Society Monograph, 3: 166.
44. Yacoub, A.M., 2003. Study of histopathological changes in the gills of *Oreochromis niloticus* from Lake Manzala due to water pollution. Egyptian Journal of Aquatic Biology and Fisheries, 7(2): 71-86.
45. Robert, R.J., 1981. Patalogica de los peces. Editional Mundi-Prensa, Madrid.
46. Yacoub, A.M., 2004. Histopathological effects of accumulated heavy metals and macronutrients on the gills of some fish species from Bardawil Lagoon. Journal of Egyptian Academic Society of Environmental Development, (D-Environmental studies), 5(1): 111-143.
47. Ibrahim, S.A. and S.I. Tayel, 2005. Effect of heavy metals on gills of *Tilapia zillii* inhabiting the River Nile water (Domietta Branch) and El-Rahawy Drain. Egyptian Journal of Aquatic Biology and Fisheries, 9(2): 111-129.
48. Yacoub, A.M., S.A. Mahmoud and S.I. Tayel, 2008. Health status of *Oreochromis niloticus* in fish farm irrigate with drainage water in El-Fayoum province, Egypt. Egyptian Journal of Aquatic Research, 34(1): 161-175.
49. Capkin, E., I. Altinok and S. Karahan, 2006. Water quality and fish size affect toxicity of endosulfan, an organochlorine pesticide, to rainbow trout. Chemosphere, 64: 1793-1800.

50. Yacoub, A.M., 2002. Effect of industrial wastes in River Nile on the ultrastructure of the kidney of *Clarias gariepinus*. Egyptian Journal of Aquatic Biology and Fisheries, 6(4): 183-201.
51. Mabrouk, D.R., 2004. Aspects of Manzalah Lake Pollution on *Mugil* Species, M.Sc. Thesis, Faculty of Girls, Ain Shams University, Egypt, pp: 293.
52. Ayas, Z., G. Ekmekci, M. Ozmen and S.V. Yarli, 2007. Histopathological changes in the livers and kidneys of fish in Sariyar Reservoir, Turkey, Environmental Toxicology and Pharmacology, 23: 242-249.
53. Schmidt, H., D. Bernet, T. Wahli, W. Meier and P. Burkhardt-Holm, 1999. Active biomonitoring with brown trout in diluted sewage plant effluents. Journal of Fish Biology, 54: 585-596.
54. Kadry, S.H.M., A.M. Yacoub, T.A. Siliem and D.B. Mabrouk, 2003. Injuries in kidney tissue of the mugil *Liza ramada* as a biomarker for environmental pollution in the lake Manzalah. Egyptian Journal of Aquatic Biology and Fisheries, 7(3): 1-24.