World Applied Sciences Journal 25 (9): 1302-1307, 2013
ISSN 1818-4952

DOI: 10.5829/idosi.wasj.2013.25.09.13425

Histological and Histochemical Study of Submandibular Salivary Glands of Two Species of *Insectivores*

[1]*M. Zh. Bazarbayeva,* [1]*Zura Yessimsiitova,* [2]*L.S. Kozhamzharova and* [3]*K. Zh. Seitbayev*

[1]Department of Biodiversity and Bioresources, Al-Faraby Kazakh National University, 050038 Almaty, Kazakhstan, Faculty of Biology and Biotechnology
[2]Department of Biology, Faculty of Water Resources, Environment and Construction, Taraz State University named after M.Kh. Dulaty, Taraz, Kazakhstan
[3]Department of Biology-Geography, Tarazky Innovative and Humanities University, Kazakhstan, Faculty of Naturally Knowledge-Jurisprudence

Submitted: Sep 24, 2013; **Accepted:** Oct 27, 2013; **Published:** Oct 30, 2013

Abstract: The histological structure of the submandibular salivary glands of the Tien Shan shrew-Sorex asper Thomas and eared hedgehog-Erinaceus auritus Gmelin has been studied for the first time. Submandibular salivary gland of these animals is not an independent body like the in case of majority of other mammals and lie in the same connective tissue capsule with sublingual gland.Submandibular salivary glands of studied representatives of the species Insectivora are complex alveolar-tubular glands with acini and duct system that includes the intercalated, striated and interlobular ducts. The acini of shrew contain one type of cell that produces serous secret, while the acini of hedgehog are composed of two types of cells: simple and complex. The study revealed the unusual fact: that the simple acini of the hedgehog were mucous; while it is known that usually the simple acini of mammals are serous. *This* is previously unknown fact, as it is known from classical histology that central large mucosal cells and Dzhianutsi demilunes always have a serous nature. Thus, the two species belonging to the same type had different histological structure of acini that can be explained by their size, habitat and the type of nutrition.

Key words: Insectivora · Salivary · Glands

INTRODUCTION

It is widely acknowledged that the salivary glands are important multifunctional organ in the body and perform many functions: digestive, protective, excretory, endocrine [1, 2]. Despite the fact that numerous studies on the salivary glands have been published, comparative morphology of these organs in different species of animals still remains underresearched. The majority of studies and tests are carried out on laboratory animals and human [3, 4]. The information on glands of other of mammals is sketchy, not systematic and is not reflected in the relevant manuals and materials [5-8].

These underresearched animals include members of the species Insectivores. Insectivores are the most ancient and primitive of all placental animals. It is quite possible that the ancestors of Insectivores were ancestors of all other placental. Small and very small animals constitute the majority of the order. The salivary glands of two species of insectivorous: Tien Shan shrew-*Sorex asper Thomas* and eared hedgehog-*Erinaceus auritus Gmelin* have been studied.

Shrew is a very small animal (weighing 5-10g). Shrew eats insects, small invertebrates, less plant seeds. Shrew eats several times a day and usually sleeps between meals. Eared hedgehog is a bit larger animal (weighing more than 500g), prefers the beetles, ants, sometimes eat frogs, lizards and small birds. Eared hedgehog usually hunts late at night [9].

Corresponding Author: M. Zh. Bazarbayeva, Kazakh National University named after al-Farabi, Department of Biodiversity and Bioresources. Al-Farabi av. 71 Almaty, Kazakhstan.

MATERIALS AND METHODS

The research was carried out in the histological laboratory of Kazakh National University named after al-Farabi. For histological examination the submandibular salivary glands of five specimen the Tien Shan shrew-*Sorex asper Thomas* and five specimen of the eared hedgehog-*Erinaceus auritus Gmelin* were fixed in 10% neutral formalin.Fixed pieces after washing and dewatering were embedded in paraffin. 5-7 microns thick Paraffin sections were dyed with hematoxylin-eosin. The results were statistically processed and tabulated.

The detection of common proteins was carried out by Daniel histochemical reaction with bromophenol blue, PAS-positive substances were detected using McManus and Hotchkiss method.To determine glikozoaminoglikans (acid mucopolysaccharides) Stidmen reaction with alcian blue was used by authors [10]. The reviewing and photographing the histological preparations were performed at the light microscope Leica DMLS with a digital camera Leica DFS 280.

RESULTS AND DISCUSSION

The study of the morphology of the organ showed that the submandibular salivary glands of the Tien Shan shrew and the eared hedgehog-are the paired organs that lie in the front of the neck on the either side of the middle line and border with each other in the medial part. Each of both glands was oval in shape and laid in a single connective tissue capsule with sublingual gland.

From lateral side the submandibular glands were adjacent to the sublingual glands, while from the cranial edge they were adjacent to the lymph nodes.

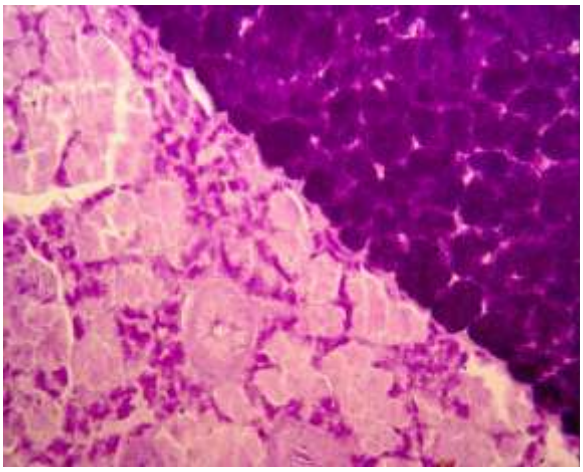

Fig. 1: The boundary between the submandibular and sublingual glands (the submandibularon the left, the sublingual gland on the right) PAS - reaction. SW. × 200

On the outside the entire complex was covered by common connective tissue sheath. The right and left submandibular glands were completely symmetrical and could have been easily separated from each other, as connective tissue layer separated them. At the same time, each of the paired submandibular glands was more tightly coupled to the corresponding sublingual gland and a layer of connective tissue between them was very thin. PAS- response clearly shows the boundary between these two glands due to a more intense color of sublingual gland, which contains more mucosal components than the submandibular gland (Fig. 1)

Histological examination revealed that the submandibular salivary glands of insectivorous are complex, branched, tubular-alveolar glands.

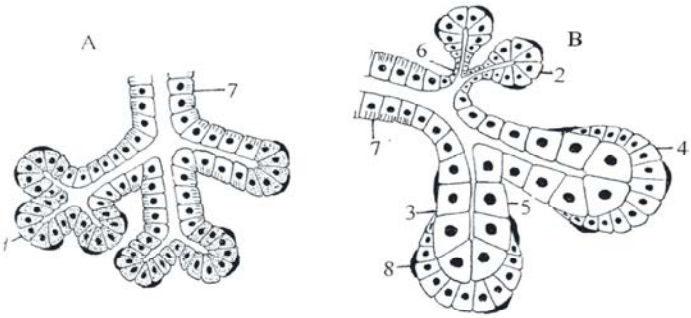

Fig. 2: The structure lobules of the submandibular salivary glands of insectivorous
A – the lobe of submandibular salivary gland of Tien Shan shrew;
B – the lobe of submandibular salivary gland of eared hedgehog
1- the simple seromucous acinus; 2- simple mucous acinus; 3- complex acinus; 4- mucosal demilunar; 5- seromucous central cells; 6- intercalated parts; 7- striated ducts; 8- myoepithelial cells;

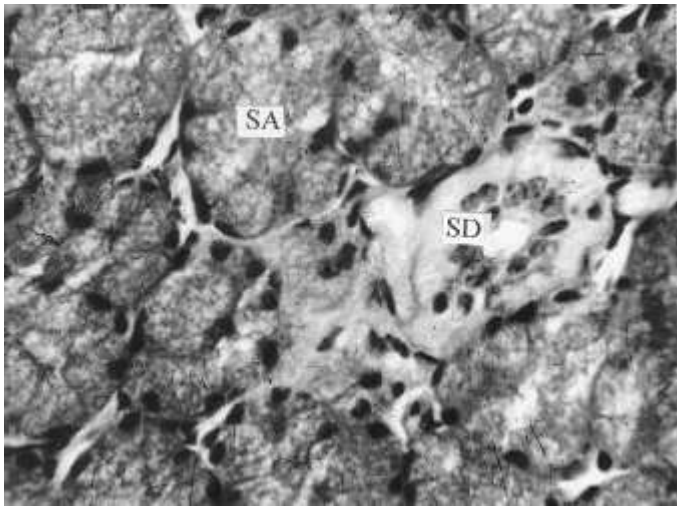

Fig. 3: Histostructure submandibular salivary gland of the Tien Shan shrew.
SA – simple acini, SD –striated ducts. Staining with hematoxylin and eosin. 300 x

Table 1: Diameters of acini and ducts in the submandibular salivary glands of mammals

Mammals	Diameter of simple acini, mkm	Diameter of complex acini, mkm	Diameter of striated ducts, mkm
Tien Shan shrew	20.01 ± 0.87	–	24.18 ± 1.02
Eared hedgehog	28.84 ± 1.14	56.00± 1.21	43.96±2.01

Very thin layers of connective membrane covering the organ from the outside went into gland parenchyma, dividing it into lobules. The gland parenchyma constituted by secretory parts or acini and a system of ducts.

The structure of the submandibular salivary gland of shrew included simple acini and striated ducts (Fig. 2, 3). We called acini simple, because they were formed by one type of cells.

The nuclei of acinar cells were round and were located centrally or slightly shifted into the basal part of the cell. Cytoplasm of the acini cells was basophilic. The average diameter of acini was (20.01 0.87) mkm (Table 1). Lumen of the acini in sections was not visible.

Histochemical studies have shown that the simple acini of shrew were stained for aggregateprotein and PAS-reaction. Reaction to acid mucopolysaccharides (glycosoaminoglycanes) with Alcian blue was negative. Consequently, simple acini of shrew were seromucous and contained mainly proteins and neutral mucopolysaccharides in its secretion.

Streaked and interlobular ducts presented duct system of a shrew. Intercalated ducts were absent. Cubic cells with inconspicuous basal striation formed striated ducts. Interlobular ducts were formed by cubic cells and are often contained secretion.

The ends of secretory units of submandibular salivary gland of the eared hedgehogs had a more complicated structure than the shrew. The study has revealed two types of acini: simple and complex (Fig. 3). Moreover in some part simple acini in the others complex acini prevailed. However more often they were mixed with no patterns (Fig. 4). On hematoxylin-eosin preparations, simple acini were spherical or ovoid form and were formed by a single cell type. The cytoplasm of these cells was intensely colored and granular, while it was eosinophilic in the apical part of cells and slightly basophilic in the basel part. Round nuclei with very apparent nucleoli were shifted to the base of the cell. Acini lumen was not visible. Myoepithelial cells with flattened nuclei presented the outer layer of acini. The average diameter of simple acini was (28.84 + 1.14) mkm (Table 1).

Complex acini of the submandibular salivary glands of the hedgehog are larger than simple. The diameter of complex acini was (56.0 + 1.2) mkm. Cells of two types formed them: large acidophilic cells lying at the center and small cells, forming a half moon on the outside of the acinus. Thus, the small cells were located on the large central cell groups. The slices of cells had the form of "cap" or demilunes, covering the acinus. On the top complex end a single layer of myoepithelial cells covered parts as well as the simple ones.

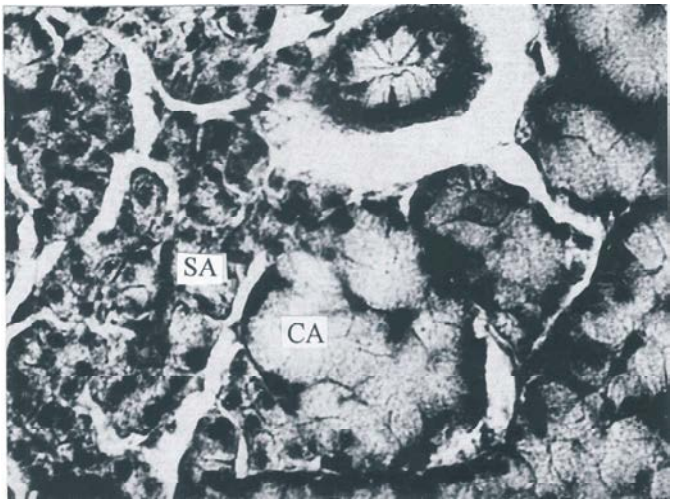

Fig. 4: The Histostructure submandibular salivary gland of the eared hedgehog. Visible small simple acini - SA and large complex acini - CA. Staining with hematoxylin-eosin.

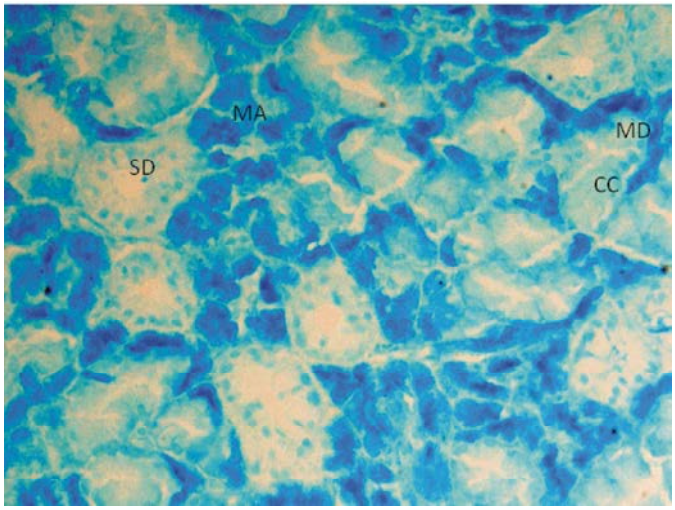

Fig. 5: The histochemical reaction to glycosoaminoglycanes in the submandibular salivary gland of the eared hedgehog. The glycosoaminoglycanes in simple mucosal acini - MA and mucosal demilunar - MD stained in bright blue. The central cells (CC) of the complex acini and striated duct (SD) cells are not stained. Colouring by alcian blue and hematoxylin.

The similar description of histostructure of the submandibular salivary glands of cats and dogs are given in different studies [1, 11]. While comparing the morphology of the submandibular salivary glands of hedgehog and predators we could have made a false conclusion about the great similarity in the structure of the submandibular salivary glands, if we had limited ourselves to the histological description only. However, histochemical study has shown that simple acini cells and semilunar cells were identical in nature of secretion produced and belonged to mucosal cell type, as they intensely coloured alcian blue and gave a pronounced PAS-reaction (Fig. 5, 6). In contrast, the central large acini cells in alcian blue were not dyed, but gave a weak PAS-reaction and a more intense color on the proteins. Thus, complex acini in the submandibular salivary glands of the hedgehog consisted of central large serous cells and mucosal demilunes, while as it is known from the literature [1] the central large cells of the other animals (carnivores, artiodactyls, human) are purely mucous and demilunes are serous.

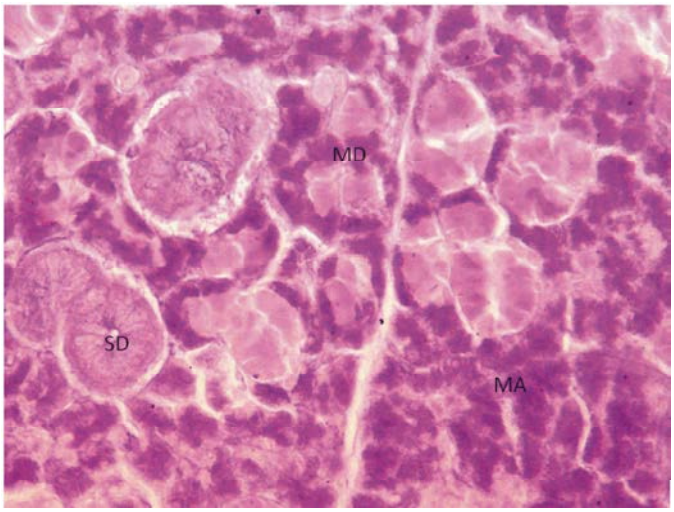

Fig. 6: Histochemical reaction to neutral mucopolysaccharides in the submandibular salivary gland of the eared hedgehog

We have found only one study in the literature pointing to such uncharacteristic mammalian structure when serous acini of submandibular salivary glands were covered outside by mucosal demines. It was study of round-eared bats Tonatia sylvicola [12]. The author reports that the large salivary glands in different species of bats have differences in structure and histochemistry even when closely related species are considered. The research also indicates that their teeth, tongue and digestive tract are highly variable and connected to the eating habits.

To our knowledge as far as submandibular salivary glands of the hedgehog are concerned there is no evidence in the literature that describes their unusual histostructure. To our knowledge there are no descriptions of differences we have found in the structure of the submandibular salivary glands between the Tien Shan shrews and eared hedgehog of two members of species of Insectivorain the existing literature.

The cells of simple mucosal acini (MA) and mucosal demilunar (MD) complex acini contain many neutral mucopolysaccharides. Striated ducts (SD) weakly stained by PAS. 300 x

In the description of the study we deliberately did not use the term "mixed acinus" that often cause terminological confusion in the literature and used the phrase "complex acinus" instead. Most of histologytextbooks and articles [13, 14, 5] state that mixed acinus produces mixed seromucous secretion, at the same time pointing that the serous component is produced by protein demilunes while slimy is produced by mucosal cells.

At the same time, other authors [1] indicate that the acini of submandibular salivary glands of rats are also mixed as they produce mixed seromucous secretion. But the acini of the rat are "simple" and homogeneous. They do not have two types of cells: "serous" and "mucosal" so all of the cells are seromucous. Thus, analyzing the literature and our own data, we conclude that mixed acini may have one type of cell (rat) or two types of cells (human). As authors [3] indicates the confusion in terminology deepens the complexity of the interconversion and function of secretion cells of submandibular salivary glands [1]. If we replace the notion of a "mixed" acinus, which only indicates that acinus produces mixed seromukozny secretion, but does not specify the differentiation of acinar cells with the terms "complex" and "simple" acini, the confusion with terminology will be solved. For that reason we will be using "complex" and "simple" acini terms.

The Histological examination showed that the submandibular salivary duct system of the hedgehog includes intercalated, striated and interlobular ducts.

Intercalated ducts are rarely met in sections. They were located between simple end parts and streaked canals and consisted of cube-shaped cells. Striated salivary ducts or salivary tubes were clearly visible in sections. They were formed by the oxyphilic cells with striations in the basal part of the cells and had a vesicular, bright nucleus with one or two nucleoli. The apical surface of the cell of the salivary tube was flat, but sometimes-visible swelling was observed. The cavity of duct was clearly expressed. Interlobular ducts had greater diameter than the striated ducts and more well

developed connective tissue capsule. Well-stained on acidic and neutral mucopolysaccharides and less stained on total protein flaky secretion in the lumen of the large ducts was often visible.

CONCLUSION

- Submandibular salivary glands of insectivores are paired organs and lie in front of the neck in a single connective tissue capsule with the sublingual gland and lymph nodes.
- Submandibular salivary glands of shrew and eared hedgehog are complex alveolar-tubular glands with acini and duct system that includes the intercalated, striated and interlobular ducts.
- Our data indicate that the submandibular salivary glands of the Tien Shan shrew and eared hedgehog belong to mix seromucous glands type. In case of a shrew the secretion was produced by simple acini, while in the case of a hedgehog in complex acini two types of cells mucosal and serous could be differentiated, therefore in the secretion of the hedgehog more mucosal substances, particularly glikozoaminoglikanes were found. Such specialized cells, whichare inherent in most of the higher mammals, including human, enables to produce serous and mucous secretion in large quantities.

REFERENCES

1. Babayeva, A.G. and E.A. Shubnikova, 1979. The structure, function and adaptive growth of salivary glands. Moscow University, [In Russian], pp: 556.
2. Miletich, I., 2010. Introduction to salivary glands: structure, function and embryonic development. Front Oral Biol., 14: 1-20.
3. Amano, O., K. Mizobe and K. Sakiyama, 2012. Anatomy and histology of rodent and human major salivary glands. Acta Histochem Cytochem, 45(5): 241-50.
4. Pícoli, L.C., F.J. Dias and I.S. Watanabe, 2011. Ultrastructure of submandibular salivary glands of mouse: TEM and HRSEM observations. Microsc Res Tech, 74(12): 1154-60.
5. Habata, I., T. Yasui and A. Tsukise, 2011. Histochemistry of sialoglycoconjugates in goat submandibular glands. Anat Histol Embryol, 40(3): 187-95.
6. Adnyane, I.K., A.B. Zuki and S. Agungpriyono, 2010. Histological study of the parotid and mandibular glands of barking deer (Muntiacus muntjak) with special reference to the distribution of carbohydrate content. Anat Histol Embryol, 39(6): 516-20.
7. Krause, W.J., 2010 Microscopy of the koala mandibular (submandibular) glands. Anat Histol Embryol, 39(6): 503-8.
8. Mizuno, T., A. McKinnon and H. Amasaki, 2009. Histological structure and distribution of carbonic anhydrase isozymes (CA-I, II, III and VI) in major salivary glands in koalas. Anat Histol Embryol, 38(6): 449-54.
9. Naumov, S.P., 1989. Mammals., [In Russian], 7: 379.
10. Volkova, O.V. and Y.K. Yeletskii, 1982. The Fundamentals of histology and histological techniques. Moscow: Medicine. [In Russian], pp: 659.
11. Suzuki, S., N. Hayao and O. Junichi, 1981. Fine structure of the bovine mandibular gland. Mem. Fac. Agr. Kadoshima Univ., 17(26): 147-155.
12. Nagato, T., B. Tandler and J.P. Carleton, 1984. Unusual smooth endoplasmic reticulum in submandibular acinar cells of the male round-eared bat, Tonatia SylvicolaUltrastruct Res., 87(3): 275-284.
13. Afanasiev, Y.I., N.A. Yurina and E.F. Kotovcky, 2002. Histology, cytology and embriology. Moscow: Medicine, [In Russian], pp: 744.
14. Hem, A. and D. Kormak, 1983. Histology. Vol 2. Moscow: Mir., pp: 458.