World Applied Sciences Journal 13 (3): 431-437, 2011
ISSN 1818-4952


# Study on Ovarian Follicle Ultra Structure and Rhythm of Gonad Development in (*Rutilus frisii kutum*) from Caspian Sea

[1]*Shafiei Sabet Saeed,* [2]*Mohamad Reza Imanpoor,*
[1]*Aminian Fatideh Bagher and* [1]*Gorgin Saeed*

[1]Department of Fisheries, Golestan, Gorgan University of Agricultural Sciences and Natural Resources, Iran
[2]Guilan, Fishing Technology Department,
Mirza Koochak Vocation and Higher Education Center for Fisheries Sciences and Technology

**Abstract:** The ultra structure of the ovarian follicle and changes occurring in the gonad were studied during cortical alveoli, vitellogenesis and oocyte maturation in of female Kutum, (*Rutilus frisii kutum*) were conducted in Bandar-e-Kiashahr in Southwestern of Caspian Sea from November 2007 to April 2008. The microvilli began to form on the oocyte surface during cortical alveoli phase and during vitellogenesis, came into contact in the pore canals of the zona radiata with microvilli formed from granulosa cells. While the special thecal cells posses specific organelles, which are characteristic of steroid-producing cells, namely, mitochondria with tubular cristae, smooth endoplasmic reticulum and lipid droplets, the granulosa cells contain organelles typical for protein-secreting cells. No abnormalities or pathological changes in the ovarian or body of the investigated fish were detected. The aims of this study were to confirm the timing, frequency and duration of the spawning period, monitor changes in the gonado-somatic index (GSI), relate (GSI) the histological characteristics of the ovaries and describe the stages of Kutum oocyte and ovarian development. Gonadal samples were taken monthly from the females stained with HandE stain and studied by light microscope. Different stages of oocyte development (nucleus changes, oocyte diameter and forming of yolk vesicle, yolk granules and lipid droplets) were then surveyed. This study showed that gonadosomatic index (GSI) began to increase in March and reached the highest value (29.47±4.2) in April and then decreased sharply in early may. According to these results, ovarian development in the *Rutilus frisii kutum* is synchronous. Spawning occurred once a year in February- April.

**Key words:** Microstructure · Histology · Ovaries · Rutilus frisii kutum · Badar-e-kiashahr · Sefid-rood

## INTRODUCTION

Currently, studies on the histology of many biological phenomena such as fish reproduction to invent new and effective methods for increasing efficiency of broodstock, increasing fish production, increase efficiency and higher fish are predicted. Determination of the peak period of spawning assessment and exploitation of fish, understanding the biological characteristics and life cycle of a species also supply management and reconstructions are important roles [1, 2]. Kutum species are economic and native of the Caspian Sea. The highest distribution is in the south west coast of the Caspian Sea [3, 4]. In Iranian coast, gathering and scattering of the fish heavily depend on physical conditions such as temperature, flows and marine food supply [5]. As the histological science being young, except a few cases, comprehensive studies regarding to ovarian histology of kutum is considerable to determine the independence of sexual, especially in the south west coast of the Caspian Sea. In some teleosts, histochemical and ultra structural studies have shown that the special thecal cells are cellular sources of the sex steroids during the vitellogenesis and oocyte maturation [6-9]. In this research, images of ovarian tissue levels of performance ovulation and reproductive pattern of kutum of the

**Corresponding Author:** Shafiei Sabet Saeed, Department of Fisheries, Golestan, Gorgan University of Agricultural Sciences and Natural Resources, Iran.
Tel: +98-9111447909, Fax: +98-1313382354, E-mail: saeed_fisheries@yahoo.com.

Caspian Sea Power intensify have been provided. Generally, ovaries of the bony fish in the bag as containing the channel exit duct and fish eggs of the bony fish are come comes in a single channel. Conduit between the outlet and cavity eggs on the outside leads to urinary tract. Among various fishes, course structure in the ovary is different. Common Carp family fish ovary has a pair of symmetrical, as tight to the bag shape, membrane bag and swimming bladder (Ceolomic) [10]. Ovarian tissue graft wall, smooth muscle cells, formation of oocytes and the internal wall surface of the dilatation of ovarian germinal pages are known to be produced [11]. Studies about the physiological action performances indicated that the caracteristics and behavior of uniform environmental conditions are comply with fish [12]. Especially the timing, frequency and spawning duration, growth and fecundity rate, size and age depend to the environment [13]. Therefore, changing the environmental conditions, many fish for adaptation to new situations and stability in the generation of the necessary reactions show that the reaction to this collection with latter time changes in different tissues of the body and limbs, including the ovaries is the cause. Since the complexity of most biological problems to obtain oocytes and oocytes for the required artificial amplification and is difined manufacturing processes more oocytes consider the knowledge of biology and ovarian development is especially important. Therefore, this study investigated growth and ovarian development of kutum in the Caspian Sea area through Bandar-e-Kiashahr. Studies on the histology are able to provide the necessary and appropriate strategies for optimum utilization and maintain supplies of this valuable species harvested step. In the present study, it was aimed to clarify ultra structural features of the follicles in the cortical alveoli, vitellogenesis and maturation phases

## MATERIALS AND METHODS

This study was conducted on the number of kutum with number 64 in linear groups – with different age. Fish sampling started at the same time (15/11/2007) south-west coast of the Caspian Sea started in Bandar-e-Kiashahr, this catching performed until (15/4/2008). Samples were prepared from market and also after month cooperation with the patrol unit to protect local and marine resources fishing. We selected Sefid-Roud River to collect samples and record broodstock biometrical data status of Kutum. Quantitative indices with precision 1 mm, 0.01 g and 1 g, evaluation, registration forms and booklet were recorded. Samples in specific small-scale special compartment specific studied were kept for laboratory studies like determination of age. Weight factors, including weight of fish samples and case filling empty abdomen were determined with scale sartorious with 1 gram accuracy and gonad weight were determined with a digital scale, model Acculab.V-200 (0.01 g) [14]. Fish with various maturating stages were collected from the sea and river in different seasons and the length and weight of the collected fresh fish were then measured. The bodies of fish ovaries were carefully weighed and were then registered. Number of oocytes counted in each warm with oocytes available in one to two grams of the ovary is attached [15]. All oocytes were found in different size [16].

**Gonadic Index or Relationship Gonadosomatic GSI:**
$GSI = WG / WT \times 100$

Weight of gonad = WG, WT= total weight of fish, [16].

For measuring abdominal empty weight of total body weight after registering gonad and intestinal contents out and weighting was done.

$$WE = TW\text{-}O_{I\ and\ G}$$

Where WE= abdominal weight empty, TW= total body weight, $O_{I\ and\ G}$= gonad and intestinal contents

Determination of fish age was down through samples taken from the scales between the scales available in the lateral line and dorsal side. Find the circle-shaped scales (Cycloid) number 5 to 10 from the area generally between dorsal and lateral line. Collected scales the following two left eye and find Nikon 40x and 20x by counting rings twilight age were determined [16].

**Histological Study Methods:** To evaluate the changes that are necessary, fish ovaries as new tour with blades or net mesh (vetch), Sheyl or Kulham. Gonad cached and has been forthright and fish out the body and kept in physiological serum solution. Several gonads cut in each step of investigation were performed in each sample. Counting the number of oocytes at different stages is usually investigated (ovugony, raw eggs, pitted eggs, eggs with yolk and the eggs are done Atretic [17]. Gonad for tissue sampling sectors was cut from beginning, middle and end. After sampling of gonads (from the beginning, median and end), histological study was done in International Institute of Biochemistry in sturgeon - Rasht, making clear, Paraffin be, Impression, cutting, coloring Hematoxilin and Eosin (H and E) and by Monte

and password were ultimately to Find histological analysis by optical microscope image of the samples was done. Sampling gonads divided based on six-stage method according to appearance and size oocyte. Follicular layer, cell wall, vacuoles, nuclear and Nucleolus stage diagnosis were then investigated [18]. Egg diameter, using binuclear scaled, so that some spawning any fish in any repeat was on and put binuclear under was reading the numbers. It most be noted that the number of 10 randomly eggs of ovaries available on lam select and average egg diameter for each repetition of the samples was then calculated. All data were analyzed by using the Excel program and SPSS Vr. 11.05. For statistical methods we used one-way ANOVA and Tukey test (T. Student).

## RESULTS

According to the results of the present study, tissue sections in three areas elementary, middle and end ovarian Kutum, there was no significant difference in the frequency of oocytes ($p>0.01$). Investigations with regard to the stages of growth and independence ovarian kutum can be divided into six parts including: first stage (stage Nucleolus Chromatin), the second stage (stage Nucleolus side), the third stage (stage vesicles yolk), fourth step (step seeds yolk), the fifth stage (maturity stage) and stage six (stage eggs found), as described in table 1. Minimum and maximum diameter of oocytes was 0/19 ±2 /81 to 0/23±3/48 mm and 2/14± 19/52 to 1/49 ± 22/38 mm respectively.

**The Cortical Alveoli Phase:** The ovary of mature *Rutilus frisii kutum* contains oocytes in different stages of development. The spawning occurs during February-April. After ovulation, oocytes that will be ovulated next year develop from cortical alveoli. This phase is marked by the appearance of the cortical alveoli in the cytoplasma (Figure 4). The lipid droplets accumulate in the cytoplasm until December. In this phase the oocytes are still covered with one layer of follicle cells.

**The Vitellogenenic Phase:** The yolk globules appear in the peripheral cytoplasm between the lipit droplets and soon after fill in oocyte cytoplasm. With the growth of the oocyte, zona radiata (ZR) increases in thickness (Figure 5). The zona radiata consists of an outer (ZE) and an inner layer (ZI). However, the ZE begins to develop with the appearance of cortical alveoli (Figures 4).

Table 1: Macroscopic investigation (Kestiven, [35]) and histological classification and description of the ovarian maturity stages in Kutum from the Caspian Sea.

| Macroscopic description | Histological description | Stage |
|---|---|---|
| Sex organs very small and near the spinal column, ovaries transparent grayish color, eggs inenarrable eye disarm | Find great in the center of the core oocyte and low value ovuoplasm, Nucleolus. Several small nuclear and related disciplines Nucleolus Chromatin is highly basophile cytoplasm is dark blue in color. Oocyte Protoplasm side is growing, Chromatin material is visible inside the oocyte, Nucleolus to many small size and proximity internal layer nuclear membrane are put and vacuoles thin layer around the core made up of follicular intensity has decreased basophile oocyte. | Immature |
| Ovaries semi-transparent, gray, half or slightly more than half the abdominal length of enclosure, with a single particle between eggs visible, fish have spawning (in rest) in this class are put | Vesicles, yolk oocyte increased in size, around a few core vesicles row is visible, follicular cells and increased thickness of layers formed radius, amount acidosis ovuoplasm increased finds. | Early stage of maturing |
| ovaries, partial capillary blood red and occupies half the yard abdomen, eggs and armed non-eye visible as are scabrous | Nucleolus scattered in various parts of the core and the number decreases, making the last stage of vacuoles reached, increased follicular layer and two layers of granulosa cell layer Theca radius is more specific. Acidophilic oocytes are completely. | Late stage of maturing |
| Sex organs courtyard filled a eggs completely round and some are semi-transparent and has eggs of the current low pressure, semi-transparent eggs with some more egg on the outside are | More eggs and gonad mature oocytes and their diameter increased, yolk accumulation found objects, with vacuoles also merged and formed a large vacuoles gives Intake oocytes and nuclear migration toward the animal pole we. Layer around the ovarian follicular developed. | Mature |
| Ovaries soften and Eggs depleted completely abdominal landscaping are discharged | Fish eggs found in their oocytes, Ron amount of ovarian follicles and oocytes non-empty view is normal. Immature oocytes in this stage are visible. | Spent |

Table 2: Evaluation of some indices whitefish weight (gr).

| Standard Deviation | Average | Maximum | Minimum | Factor |
|---|---|---|---|---|
| 128.36299 | 256.6425 | 654 | 23 | Gonad weight |
| 447.334 | 916.68 | 2141 | 280 | Stomach empty weight |
| 546.982 | 1175.78 | 2498 | 449 | Total body weight |



(A) (B)

Fig. 1: Oocyte in the A - stage I (of nucleus chromatin) $20_X$ and $40_X$. B- Stage II (nucleus and side) $20_X$ and $40_X$. EandH staining

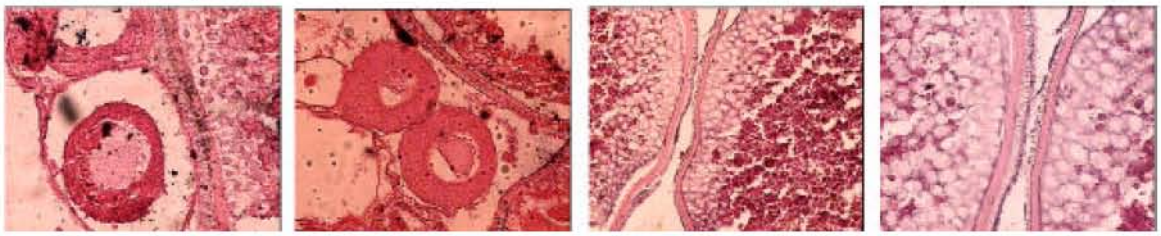

(A) (B)

Fig. 2: A- Oocyte in- Stage III (Vesicles yolk) $20_X$. B- Stage IV (yolk grains) $20_X$. EandH staining.

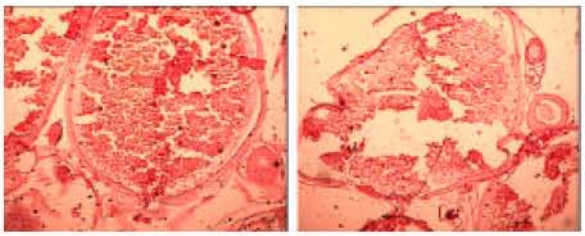

(A) (B)

Fig. 3: A- Oocytes in Stage V (mature). B - Stage VI (eggs found or spawned). EandH stained.


Fig. 4: Light micrograph of an oocyte in the cortical alveoli phase from 5 µm cross section in *Rutilus frisii kutum*. Lipid droplets (L) are present under the (ZR): zona radiata. GV: germinal vesicle. 70x.

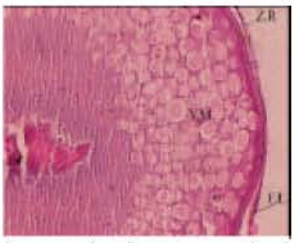


Fig. 5: Light micrograph of an oocyte in the vitellogenic phase from 5 µm cross section in *Rutilus frisii kutum*. YM: yolk material; ZR: zona radiata; FL: follicular layer. $480_X$.

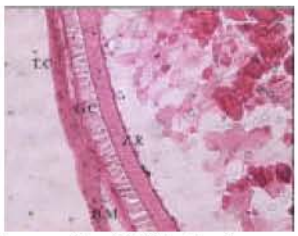

Fig. 6: Light micrograph of follicular layers and oocyte in the maturation phase from 5 µm cross section *R. frisii kutum*. ZR: zona radiata; GC: granulosa cell; TL: thecal layer; O: ooplasm. 525x.

With the accumulation of yolk globules, lamellar ZI begins to form. The ZE appears electron-dense and compact. The ovarian follicule is composed of two main cell layers: an inner granulosa layer and an outer thecal layer. These layers are separated by thick basement membrane (Figure 5). The thecal layer is composed of theca

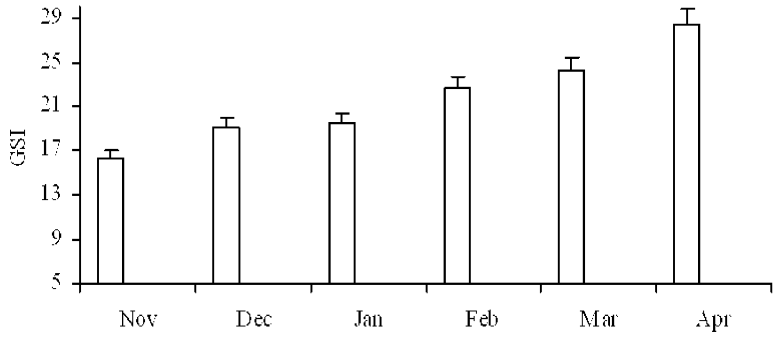


Fig. 7: Trend of average values Gonadosomatic index (GSI) in the Caspian Sea Kutum within separately month.

externaand theca interna cells. A small number of special thecal (ST) cells in thecal interna can be separated easily. These cells are larger than the ordinary thecal cells and contain a centrally located nucleus. The polysome, relatively less well-developedrough endoplasmic reticulum and the Golgi complex appear in the cytoplasm. A single layer of flattened granulosa cells surrounds the oocytes. They have a centrally located and flattened nucleus with occasionally invaginated outline. One prominent nucleolus was found. The specialized connections between the granulosa cells appeared. A small amount of smooth endoplasmic reticulum and free ribosome and a lot of mitocondria were also present throughout the cytoplasm.

**Maturation Phase:** This phase continued for about one month. During the egg maturation, granular structure of material changed, the granules were united and germinal vesicle migration started. The thickness of the granulosa and theca layers increased and the ZR became more opaque (Figure 4 and 5).

Generally, process of gradual changes in gonadosomatic index (GSI) kutum during sampling showed that (GSI) from February was gradually increase during the March and April month which demonstrated after the value of GSI be suddenly dropped.

## DISCUSSION

Wide studies about structural changes in ovarian morphology in fish tissue and bone during ovugensis process were done by different researchers [12]. Seasonal changes of ovarian tissue in red mullet *Mulets surmuletus* from southern coast of the UK [19], reproductive cycle and time of the annual reproductive Sea bass on Ovarian Morphology and Histology [20], Histological study and development stages fish ovarian bester sturgeon [21], macroscopic and microscopic stages of ovarian development in white sturgeon *Acipenser transmuntanus* [22] and the independence of sexual sludge process based on fish *Tinca tinca* Histology [23]. Ovarian development in the *Rutilus frisii kutum* is synchronous. Spawning occurred once a year in February- April. In this species, the microvilli began to form on the oocyte surface in cortical alveoli phase as [6,24] indicated a close contact between microvilli processes of the granulosa cells and oocyte surface was maintained only during vitellogenesis. Therefore, in C. tarichi, the transport of the yolk material to oocyte is probably via these pore channels by diffusion and active transport at the molecular level and by endocytosis as suggested by [4,21]. It is generally known that chorion is formed either by the oocyte itself or both the oocyte and the follicle cells. Our study showed that two types of fish bone spawning strategy are entitled. The first is seen in more fish trout and salmon that they are kind spawning (Synchronous) it means that oocyte pending a specified period of time or it located outside the ovary, while fish such as fish stokehold spawning (Asynchronous) many have activities during different times of their reproductive and spawning. Another research showed that postoperative spawning of fish sexual stage VI to stage II, which will open in stages, is attributed back. Viewpoints [16] microscopic diagnosis Gonad is the best and most reliable way to determine gender and diagnosis of early stage of investigating sexual addition for stage II and VI studies distinction Histology of ovarian exact path. Like other researches in this kind of stage I (Chromatin Nucleolus Find) large nuclear ovucyte center and the amount is minimal ovuplasm, stage II (Nucleolus side) protoplasm oocyte is growing and nucleolus small size near the walls are put in domestic nuclear membrane [7]. At the stage III (vesicles Find yolk), oocyte size is increased [25], at the stage IV (seeds yolk) Nucleolus scattered in various parts of the and their number decreased, at the stage V (mature) vacuoles merged and vacuoles are and they migrate to animal pole. Stage VI (eggs found) amount of empty follicles and immature oocytes can find. Histological

ovarian follicles in the structure of Kutum with the results obtained in thisinvestigation were similar to other bony fish. In this study, changes in (GSI) Kutum had a significant increase on January, February witch showed a peak of in March and April and then in mid-April to June months (GSI) suddenly dropped. Diameter distribution in the oocytes during the sampling period was significant and the highest diameter of oocytes were observed in March and April and in the months April to June, diameter of oocytes reduced. A diameter change of fish oocyte probably is an important strategy in determining reproductive activities and their proliferation [26]. The most important factors of growth and maturation in bony fish are environmental factors including light, air and water temperature, salinity, water and etc. Among these, a series of conditions on the appropriate axis hypothalamus, pituitary and Gonad (HPG) effect the activation of this axis of growth and development of oocyte 27,28]. Since fish mainly with patterns and reproductive behavior or scheduled to study the process of ovarian development and maturation stages of the studies investigating sexual Histology and Morphology of Endocrine and sexual ovaries be pending. So changes in the building level Morphology and structure of ovarian oocyte referrals can be index and good in different stages of maturity in this species and other valuable fish species [29]. A histology microscopic view of the whole ovary and trend curve changes (GSI) were shown in Figure 4 which demonstrates this oocyte cleaning spawning short-term periods are abandoned. Therefore, Kutum in terms of how spawning division [30] or group spawning suddenly Total Spawned oocytes and maturity in terms of division [31] that some ovarian component species they are discharged during a period (Synchronous). Usually set the evolution of this species of fish oocyte is clear and consists of two parts yolk were made [32]. It is necessary to declare in some oocyte that ovaries may be small at the same time that this index spawning because some small fish oocyte after ovarian spawning is the remaining gradually absorbed [33]. Most important economic fish are spawning yearly and can be spawned with short reproductive season [34] However numbers of stages of sexual development of fish have close relationship with the water temperature, salinity and physical-chemical factors of the environment. Numbers of stages of reproductive development are achieved through the making cuts ovarian tissue section and the study and the process can be including the oocyte diameter growth, ultimately to the exact pattern, time spawning and spawning Power range of fish species.

## ACKNOWLEDGMENT

Hereby authors hierarchy Acknowledgment their sincere cooperation scientific consulting Dr Sarpanah, Sharif pour, Shabani, Shabanpoor, sudagar, Ghorbani, Hosseini, Salman Mahini, Aslan Parviz and Mr. Kazemi, Halajyan, Sadeghi, Jalali and other respected colleagues in the laboratory diagnosis for medical staff pathology Sadeghi clinic, Astaneh Ashrafiyeh, respected ichthyology laboratory sufferer and Higher Education Center for Science and Fisheries technology, we expressed Mirza Koochak Khan Rasht. Here we also greatly thank of Mr. Selseleh in a series of prepared samples broodstock.

## REFERENCES

1 Eigdery, Q., 1381. Histology study materials growth genital sex find hermaphrodite fish sauce over large *Barbus capito*. M.Sc. Thesis fisheries. Tehran University. Faculty of Natural Reso., pp: 96.

2 Hosseinzadeh Sahafi, H., M. Soltani and F. Dadvar, 1380. Reproductive biology and fish Shirbatt *Silago sihama* in the Persian Gulf. J. Fisheries. 1. Tenth year. Spring, 1380: 37-54.

3 Azari Takami, A.H., B. Razavi Sayad and N. Hosseinpour, 1369. Review of artificial propagation and breeding fish in white *Rutilis frisii kutum*. J. Veterinary Medicine, Tehran University, 45: 52-45.

4 Selman, K. and R.A. Wallace, 1986. Gametogenesis in Fundulus heteroclitus. Am. Zool., 26: 173-192.

5 Ghaninezhad, D., 1384. Assessment of reserves in the Caspian Sea Bony fish, pp: 82-80. Fisheries Research Institute of Iran, Tehran, pp: 169.

6 Matsuyama, M., Y. Nagahama and S. Matsuyama, 1991. Observations on ovarian follicle ultrastructure in the marine teleost, *Pagrus major*, during vitellogenesis and oocyte maturation. Aquac., 92: 67-82.

7. Nagahama, Y., 1983. The functional morphology of teleost gonad. In: Fish physiology (WJ Hoar, DJ Randall, EM Donaldson, Eds), Academic press, NY, USA, 9: 223- 264.

8. Nagahama, Y., K. Chan and W.S. Hoar, 1976. Histochemistry and ultrastructure of pre-and post-ovulatory follicles in the ovary of the goldfish, *Carassius auratus*. Can. J. Zool., 54: 1128-1139.

9. Nagahama, Y., H. Kagawa and G. Young, 1982. Cellular sources of sex steroids in teleost gonads. Can. J. Fish Aquat. Sci., 39: 56- 64.

10 Vossoughi, Y. and B. Mosatajir, 1367. Freshwater fishes. Tehran University Publications, pp: 317. 71, 72, 227 and 228 .

11. Oryan, S.H., 1376. Fish physiology. Tarbiat Modarres University Noor., pp: 80.

12 Trosov, V.Z., 1964. Institute of International Research of Khaviar. 205, 310.

13 Smith, B.B. and K.F. Walker, 2004. Spawning dynamics of common carp in the River Murray, South Australia, shown by macroscopic and histological staging of gonads. J. Fish Biol., 64: 336-354.

14 Deriso, R.B., 1980. Harvesting strategies and parameter estimation for and age-structured model. Canadian J. Fisheries and Aquatic Sci., 37: 174-8.

15 Aminian, B., 1385. Selectivity broodstock kutum (*Rutilus frisii kutum*) in the southern Caspian Sea, using indices of sexual investigation. Dissertation fishery. University of Agricultural Sciences and Natural Resources Gorgan. pp: 120.

16 Biswas, S.P., 1993. Manual of method in fish biology. South Asian Publisher Put. Ltd., pp: 145.

17 Poosti, A. and A. Sadegh Marvdasti, 1996. Compurgation histology and histotechique. Tehran University press, First Edition, pp: 480.

18 Rinchard, J. and P. Kestemont, 1996. Comparative study of reproductive biology in single and multiple spawned cyprinid fish. Morphological and Histological features. J. Fish Biol., 49: 173-265.

19 Deniel, C. and K. Nda, 1993. Sexual cycle and seasonal changes in the ovary of Red Mullet *Mullus surmuletus* from the southern coast of Brittany. J. Fish Biol., 43(2): 229-244.

20 Guiguen, Y., C. Cauty, A. Fostier, J. Fuchs and B. Jalabert, 1993. Reproductive cycle and sex inversion of the Sea Bass, *Lates calcalifer*, reared in sea cage French Polynesia, histological and morphometric description. Envir. Biol. Fishes. 39: 231-247.

21 Mojazi Amiri, M. Maebayashi, A. Hara, S. Adachi and K. Yamauchi, 1996. Ovarian development and serum sex steroid and vitellogenin profiles in the female cultured sturgeon hybrid the Bester. J. Fish Biol., 48: 1164-1178.

22 Doroshov, S.I., G.P. Moberg and J.P. Venennam, 1997. Observation on the reproduction cycle of cultured white sturgeon, *Acipenser transmuntanus*. Envir. Biol. of Fishes. 48: 265-278.

23 Pimpicka, E. and A. Tkacz, 1997. Course of oogenesis in juvenile tench, *Tinca tinca*, female from Lake Dgal Wielki Neopoland, Folia Zoological., 46(2): 177-187.

24 Takashima, F. and T. Hibiya, 1995. An Atlas of Fish Histology. Gustav Fischer Verlag, pp: 129-150.

25. Yusefiyan, M., S.H. Oryan, F. Farrokhi and H. Sayyan, 1382. Study of growth in fish oocytes mullet thin beak *Liza saliens* Risso, J. Fisheries, 1: 131-152.

26 Tomasini, J.A., D. Coolart and J.P. Quignard, 1996. Female reproduction biology of the sand smelt in brackish lagoons of southern France. J. Fish Boil., 46: 94-612.

27 Faridpak, F., 1365. Fish proliferation and executive instructions hydrothermal. Fisheries course of study in Tehran University. pp: 310.

28 Matty, A.J., 1985. Fish endocryology, Croom. Helm., 13: 473.

29 Tyler, C.R. and J.P. Smpter, 1996. Rev. Fish. Bio., 6, 287.

30 Prabhu, M.S., 1956. Maturation of intra-ovarian eggs and spawning periodicities in some fishes. Indian J. Fisheries, pp: 56-90.

31 Marza, V.D., 1938. Histophysiologies Del ovogenes. Herman, Paris, France. pp: 81.

32 Rinchard, J. P. Kesteven and R. Heine, 1997. Comparative study of reproductive biology in single and multiple spawner cyprinid fish. 11. J. Fish. Biol., 50: 169-180.

33 Nicolsky, G.V., 1963. The ecology of fisher. Academic Press, pp: 350.

34 Pitcher, T.J. and P.J.B. Hart, 1996. Fishery's Ecology. Chapman and Hall, pp: 414.

35 Kestiven, G.L., 1960. Manual of field methods in fisheries biology. FAO man. Fish. Sci., pp: 152.