

First Report of *Hystrichis* in Eurasian Otter (*Lutra lutra*) from Iran

¹M.R. Youssefi, ²S.H. Hosseini and ³B. Esfandiari

¹Department of Veterinary Parasitology, Islamic Azad University Babol - Branch, Iran

²Department of Veterinary Parasitology, Faculty of Veterinary Medicine,
University of Tehran, Tehran, Iran

³Pasteur Institute of Iran-Amol Research Center, Iran

Abstract: The Eurasian otter is a semi aquatic territorial carnivore which feeds mainly on aquatic prey and whose habitat is usually linked to the existence of relatively clean fresh water. The otter's worldwide distribution has shown a sharp decline in the last decades. A 2.5-year-old male Eurasian otter (*Lutra lutra*) of 5.0 kg body weight after dying in a road accident was examined for endoparasites of digestive tract by the means of screening (Mesh 70). The specimens were fixed and preserved in 70 % ethanol and lactophenol. *Hystrichis* spp was isolated from this Eurasian otter. Most researches were based on indirect observations such as surveys of spraint (faeces). Information gained from researches using otters which were found dead, forms an important contribution to increase our knowledge about parasites of this animal.

Key words: Eurasian otter % *Lutra* % Endoparasite % *Hystrichis*

INTRODUCTION

The Eurasian otter is a semi aquatic territorial carnivore which feeds mainly on aquatic prey and whose habitat is usually linked to the existence of relatively clean freshwater, available shelter (riparian vegetation, rocky structures and others) and abundant prey [1]. The otter's worldwide distribution has shown a sharp decline in the last decades. Although a general recovery has been noted in recent years [2]. The species conservation status has justified its inclusion in the List of Rare and Threatened Mammals of the Council of Europe, in Appendix II of the Berne Convention, in Appendices II and IV of the Habitat Directive of the European Union, in Appendix I of the CITES and in the 2000 IUCN Red List of Threatened Species, whereas it is classified as vulnerable [3]. No helminthes were previously reported from Eurasian otters in Iran. Aim of this article is to report the *Hystrichis* spp in Eurasian otters from north of Iran for the first time.

Case Report: A 2.5-year-old male Eurasian otter (*Lutra lutra*) of 5.0 kg body weight died in a road accident, was examined for endoparasites of digestive tract. Present study is based on *Hystrichis* spp, isolated from one road accident-killed Eurasian otter originating from Babolsar, North of Iran in 2009. Killed otter transported to the parasitology laboratory Faculty of Veterinary Medicine,

Babol Azad Islamic University. Digestive tract was examined for endoparasites by the means of screening (Mesh 70). The specimens were fixed and preserved in 70 % ethanol. They were cleared in lactophenol and studied in temporary mounts. For definitive identification samples were sent to Zelatca Dimitrova (Department of Biology, Faculty of Agriculture, Thracian University, Student Campus, 6000 Stara Zagora, Bulgaria). The measurements are in millimeters unless otherwise stated.

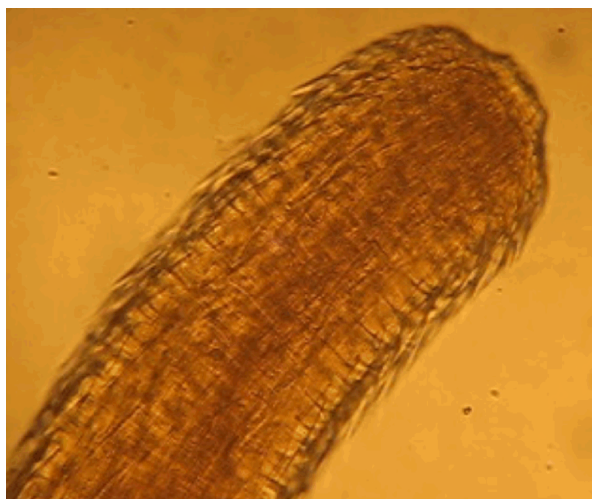


Fig. 1: Head of *Hystrichis* isolated from intestine of *lutra lutra*

Nine helminthes (nematode) were obtained, identified as *Hystrichis*. All of samples measured about 1.5 ± 0.3 cm. The anterior extremity is swollen and bears several rows of small spines. Whole of body were covered with spines. Spines of the trunk ($9.36 \pm 0.4 \mu\text{m}$) were longer than spines around the head ($7.56 \pm 0.3 \mu\text{m}$) of *Hystrichis*.

Although once widespread throughout the world, Eurasian otter underwent a dramatic decline in 20th century, to the point where the species became rare or extinct across much of its former range [1]. Otters are nocturnal, elusive and trap-shy; direct observations are therefore difficult. Most researches were based on indirect observation such as surveys of spraint (faeces). Information gained from research using otters found dead therefore forms an important contribution to our knowledge. Information gained from researches using otters which were found dead, forms an important contribution to increase our knowledge about parasites of this animal. While death of otters in road accidents are clearly undesirable, opportunistic use of such events provides a chance to take observations, measurements, biological specimens or samples which can be of great benefit to ecological researches [4, 6].

Post-mortems examinations were carried out on 341 otters found dead in southwest and southern England from 1996-2003 and on 609 dead otters found in Wales and the rest of England from 1992 to 2003 [1]. Analyses showed that most otters are killed in winter and more males are killed on the roads than females. Most were in excellent condition, though a small number (particularly orphaned or abandoned young) were suffering from infections, ill health or starvation [5, 7].

REFERENCES

1. Chadwick, E.A., 2006. A post mortem study of otters found dead in England and Wales between 1992 and 2003. Environment Agency R & D Technical Report, W1-084.
2. Elliot, K.M., 1983. The otter (*Lutra lutra*) in Spain. Mammal Review, 13: 25-34.
3. Hilton, T.C., 2000. IUCN Red List of Threatened Species. IUCN, Gland, Switzerland and Cambridge, UK.
4. Liles, G. and R. Colley, 2000. Otter *Lutra lutra* road deaths in Wales. Identification of blackspots and establishment of mitigation measures. Report for the Environment Agency Wales, Welsh Water and the Wildlife Trusts Otters and Rivers Project.
5. Liles, G. and R. Colley, 2001. Otter (*Lutra lutra*) road mortalities: a procedure for the implementation of mitigation measures. A report for the Environment Agency Wales.
6. Jefferies, D.J. and H.M. Hanson, 2000. The role of dieldrin in the decline of the otter (*Lutra lutra*) in Britain: the analytical data. In J.W.H. Conroy, P. Yoxon and A.C. Gutleb, (Eds.), Proceedings of the First Otter Toxicology Conference, Skye, Sept International Otter Survival Fund, Broadford, Scotland, pp: 95-143.
7. Torres, J., C. Feliu, J. Fernandez-Moran, J. Ruiz-Olmo, R. Rosoux, M. Santos-Reis, J. Miquel and R. Fons 2004. Helminth parasites of the Eurasian otter *Lutra lutra* in southwest Europe. J Helminthol. Dec., 78(4): 353-9.