

Antioxidant and Hepatorenoprotective Effects of *Thyme vulgaris* Extract in Rats during Aflatoxicosis

¹Mohamed A. Hamzawy, ²Ezzeldeen S.M. El-Denshary,
³Nabila S. Hassan, ⁴Fathia Manaa and ⁵Mosaad A. Abdel-Wahhab

¹Department of Pharmacology and Toxicology, College of Pharmacy,
Misr University for Science and Technology, 6th October City, Egypt

²Department of Pharmacology and Toxicology, Faculty of Pharmacy, Cairo University, Cairo, Egypt

³Pathology Department, National Research Center, Dokki, Cairo, Egypt

⁴Physiology Department, National Research Center, Dokki, Cairo, Egypt

⁵Food Toxicology and Contaminants Department, National Research Center, Dokki, Cairo, Egypt

Abstract: Chronic liver diseases are common worldwide and are characterized by a progressive evolution from steatosis to chronic hepatitis, fibrosis, cirrhosis and hepatocellular carcinoma. The aim of the current study was to evaluate the total phenolic compounds, the antioxidant properties and the hepatorenoprotective potential of thyme vulgaris extract against aflatoxins-induced liver damage. Six groups of male Sprague-Dawley rats were treated for 6 weeks including the control; the group fed AFs-contaminated diet (2.5mg/kg diet); the groups treated orally with thyme extract at low (TE1) and high (TE2) doses (500 and 1000 mg/kg b.w) and the groups treated orally with TE1 and TE2 one week before and during AFs treatment for five weeks. The results showed that the ethanol extract contained higher phenolic compounds and possessed higher DPPH radical scavenging activity than the aqueous extract. Animals fed AFs-contaminated diet showed significant disturbances in serum biochemical parameters, inflammatory cytokines, the histological and histochemical pictures of the liver and kidney accompanied by a significant increase in MDA and a significant decrease in SOD and GPx in liver. Thyme extract succeeded to improve the biochemical parameters, inflammatory cytokines, decreased the oxidative stress and improved the histological pictures in the liver and kidney in rats fed AFs-contaminated diet in a dose dependent manner. It could be concluded that thyme vulgaris extract has potential hepatorenoprotective effects against aflatoxins due to its antioxidant properties and radical scavenging activity.

Key words: Aflatoxins • Thyme Vulgaris • Oxidative Stress • Liver • Kidney

INTRODUCTION

Aflatoxins (AFs), a group of mycotoxins produced by the common fungi *Aspergillus flavus* and *Aspergillus parasiticus*, are established human hepatocarcinogens and well-known hepatocellular carcinoma (HCC) risk factors when present in foodstuffs [1]. A significant association between aflatoxin B₁ (AFB₁) contamination of food and the high frequency of human liver cancer in many developing countries has been established [2]. Several epidemiological studies in areas of high aflatoxin exposure, particularly in Africa, Southern China and

Taiwan [3], have further substantiated this idea. Retrospective evaluation of data from Kenya (low altitude), Thailand and Mozambique shows that the annual liver cancer rates are 2-4, 0-6 and 4-25/ 100,000, respectively [1]. In Egypt, there is a growing incidence of HCC (per 100,000) of 10-120/ 100,000 [4] and HCC is considered the leading cause of death from all other cancer sites [5]. Hospital based studies from Egypt have reported an increase in the relative frequency of all liver-related cancers in Egypt (>95% as HCC), from 4.0% in 1993 to 7.3% in 2003 [6]. Although the maximum permissible level of AFB₁ in foodstuffs is 20 µg/kg [7],

Corresponding Author: Mosaad A. Abdel-Wahhab, Food Toxicology and Contaminants Department,
National Research Center, Dokki, Cairo, Egypt.
Fax: +202-3337-0931, Tel: +202-2283-1943, E-mail: mosaad_abdelwahhab@yahoo.com.

AFB₁ concentrations several times in excess of this level have been reported in common staple foods in many African countries [8].

AFB₁ is classified by the International Agency of Research on Cancer as Group 1 human carcinogen and induced hepatocellular carcinoma [9, 10]. The toxic metabolite AFB₁-8, 9-epoxide results from biotransformation of AFB₁ by liver microsomal enzymes. The toxic effects of aflatoxins mostly arise from the binding of this particular epoxide derivative to DNA [11]. Moreover, exposure to AFs may lead to biological activities, such as oxidative stress, acute toxicity, teratogenicity, mutagenicity and carcinogenicity [12-15].

It has been well documented that drug-metabolizing enzymes (phase-I and phase-II enzymes) and AFB₁-adduct formation can be changed by natural constituents of the diet, nutrients, phytochemicals and xenobiotics [15, 16]. Phenolic phytochemicals are thought to promote optimal health partly via their antioxidant and free radical scavenging effects thereby protecting cellular components against free radical induced damage. But due to their diverse chemical structures, they are likely to possess different antioxidant capacities [17].

Thyme has been commonly used in foods mainly for the flavor, aroma and preservation and also in folk medicine since the ancient Greeks, Egyptians and Romans. The leafy parts of thyme belonging to the Lamiacea family are often added to meat, fish and food products and also used as herbal medicinal products [18]. Evidence based research postulate that thyme possesses numerous biological activities including antispasmodic [19], antimicrobial [20], antioxidant [21] and antifungal [22]. Moreover, thyme extract possess antioxidant activity and inhibits lipid peroxide formation [23]. The aims of the current study were to determine the total phenolic content, the radical scavenging activity of the ethanolic extract of thyme *in vitro* and to evaluate the protective effects of the extract against liver damage in rats fed AFs-contaminated diet.

MATERIALS AND METHODS

Chemicals and Kits: Alanine aminotransferase (ALT), Aspartate aminotransferase (AST), Glutathione peroxidase (GPx) and Superoxide dismutase (SOD) measuring kits were purchased from Randox, (Antrim, UK). Alkaline phosphatase (ALP), Total protein (TP), Albumin and Creatinine measuring kits were purchased from QCA, (AMPOSTA, Spain). Urea was purchased from

Prodia, (Korbach, Germany). Lipid peroxide formation was evaluated as malondialdehyde (MDA) and was purchased from Oxis Research™ Co., (USA). Alpha fetoprotein (AFP) was purchased from Monobind Inc, (Lake Forest, USA). Interleukin-1β (IL-1β) and Tumor Necrosis Factor-alpha (TNF-alpha) were purchased from Orgenium (Helsinki, Finland). All other chemicals were of the highest analytical grade available.

Aflatoxin Preparation: The aflatoxin was produced via fermentation of rice by *Aspergillus parasiticus* NRRL 2999. The fermented rice was autoclaved, dried and ground to a powder and the aflatoxin content was measured by the use of HPLC [24]. The rice powder was incorporated into the basal diet to provide the desired level of 2.5 mg/kg diet. The diet containing the aflatoxins was analyzed and the presence of parent aflatoxins was confirmed and determined as mentioned above.

Plant Material: Thyme (*Thymus Vulgaris*) was purchased from a local market. The plant was identified by the Department of Medicinal Plants, National Research Center and the voucher was kept in the herbarium of NRC.

Preparation of Thyme Extracts: Dried and ground flowers and leaves of thyme (*Thymus Vulgaris*) (50 g) were subjected to extraction with 400 ml of ethanol (95%) or distilled water for 48 hrs. The extracts were filtered and the ethanol extract was concentrated under the reduced pressure of nitrogen and completely evaporated in a vacuum oven at a temperature not exceeding 40 °C [19] until constant weights were obtained for the ethanol extract. The aqueous extract was dried using Freeze Dryer system (Dura-Dry Freeze Dryer, Model PAC-TC-V4; FTS system, Inc., Stone Ridge, NY, USA).

Determination of Total Phenolic Contents: The concentration of phenolics in the extracts was determined using the method of Jayaprakasha and Rao [25]. Estimation of phenolic compounds as catechin equivalents (CE) was carried out using standard curve of catechin [26].

Radical Scavenging Activity (RSA) by 1,1-diphenyl 1-2-picryl Hydrazyl (DPPH) Assay: Crude extracts was dissolved in methanol to obtain a concentration of 200 ppm and 0.2 ml of this solution was completed to 4 ml by MeOH and 1 ml of DPPH (6.09x10⁻⁵ mol/L) solution in the same solvent was then added. The absorption was

monitored after 10 min at 516 nm. The reference sample (Blank) was 1 ml of DPPH solution and 4 ml MeOH. The capacity of antioxidants to quench DPPH radical was determined according to Nogala-Kalucka *et al.* [27] and calculated according to the following equation:

$$\text{RSA \%} = (\text{Absorbance of control sample} - \text{absorbance of extract sample}) / \text{absorbance of control sample} \times 100.$$

Experimental Animals: Three-month old male Sprague Dawley rats (100-150 g) were purchased from Animal House Colony, National Research Centre, Cairo, Egypt. Animals were maintained on standard lab diet (protein: 160.4; fat: 36.3; fiber: 41 g/kg of metabolizable energy 12.08 MJ) and housed in filter-top polycarbonate cages in a room free from any source of chemical contamination, artificially illuminated (12h dark/light cycle) and thermally controlled ($25 \pm 1^\circ\text{C}$) at the Animal House Lab., National Research Centre. After an acclimatization period of 1 week, the animals were divided into six groups (10 rats/group) and all animals received humane care in compliance with the guidelines of the Animal Care and Use Committee of the National Research Center.

Experimental Design: Animals within different treatment groups were treated daily for 6 weeks including the control, the group fed AFs-contaminated diet (2.5 mg/kg diet), the groups treated orally with the low (TE1) and high (TE2) dose of thyme extract (500 and 1000 mg/kg b.w) and the groups pretreated orally with thyme extract at the two tested doses one week before and during AFs treatment for another five weeks. At the end of the treatment period, all animals were fasted for 12 hr and blood samples were collected from the retro-orbital venous plexus from each animal under ether anesthesia. Blood samples were left to clot and the sera were separated using cooling centrifugation at 3000 rpm for 15 min and stored at -20°C until analysis. The sera were used for the determination of ALT and AST, ALP, total protein, albumin, urea, creatinine, AFP, TNF- α and IL-1 β according to the kits instructions.

After collection of blood samples, all animals were killed by cervical dislocation and sample of the liver was weighed (approximately 0.05-0.1 g) and homogenized in phosphate buffer (pH 7.4) to give 20 % w/v homogenate. This homogenate was centrifuged at 1700 rpm at 4°C for 10 min and the supernatant was stored at -70°C until analysis. This supernatant was used for the assessment

of GPx, MDA and SOD according to the kits instructions. Another sample of each liver was removed and placed in 10 % of natural formalin for histological and histochemical studies [28].

Statistical Analysis: All data were statistically analyzed by analysis of variance (ANOVA) using the General Linear Model Procedure of the Statistical Analysis System [29]. The significance of the differences among treatment groups was determined by Waller-Duncan k-ratio [30]. All statements of significance were based on probability of $P \leq 0.05$.

RESULTS

Total Phenolic Content and DPPH Scavenging Activity: The results presented in Table (1) revealed that the yield and the total phenolic content of ethanolic extract of thyme were higher than that obtained from the aqueous extract. Moreover, the DPPH scavenging activity of the ethanolic extract demonstrated higher radical scavenging activity than the aqueous extract. Therefore, the ethanolic extract was used for the biological assay.

The Biological Assay: No animal mortality was observed in any of the groups treated with thyme extract alone at the two tested doses or the groups treated with thyme one week before and during the AFs treatment. The effect of different treatments on body weight changes was depicted in fig (1). Animals fed with AFs-contaminated diet showed a significant decrease of the body weight whereas; animals treated with TE1 or TE2 were comparable to the control. Animals fed AFs-contaminated diet and treated with TE1 or TE2 succeeded to normalize body weight. The results also indicated that animals fed AFs-contaminated diet showed a significant decrease in food intake. Animals treated with TE1 showed insignificant decrease in food intake however; those treated with TE2 were comparable to the control. The administration of TE1 or TE2 one week before and during AFs treatment resulted in a significant improvement in food intake. This improvement was more pronounced in the group treated with TE2 (Fig. 2).

The effects of different treatments on serum biochemical parameter were depicted in table (2). The results indicated that animals fed with AFs-contaminated diet alone showed a significant increase in serum ALT, AST, ALP, urea, creatinine and AFP accompanied with a significant decrease in total protein and albumin.

Table 1: Yield, total phenolic compounds and DPPH radical scavenging activity of the ethanol and aqueous extracts of *Thyme vulgaris*

Extract Parameter	Ethanol extract	Aqueous extract
Yield (g/100 g plant)	19.49 ± 0.47	21.85 ± 0.48
Total phenolic compounds (µg/g)	413.33 ± 3.34	403 ± 3.34
DPPH radical scavenging activity (%)	72.33	51.30

Table 2: Effect of ethanol extract of *Thyme* on serum biochemical parameters.

Group Parameter	Control	AFs	TE1	TE2	TE1+ AFs	TE2+ AFs
AST (U/ml)	246.40 ± 2.42 ^a	335.20 ± 5.37 ^d	239.0 ± 12.28 ^b	240.60 ± 6.42 ^a	303.2 ± 3.38 ^c	264.76 ± 2.43 ^a
ALT (U/ml)	77.40 ± 1.75 ^a	129.60 ± 3.93 ^c	72.6 ± 3.17 ^a	75.32 ± 3.75 ^a	105.0 ± 4.95 ^b	87.64 ± 2.43 ^a
ALP (U/L)	103.45 ± 5.01 ^a	193.70 ± 6.26 ^b	103.93 ± 4.14 ^a	102.54 ± 4.34 ^a	139.91 ± 4.24 ^c	113.94 ± 3.42 ^d
TP (mg/dl)	10.85 ± 1.24 ^a	4.64 ± 0.26 ^b	10.13 ± 0.66 ^a	10.83 ± 1.23 ^a	8.92 ± 0.28 ^c	9.98 ± 0.73 ^c
Albumin (mg/dl)	3.23 ± 0.19 ^a	1.67 ± 0.11 ^b	3.12 ± 0.09 ^a	3.32 ± 0.21 ^a	2.47 ± 0.16 ^c	3.12 ± 0.21 ^a
Urea (mg/dl)	1.47 ± 0.12 ^a	2.76 ± 0.35 ^b	1.60 ± 0.14 ^a	1.81 ± 0.22 ^a	1.49 ± 0.10 ^a	1.42 ± 0.21 ^a
Creatinine (mg/dl)	0.71 ± 0.11 ^a	2.54 ± 0.11 ^b	0.74 ± 0.14 ^a	0.72 ± 0.12 ^a	1.94 ± 0.02 ^c	0.93 ± 0.04 ^d
AFP (ng/ml)	1.63 ± 0.09 ^a	3.87 ± 0.17 ^b	1.54 ± 0.05 ^a	1.33 ± 0.04 ^a	2.23 ± 0.11 ^c	1.53 ± 0.21 ^a

Within the row, means superscripts with different letters are significantly different at $p \leq 0.05$.

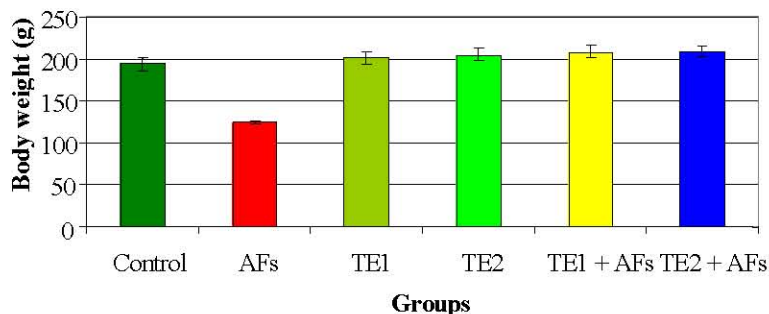


Fig. 1: Effect of the treatment with ethanol extract of thyme vulgaris on body weight of rats fed AFs-contaminated diet

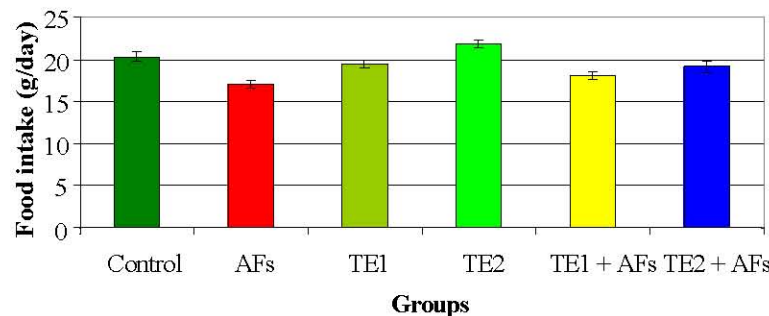


Fig. 2: Effect of the treatment with ethanol extract of thyme vulgaris on food intake of rats fed AFs-contaminated diet.

Animals treated with the TE1 or TE2 were comparable to the controls in all biochemical parameters except AST (Group TE1) which was decreased significantly compared to the control group. Administration with the extract at the two tested doses one week before and during the AFs treatment succeeded to induce a significant improvement in all parameters towards the control values. This improvement was more pronounced in the group receiving TE2.

The current results indicated that animals fed AFs-contaminated diet showed a significant decrease in

glutathione peroxidase (GPx) and superoxide dismutase (SOD) accompanied with a significant increase in MDA (Table 3). Animals treated with TE1 or TE2 alone showed insignificant increase in SOD while those treated with TE1 displayed a significant increase in GPx accompanied with a significant decrease in MDA. On the other hand, the effects of different treatments on inflammatory cytokines; TNF- α and IL-1 β (Table 4) revealed that TNF- α and IL-1 β were significantly increased in animals fed AFs-contaminated diet however; animals treated with TE1 or TE2 were comparable to the control group.

Table 3: Effect of ethanol extract of *Thyme* on liver antioxidants and lipid peroxidation

Group Parameter	Control	AFs	TE1	TE2	TE1+ AFs	TE2 + AFs
SOD (U/mg liver protein)	298.94 ± 12.79 ^a	164.23 ± 8.04 ^b	302.86 ± 13.46 ^a	315.32 ± 11.53 ^a	234.36 ± 4.06 ^c	258.42 ± 9.93 ^a
GPx (U/mg liver protein)	31.77 ± 2.47 ^a	15.34 ± 1.19 ^b	42.66 ± 1.21 ^c	48.65 ± 2.32 ^a	30.05 ± 2.41 ^a	33.07 ± 1.21 ^a
MDA (nmol/mg liver protein)	35 ± 1.28 ^a	90.29 ± 1.52 ^b	26.99 ± 2.22 ^c	22.43 ± 0.53 ^a	58.68 ± 4.91 ^d	42.87 ± 2.53 ^a

Within the row, means superscripts with different letters are significantly different at $p \leq 0.05$.

Table 4: Effect of ethanol extract of *Thyme* on serum inflammatory cytokines

Group Parameter	Control	AFs	T1	T2	T1+ AFs	T2 + Afs
TNF- α (pg/ml)	61.37 ± 2.81 ^a	123.13 ± 2.61 ^b	61.07 ± 2.07 ^a	60.72 ± 1.32 ^a	84.88 ± 2.28 ^c	72.32 ± 1.54 ^d
IL-1 β (pg/ml)	0.63 ± 0.04 ^a	1.93 ± 0.09 ^b	0.65 ± 0.04 ^a	0.60 ± 0.02 ^a	0.75 ± 0.05 ^c	0.67 ± 0.01 ^a

Within the row, means superscript with different letters are significantly different at $p \leq 0.05$.

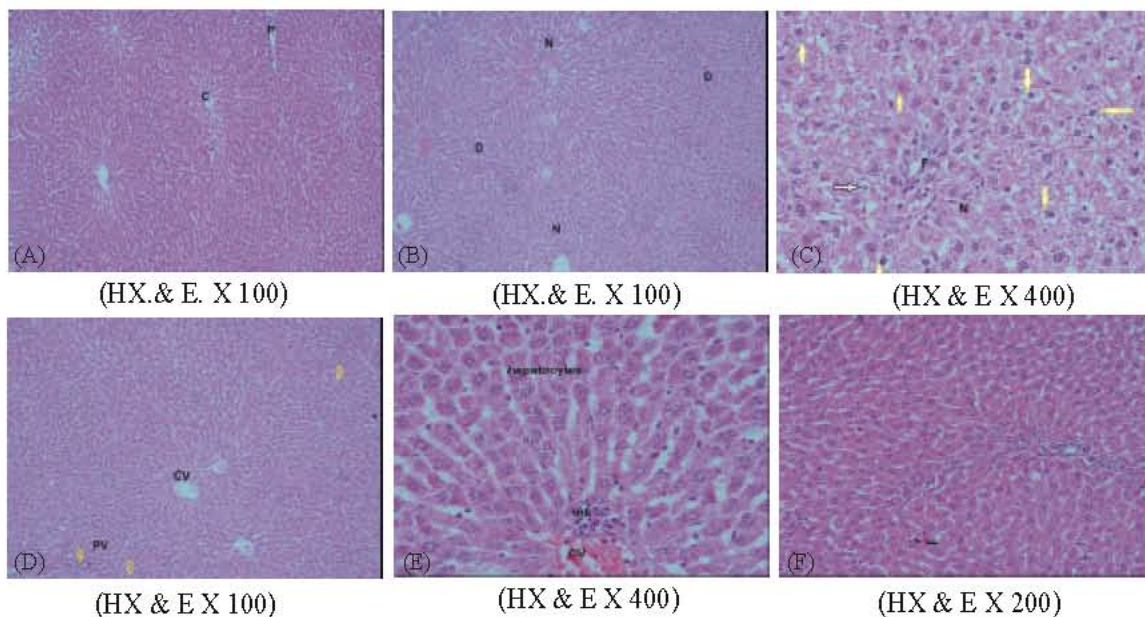


Fig. 3: A photomicrograph in liver section from (A) a control rat showing the central vein and the hepatocytes, (B) a rat fed AFs-contaminated diet showing the disorganization and damage in hepatocytes architecture mainly in the portal area around the portal tracts (D) with normal hepatocytes in the central vein area (N), (C) a rat fed AFs-contaminated diet showing hepatocytes necrosis (N), apoptosis (yellow arrows) and fibrosis around the blood vessels (F), (D) a rat treated with TE1 or TE2 alone showing hepatocytes with normal architecture in the central and the portal veins, (E) a rat fed AFs-contaminated diet and treated with TE1 showing the normal hepatocytes with vesicular nuclei and evident mononuclear cellular infiltration around the central vein and (F) a rat fed AFs-contaminated diet and treated with TE2 showing marked improvement in hepatocytes architecture and the nuclei have normal cytoplasm with vesicular nuclei.

The administration of TE1 or TE2 one week before and during AFs treatment succeeded to induce a significant improvement in TNF- α and IL-1 β towards the normal level although TNF- α and IL-1 β in the group receiving TE1 and TNF- α in the group receiving TE2 were still higher than the control in the group receiving TE1.

The histological examination of the liver section in the control rat showed normal central vein and hepatocytes (Fig. 3A). The liver of animals fed AFs-contaminated diet showed disorganization and damaged

hepatocytes architecture mainly in the portal area around the portal tracts with some normal hepatocytes in the central vein area (Fig. 3B). Some sections in the same group showed hepatocytes necrosis, apoptosis and fibrosis around the blood vessels (Fig. 3C). The microscopic examination of the liver sections in the animals treated with TE1 or TE2 alone showed hepatocytes with normal architecture in the central and the portal veins (Fig. 3D). The liver sections in the animals treated with TE1 one week before and during AFs

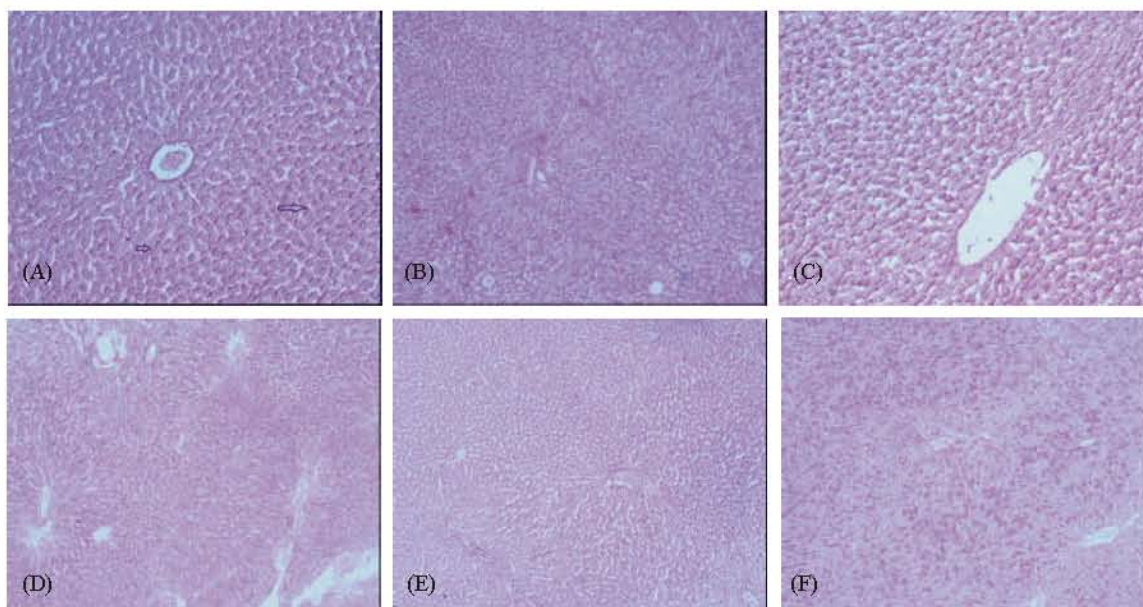


Fig. 4: Photomicrographs in liver sections stained with Periodic-Sheif reagent-stain (PAS) for glycogen demonstration from (A) control rats showing a strong reaction of PAS, (B) rats fed AFs-contaminated diet showing a weak reaction in the damaged cell while a strong reaction in intact cells, (C) rats treated with TE1 showing a strong reaction of PAS stain in hepatocytes, (D) rats treated with TE2 showing a strong reaction around the central vein and a weak reaction around the portal tracts, (E) rats fed AFs-contaminated diet and treated with TE1 showing that the hepatocytes are saturated with strong reaction in different areas and (F) rats fed AFs-contaminated diet and treated with TE2 showing strong reaction in the intact cells. (PAS reaction x 100)

treatment showed the normal hepatocytes with vesicular nuclei and evident mononuclear cellular infiltration around the central vein (Fig. 3E). Moreover, animals treated with TE2 before and during AFs treatment showed marked improvement in hepatocytes architecture and the nuclei have normal cytoplasm with vesicular nuclei (Fig. 3F).

The microscopic examination of liver sections stained with Periodic-Sheif reagent stain (PAS) for glycogen demonstration revealed that the control liver showed a strong reaction in the liver section (Fig 4A). The liver of animals fed AFs-contaminated diet showed a weak reaction in the damaged cell while a strong reaction was noticed in intact cells (Fig 4B). The liver of the animals treated with TE1 showed a strong PAS reaction in hepatocytes (Fig. 4C). Moreover, liver sections of rats treated with TE2 alone showed a strong reaction around the central vein and a weak reaction around the portal tracts (Fig. 4D). The liver of the animals fed AFs-contaminated diet and treated with TE1 showed that the hepatocytes were saturated with a strong reaction in different areas (Fig. 4E). However, the liver section of animals treated with TE2 before and during AFs treatment showed a strong reaction in the intact cells (Fig. 4F)

The histological examination of the kidney section of the control group showed the normal renal tubules and normal glomerular capsule with urinary space (Fig. 5A). The kidney sections in the animals fed AFs-contaminated diet showed tubular shrunken with lumen obliteration, tubular epithelial cells and glomerular cells are vacuolated with pyknotic nuclei (Fig. 5B). Some proximal and distal tubules have hyaline casts and cellular debris in their lumen (Fig 5C). The kidney sections in the animals treated with TE1 or TE2 showed normal structure in most of proximal and distal tubules and a renal corpuscle (Fig. 5D). The examination of the kidney sections in the animals treated with TE1 before and during AFs treatment showed increased in interstitial hemorrhages, nearly normal tubules and expanded glomerular cellularity (Fig. 5E). However, animals treated with TE2 before and during AFs treatment showed marked improvement in renal tubules and Bowman capsules with normal basement membrane and urinary space (Fig. 5F).

The histochemical examination of kidney sections stained with Periodic-Sheif reagent-stain (PAS) for carbohydrates demonstration manifested by the purple color showing the differences in the amount of mucin

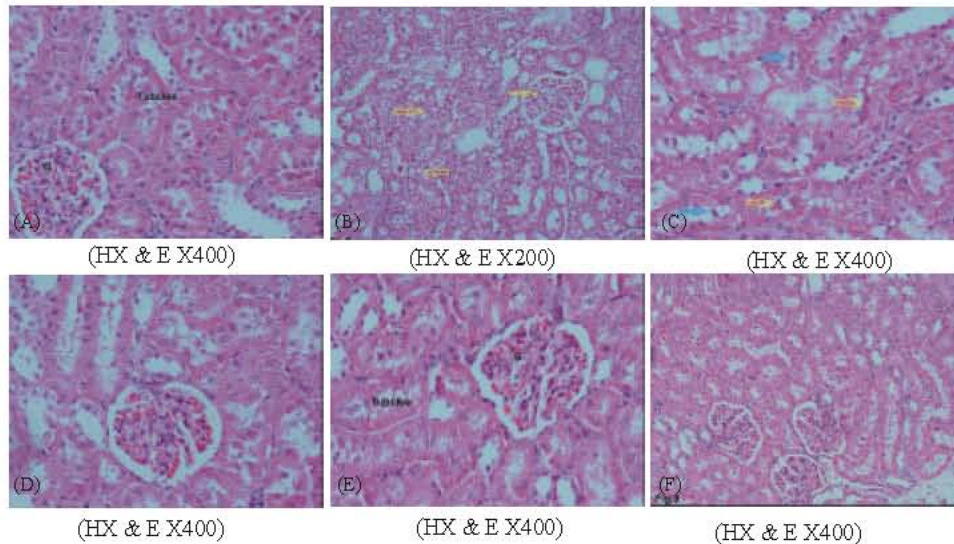


Fig. 5: Photomicrographs in a kidney from (A) control rats showing the normal renal tubules and normal glomerular capsule with urinary space, (B) rat fed AFs-contaminated diet showing tubular shrunken with lumen obliteration, tubular epithelial cells and glomerular cell are vacuolated with pyknotic nuclei (arrow), (C) rats fed AFs-contaminated diet showing that some proximal and distal tubules have hyaline casts and cellular debris in their lumen, (D) rats treated with TE1 or TE2 showing the normal structure in most of proximal and distal tubules and a renal corpuscle, (E) rats fed AFs-contaminated diet and treated with TE1 showing the improvement in most of proximal and distal tubules and glomeruli (G), few tubules are still exhibiting necrosis in the epithelial cell lining and (F) rats fed AFs-contaminated diet and treated with TE2 showing marked improvement in renal tubules and Bowman capsules with normal basement membrane and urinary space.

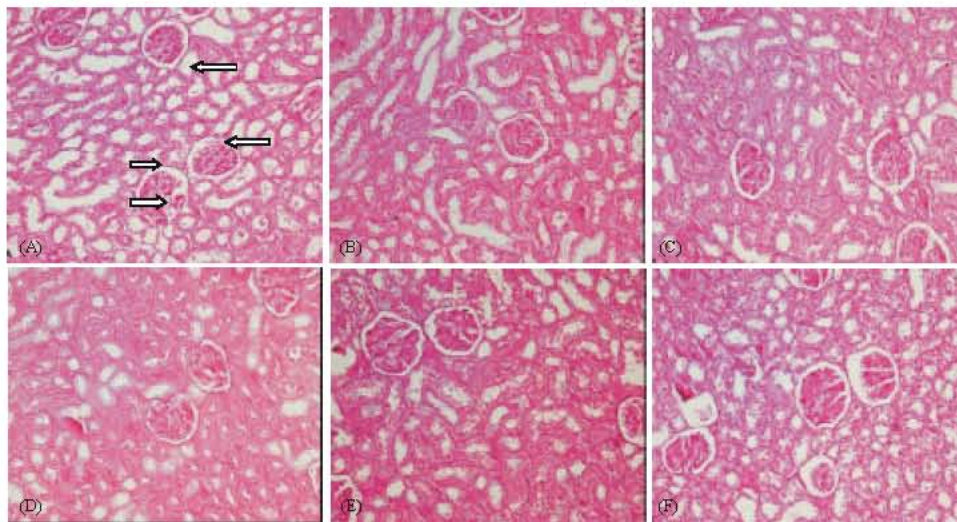


Fig. 6: Photomicrographs of kidney sections stained with Periodic-Sheif reagent-stain (PAS) for carbohydrates demonstration form (A) control animals showing positive reaction of PAS in the basement membrane of the tubules and Graffian follicles (G) and tubular brush border (b) and tufts (T), (B) animals fed AFs-contaminated diet showing positive reaction in some tubules and glomeruli others showing decrease in reaction brush border, (C) animals treated with T1 showing positive reaction in some tubules and glomeruli, (D) animals treated with TE2 showing positive reaction in some tubules and glomeruli, (E) animal fed AFs-contaminated diet and treated with TE1 showing positive reaction in different previous areas, low reaction in some epithelial cells lining tubules and (F) animal fed AFs-contaminated diet and treated with TE2 showing positive strong reaction in some tubules and glomeruli. (PAS reaction x 100)

reaction in tubular basement membrane and brush borders or in glomerular basement membrane and tufts in different groups. The results of PAS stain in the control group revealed that the kidney showed a positive reaction in the basement membrane of the tubules and Graffian follicle, tubular brush border and tufts (Fig. 6A). Animals fed AFs-contaminated diet showed positive reaction in some tubules and glomeruli, others showed decrease in reaction brush border (Fig. 6B). The kidney of the animals treated with TE1 or TE2 showed positive reaction in some tubules and glomeruli, others showing decrease in brush border reaction (Figs. 6C, D). However, the kidney of rats fed AFs-contaminated diet and treated with TE1 showed positive reaction in different previous areas, low reaction in some epithelial cells lining tubules (Fig. 6E). Moreover, animals treated with TE2 before and during AFs treatment showed marked improvement in renal tubules and Bowman capsules with normal basement membrane and urinary space (Fig 6F).

DISCUSSION

It is well known that the extraction of active ingredient compounds from plant material depends on the type of solvent used in the extraction procedure [31]. The results of the present study revealed that the yield and total phenols content of ethanolic extract were higher than that in the aqueous extract. These results are in agreement with those reported recently [32]. On the other hand, the ethanolic extract showed a higher DPPH free radical scavenging activity compared to the aqueous extract of thyme. These results are in agreement with those reported by Lin *et al.* [33], who reported that the ethanol extract of *thyme vulgaris* showed the strongest DPPH free-radical scavenging activity among forty two of different kinds of herbs. Conclusively, this study indicates that most of the active compounds in this plant are insoluble in water and are predicted to be non-polar, hydrophobic organic compounds. This implies that essential oil as non-polar organic compounds could be the main active compounds in this plant. These results agree with that of the previous study carried out by Ali-Shtayeh *et al.* [34] who reported that the ethanolic extract was the most active extract compared with ethyl acetate and freeze dried water extracts.

The current study was also conducted to evaluate the protective role of ethanol extract of *thyme vulgaris* against the oxidative stress and liver damage in rats fed AFs-contaminated diet. The selective doses of AFs and thyme extract were literature based [35, 36], respectively.

The results indicated that animals fed AFs-contaminated diet showed a significant decrease in body weight and feed intake compared to the untreated control rats. Similar decrease in food consumption and body weight is reported in rats treated with AFB₁ [37].

The reduction in body weight in the animals fed AFs-contaminated diet alone may be due to the effects of AFs on the balance between orexigenic and anorexigenic circuits that regulate the homeostatic loop of body weight regulation, leading to cachexia [38]. It is well documented that AFs exposure may lead to significant reduction of leptin [13]. Low leptin concentration accompanied with high levels of cortisol, IL-6 and insulin resistance which together act to influence the feeding response, causing weight loss in patients with pancreatic cancer [39]. This correlation may explain the recorded decrease in body weight in animals ingested AFs. Since leptin and its receptor are the key players in the regulation of energy. Another mechanism for the reduction of body weight due to AFs ingestion could be that AFs ingestion alters various digestive enzymatic activities that give rise to a malabsorption syndrome, characterized by steatorrhea, hypocarotenoidemia and to lowering of bile, pancreatic lipase, trypsin and amylase [40]. Moreover, the biotransformation of AFB₁ gives rise to various metabolites; the 8,9 epoxide, in particular, is relevant because it may covalently bind to DNA and to proteins, which then alters enzymatic processes, such as gluconeogenesis, Krebs cycle or fatty acid synthesis [41].

The results of the current study revealed that AFs lead to a significant increase of ALT, AST, ALP, urea and creatinine. The significant increase of ALT, AST and ALP in AFs-treated animals indicate changes in the hepatic tissues and biliary system [42], structural damaging of liver integrity, because these enzymes are cytoplasmic in location and released into plasma as a result of cellular damage [43, 44]. Moreover, increase in urea and creatinine levels reported in the current study in AFs-treated group clearly indicated the harmful and stressful effect on renal tissue. Taken together, the increased level of urea and the decreased level of albumin and total protein (TP) indicate the inhibition of protein synthesis and increase of protein catabolism and/or renal dysfunction [45, 46]. These results clearly indicated that AFs had stressful effects on the hepatic and renal tissues, consistent with those reported in the literature of aflatoxicosis [47, 48]. On the other hand, animals treated with AFs showed a significant increase in AFP which is considered a specific biomarker for liver cancer. This increase in AFP may be due to induction of expression of mRNAs of liver alpha-

fetoprotein [15, 48]. Similar to these observations, Yang *et al.* [49] and Sell *et al.* [50] reported that AFB₁ administration resulted in the elevation of serum AFP level in both duck and rats.

The hepatic antioxidants represent the major defense against toxic liver injury and they act as antiapoptosis. The current study showed that animals fed AFs-contaminated diet suffered from oxidative stress as indicated by the significant increment of lipid peroxidation (MDA) and the significant reduction of enzymatic antioxidants such as superoxide dismutase (SOD) and glutathione peroxidase (GPx). These results are in agreement with those reported by Abdel-Wahhab *et al.* [15] and Abdel-Aziem *et al.* [16] who suggested that oxidative stress may be due to direct effect of AFs or by the metabolites formed and the free radicals generated during the formation of these metabolites. Moreover, the reduction of protein synthesis in AFs-treated animals may affect certain metal ions (i.e. iron and copper), which play an important role in free radical production and liberation. In normal state, metal ions are bonded to transfer proteins, such as ceruloplasmin and transferrin [51] and play a crucial role of SOD, CAT and GPx activities, which constitute the enzymatic antioxidant defense system of the cell, displaying bidirectional alterations, either in the form of increase or decrease, depending on the particular tissue.

Tumor necrosis factor alpha (TNF- α) and interleukin-1 alpha (IL-1 α) are produced by macrophages and they play an important role in tumor conditions [13, 52]. It has been reported that TNF- α is an essential factor in tumor promotion [53]. Furthermore interleukin-1 polymorphisms are important mediators in the inflammatory process [54]. In the current study, the ingestion of AFs-contaminated diet significantly increased TNF- α and IL-1 α suggesting that AFs preferentially affects macrophage functions. In particular, it decouples the close correlations usually observed between transcriptional and translational controls of IL-1 α and TNF- α production by these cells [55]. Indeed, TNF- α plays a causal role in the development of liver injury [56]. Furthermore, it has been reported that TNF- α plays a major role in modulating mycotoxin-induced hepatotoxicity [57]. Moreover, TNF- α has been proven to play an important role in inflammation by mediating the proliferation and differentiation of immune cells and development of immune response [58]. TNF- α is one of the major inflammatory mediators secreted by activated macrophage and involved in many crucial events for the initiation of both acute and chronic inflammation, such as regulating the production of several cytokines, up-

regulation of adhesion molecule expression and activation of leukocyte-specific chemotactic cytokines [59].

The histological results reported in the current study confirmed the biochemical results and indicated that aflatoxin induced severe histological changes in the hepatic tissues. Similar histological changes in the liver have been documented previously [12, 15, 60].

There have been great efforts to find safe and potent natural antioxidants from various plant sources. Phenolic phytochemicals are thought to promote optimal health partly via their antioxidant and free radical scavenging effects thereby protecting cellular components against free radical induced damage [44]. The current study revealed that the ethanol extract of thyme is rich in phenolic compounds and showed a strong DPPH free radicals scavenging activity.

The improved feed intake, body weight, biochemical parameters, histological and histochemical picture of the liver and kidney in animals fed AFs-contaminated diet and treated with thyme extract revealed the protective role of the extract against AFs-mediated liver injury in a dose dependent manner through its antioxidant and free radical scavenging properties [61]. This antioxidant activity is mainly due to the presence of phenolic compounds thymol and carvacrol [21].

On the other hand, TE2 succeeded to restore IL-1 β to normal level and reduced TNF- α in rats treated with AFs. These results suggested that thyme extract possesses anti-inflammatory activity due to thymol content which was found to inhibit human elastase activity [62]. In addition, carvacrol has been described as promoter for liver regeneration and inhibitor in TNF- α and IL-6 level in rats undergoing partial hepatectomy [63]. Furthermore, carvacrol could reduce TNF- α and IL-1 β level in intoxicated rats through the inhibition of cyclooxygenase (COX) enzymes activity and mRNA expression and its protein in lipopolysaccharide induced inflammation [64]. Another mechanism by which thyme extract may possess anti-inflammatory response was suggested that thyme is able to modulate transcription factor of NF- κ B in both *in vitro* and *in vivo* [65].

It can be concluded that the ethanolic and aqueous extracts of *thyme vulgaris* are rich in the total phenolic content and have DPPH radical scavenging activity however; the ethanolic extract showed higher phenolic content and radical scavenging activity compared to the aqueous extract. The ethanolic extract exhibited hepatorenoprotective properties against aflatoxin-induced liver and kidney injury in a dose dependent manner due to its antioxidant, free radical scavenging activities and anti-inflammatory properties.

REFERENCES

1. Chen, C.J., Y.J. Zhang, S.N. Lu and R.M. Santella, 1992. Aflatoxin B₁ DNA adducts in smeared tumor tissue from patients with hepatocellular carcinoma. *Hepatology*, 16: 50-55.
2. Williams, J.H., T.D. Phillips, P.E. Jolly, J.K. Stiles, C.M. Jolly and D. Aggarwal, 2004. Human aflatoxicosis in developing countries: a review of toxicology, exposure, potential health consequences and interventions. *Am. J. Clin. Nut.*, 80: 1106-1122.
3. Lunn, R.M., Y.J. Zhang, L.Y. Wang, C.J. Chen, P.H. Lee, C.S. Lee, W.Y. Tsai and R.M. Santella, 1997. pp: 53 Mutations, Chronic Hepatitis B Virus Infection and Aflatoxin Exposure in Hepatocellular Carcinoma in Taiwan. *Cancer Res.*, 57: 3471-3477.
4. McGlynn, K.A., L. Tsao, A.W. Hsing, S.S. Devesa and Jr. J.F. Fraumeni, 2001. International trends and patterns of primary liver cancer. *Int. J. Cancer*, 94: 290-296.
5. El-Serag, H.B. and A.C. Mason, 1999. Rising incidence of hepatocellular carcinoma in the United States. *N. Engl. J. Med.*, 340: 745-750.
6. El-Zayadi, A.R., H.M. Badran, E.M. Barakat, M.D. Attia, S. Shawky, M.K. Mohamed, O. Selim and A. Saeid, 2005. Hepatocellular carcinoma in Egypt: a single center study over a decade. *World J. Gastroenterol.*, 11: 5193-5198.
7. FAO/WHO, 1999. Joint FAO/WHO Expert Committee on Food Additives (JECFA): B.G. Aflatoxins and M. WHO Technical Report, Geneva, 884: 69-77.
8. Munro, I., 1976. Naturally occurring toxicants in foods and their significance. *Clin. Toxicol.*, 9: 647-663.
9. IARC (International Agency for Research on Cancer), 1993. Aflatoxins. In: IARC Monographs on the Evaluation of Carcinogenic Risks to Humans. IARC. Lyon, France, 56: 243-395.
10. IARC (International Agency for Research on Cancer), 2002. Some traditional herbal medicines, some mycotoxins, naphthalene and styrene. In: IARC Monograph Evaluation Carcinogen Risk of Human, Lyon, France, pp: 1-556.
11. Rawal, S., J.E. Kim and R.Jr. Coulombe, 2010. Aflatoxin B₁ in poultry: Toxicology, metabolism and prevention. *Res Vet. Sci.*, 89: 325-331.
12. Abdel-Wahhab, M.A., S.A. Nada, I.M. Farag, N.F. Abbas and H.A. Amra, 1998. Potential protective effect of HSCAS and bentonite against dietary aflatoxicosis in rat: with special reference to chromosomal aberrations. *Nat. Toxin.*, 6: 211-218.
13. Abdel-Wahhab, M.A., H.H. Ahmed and M.M. Hagazi, 2006. Prevention of aflatoxin B₁ initiated hepatotoxicity in rat by marine algae extracts. *J. Appl. Toxicol.*, 26: 229-238.
14. Abdel-Wahab, M., N. El-Ghawalby, M. Mostafa, A. Sultan, M. El-Sadany, O. Fathy, T. Salah and F. Ezzat, 2007. Epidemiology of hepatocellular carcinoma in lower Egypt, Mansoura Gastroenterology Center. *Hepatogastroenterol.*, 54: 157-162.
15. Abdel-Wahhab, M.A., N.S. Hassan, A.A. El-Kady, Y.A. Khadrawy, A.A. El-Nekeety, S.R. Mohamed, H.A. Sharaf and F.A. Mannaa, 2010. Red ginseng extract protects against aflatoxin B₁ and fumonisins-induced hepatic pre-cancerous lesions in rats. *Food Chem. Toxicol.*, 48: 733-742.
16. Abdel-Aziem, S.H., A.M. Hassan and M.A. Abdel-Wahhab, 2011. Dietary supplementation with whey protein and ginseng extract counteracts oxidative stress and DNA damage in rats fed an aflatoxin-contaminated diet. *Muta. Res.*, 723: 65-71.
17. Dapkevicius, A., T.A. van Beek, G.P. Lelyveld, A. van Veldhuizen, A. de Groot, J.P.H. Linssen and R. Venskutonis, 2002. Isolation and Structure Elucidation of Radical Scavengers from *Thymus vulgaris* Leaves. *J. Nat. Prod.*, 65: 892-896.
18. EMAEMHU (European Medicines Agency Evaluation of Medicines for Human Use), 2006. Committee on Herbal Medicinal Products (HMPC) In: Community herbal monograph on *Thymus vulgaris* L. and *Thymus zygis* L., herba, final document of 31 October 2007 Doc. Ref. EMEA/HMPC/ 234113.
19. Van Den Broucke, C.O. and J.A. Lemli, 1983. Spasmolytic activity of the flavonoids from *Thymus vulgaris*. *Pharm. Weekbl. Sci.*, 5: 9-14.
20. Marino, M., C. Bersani and G. Comi, 1999. Antimicrobial activity of the essential oils of *Thymus vulgaris* L. measured using a bioimpedometric method. *J. Food Prot.*, 62: 1017-1023.
21. Miura, K., H. Kikuzaki and N. Nakatani, 2002. Antioxidant activity of chemical components from sage (*Salvia officinalis* L.) and thyme (*Thymus vulgaris* L.) measured by the oil stability index method. *J. Agri. Food Chem.*, 50: 1845-1851.
22. Pina-Vaz, C., Rodrigues A. Goncalves, E. Pinto, de Oliveira S. Costa, C. Tavares, L. Salgueiro, C. Cavaleiro, M.J. Goncalves and de Oliveira J. Martinez, 2004. Antifungal activity of *Thymus* oils and their major compounds. *J. Eur. Acad. Dermatol. Venereol.*, 18: 73-78.

23. Chizzola, R., H. Michitsch and C. Franz, 2008. Antioxidative properties of *Thymus vulgaris* leaves: comparison of different extracts and essential oil chemotypes. *J. Agri. Food Chem.*, 56: 6897-8904.
24. Hutchins, J.E. and W.M. Jr. Hagler, 1983. Rapid liquid chromatographic determination of aflatoxins in heavily contaminated corn. *J. Assoc. Off. Anal. Chem.*, 66: 1458-1465.
25. Jayaprakasha, G.K. and L.J. Rao, 2000. Phenolic constituents from the lichen *Parmotrema stippeum* (Nyl.) Hale and their antioxidant activity. *Zeitschrift Fur Naturforschung, C* 55: 1018-1022.
26. Jayaprakasha, G.K., T. Selvi and K.K. Sakariah, 2003. Antibacterial and antioxidant activities of grape (*Vitis vinifera*) seed extracts. *Food Res. Int.*, 36: 117-22.
27. Nogala-Kalucka, M., J. Korczak, M. Dratwia, E. Lampart-Szczapa, A. Siger and M. Buchowski, 2005. Changes in antioxidant activity and free radical scavenging potential of rosemary extract and tocopherols in isolated rapeseed oil triacylglycerols during accelerated tests. *Food Chem.*, 93: 227-35.
28. Drury, R.A., E.A. Wallington and R. Cancerson, 1980. *Carlton's histopathological techniques*. 4th ed. Oxford, London, New York: Oxford University Press.
29. SAS (SAS Institute Inc.), 1982. *SAS User's Guide: Statistics*. SAS Institute, Cary, NC.
30. Waller, R.A. and D.B. Duncan, 1969. A Bayes rule for the symmetric multiple comparison problems. *J. Am. Stat. Assoc.*, 64: 1484-1503.
31. Majhenic, L., M. Skerget and Z. Knez, 2007. Antioxidant and antimicrobial activity of guarana seed extracts. *Food Chem.*, 104: 1258-1268.
32. Rababah, T.M., F. Banat, A. Rababah, K. Ereifej and W. Yang, 2010. Optimization of extraction conditions of total phenolics, antioxidant activities and anthocyanin of oregano, thyme, terebinth and pomegranate. *J. Food Sci.*, 75: C626-C632.
33. Lin, C.W.E.N., C.W.E.N. Yu, S.C. Wu and K.H. Yih, 2009. DPPH Free-Radical Scavenging Activity, Total Phenolic. *J. Food Drug Anal.*, 17: 386-395.
34. Ali-Shtayeh, M.S., M.A. Al-Nuri, R.M.R. Yaghmour and Y.R. Faidi, 1997. Antimicrobial activity of *Micromeria nervosa* from the Palestinian area. *J. Ethnopharmacol.*, 58: 143-147.
35. Abdel-Wahhab, M.A. and S.E. Aly, 2003. Antioxidants and radical scavenging properties of vegetable extracts in rats fed aflatoxin-contaminated diet. *J. Agric. Food Chem.*, 51: 2409-2414.
36. Shati, A.A. and F.G. Elsaid, 2009. Effects of water extracts of thyme (*Thymus vulgaris*) and ginger (*Zingiber officinale* Roscoe) on alcohol abuse. *Food Chem. Toxicol.*, 47: 1945-1949.
37. Rustemeyer, S.M., W.R. Lamberson, D.R. Ledoux, G.E. Rottinghaus, D.P. Shaw, R.R. Cockrum, K.L. Kessler, K.J. Austin and K.M. Cammack, 2010. Effects of dietary aflatoxin on the health and performance of growing barrows. *J. Anim. Sci.*, 88: 3624-3630.
38. Rastogi, R., A.K. Srivastava and A.K. Rastogi, 2001. Biochemical changes induced in liver and serum of aflatoxin B₁ treated male Wistar rats: preventive effect of picroliv. *Pharmacol. Toxicol.*, 88: 53-58.
39. Barber, M.D., D.C. McMillan, A.M. Wallace, J.A. Ross, T. Preston and K.C.H. Fearon, 2004. The response of leptin, interleukin-6 and fat oxidation to feeding in weight-losing patients with pancreatic cancer. *Br. J. Cancer*, 90: 1129-1132.
40. Osborne, D.J., W.E. Huff, P.B. Hamilton and H.R. Burmeister, 1982. Comparison of ochratoxin, aflatoxin and T-2 toxin for their effects on selected parameters related to digestion and evidence for specific metabolism of carotenoids in chickens. *Poult. Sci.*, 61: 1646-1652.
41. Lesson, S., G. Diaz and J. Summers, 1995. *Poultry Metabolic Disorders and Mycotoxins*. Montreal Canada, University Books, pp: 249-298.
42. Abdel-Wahhab, MA., S.A. Nada and F.A. Khalil, 2002. Physiological and toxicological responses in rats fed aflatoxin-contaminated diet with or without sorbent materials. *Anim. Feed Sci. Tech.*, 97: 209-219.
43. El-Agamy, D.S., 2010. Comparative effects of curcumin and resveratrol on aflatoxin B₁-induced liver injury in rats. *Arch. Toxicol.*, 84: 389-396.
44. El-Nekeety, A.A., S.R. Mohamed, A.S. Hathout, N.S. Hassan, S.E. Aly and M.A. Abdel-Wahhab, 2011. Antioxidant properties of *thymus vulgaris* oil against aflatoxin-induced oxidative stress in male rats. *Toxicol.*, 57: 984-991.
45. Jindal, N., S.K. Mahipal and N.K. Mahajan, 1994. Toxicity of aflatoxin B₁ in broiler chicks and its reduction by activated charcoal. *Res. Vet. Sci.*, 56: 37-40.
46. Abdel-Wahhab, M.A. and S.E. Aly, 2005. Antioxidant property of *Nigella sativa* (black cumin) and *Syzygium aromaticum* (clove) in rats during aflatoxicosis. *J. Appl. Toxicol.*, 25: 218-223.

47. Miller, D.M. and D.M. Wilson, 1994. Veterinary diseases related to aflatoxins, The toxicology of aflatoxins. San Diego, CA, Academic Press, pp: 347-364.
48. Abdel-Wahhab, M.A. and A.M. Kholif, 2008. Mycotoxins in animal feeds and prevention strategies: A review. Asian J. Anim. Sci., 2: 7-25.
49. Yang, C.F., J. Liu, S. Wasser, H.M. Shen, C.E.L. Tan and C.N. Ong, 2000. Inhibition of ebselen on aflatoxin B₁-induced hepatocarcinogenesis in Fischer 344 rats. Carcinogenesis, 21: 2237-2243.
50. Sell, S., K.L. Xu, W.E. Huff, L.F. Kabena, R.B. Harvery and H.A. Dunsford, 1998. Aflatoxin exposure produces serum alphafetoprotein elevations and marked oval cell proliferation in young male Pekin ducklings. Pathol., 30: 34-39.
51. Gitto, E., S. Pellegrino, P. Gitto, I. Barberi and R.J. Reiter, 2009. Oxidative stress of the newborn in the pre and postnatal period and the clinical utility of melatonin. J. Pin. Res., 46: 128-139.
52. Moon, E.Y., D.K. Rhee and S. Pyo, 1999. Involvement of NO, H₂O₂ and TNF-[alpha] in the reduced antitumor activity of murine peritoneal macrophages by aflatoxin B₁. Cancer Lett., 136: 167-1676.
53. Sukanuma, M., E. Sueoka, N. Sueoka, S. Okabe and H. Fujiki, 2000. Mechanisms of cancer prevention by tea polyphenols based on inhibition of TNF-alpha expression. Biofactors, 13: 67-72.
54. Rollinson, S., A.P. Levene, F.K. Mensah, P.L. Roddam, J.M. Allan, T.C. Diss, E. Roman, A. Jack, K. MacLennan, M.F. Dixon and G.J. Morgan, 2003. Gastric marginal zone lymphoma is associated with polymorphisms in genes involved in inflammatory response and antioxidative capacity. Blood, 102: 1007-1011.
55. Hopkins, S.J., 2003. The pathophysiological role of cytokines. Legal Med., 5: S45-S57.
56. Barton, C.C., E.X. Barton, P.E. Ganey, S.L. Kunkel and R.A. Roth, 2001. Bacterial lipopolysaccharide enhances aflatoxin B₁ hepatotoxicity in rats by a mechanism that depends on tumor necrosis factor. Hepatol., 33: 66-73.
57. Voss, K.A., R. Riley, C. Dunn and Corton J. Christopher, 2006. The role of tumor necrosis factor and the peroxisome proliferator-activated receptor in modulating the effects of fumonisin in mouse liver. Toxicol., 222: 165-174.
58. Cao, J., L.P. Jiang, X.M. Zhang, X.F. Yao, C.Y. Geng, X.X. Xue and L.F. Zhong, 2008. Boric acid inhibits LPS-induced TNF-alpha formation through a thiol-dependent mechanism in THP-1 cells. J. Trace Elem. Med. Biol., 22: 189-195.
59. Zhou, H.P., H. Lutterodt, Z.H. Cheng and L.L. Yu, 2009. Anti-inflammatory and antiproliferative activities of trifolirhizin, a flavonoid from sophora flavescens roots. J. Agric. Food Chem., 57: 4580-4585.
60. Hathout, A.S., S.R. Mohamed, A.A. El-Nekeety, N.S. Hassan, S.E. Aly and M.A. Abdel-Wahhab, 2011. Ability of *Lactobacillus casei* and *Lactobacillus reuteri* to protect against oxidative stress in rats fed aflatoxins-contaminated diet. Toxicol., 58: 179-186.
61. Loziene, K., P.R. Venskutonis, A. Sipailiene and J. Labokas, 2007. Radical scavenging and antibacterial properties of the extracts from different *Thymus pulegioides* L. chemotypes. Food Chem., 103: 546-559.
62. Braga, P.C., M. Dal Sasso, M. Culici, T. Bianchi, L. Bordoni and L. Marabini, 2006. Anti-inflammatory activity of thymol: inhibitory effect on the release of human neutrophil elastase. Pharmacology, 77: 130-136.
63. Uyanoglu, M., M. Canbek, E. Aral and C.B.K. Husnu, 2008. Effects of carvacrol upon the liver of rats undergoing partial hepatectomy. Phytomedicine, 15: 226-229.
64. Tsai, M.L., C.C. Lin, W.C. Lin and C.H. Yang, 2011. Antimicrobial, antioxidant and anti-inflammatory activities of essential oils from five selected herbs. Biosci. Biotechnol. Biochem., 75: 1977-1983.
65. Paur, I., T.R. Balstad, M. Kolberg, M.K. Pedersen, L.M. Austenaa, D.R. Jacobs and R. Blomhoff, 2010. Extract of oregano, coffee, thyme, clove and walnuts inhibits NF- B in monocytes and in transgenic reporter mice. Cancer Prev. Res., 3: 653-663.