

Comparison of *In vivo* Wound Healing Activity of *Verbascum thapsus* Flower Extract with Zinc Oxide on Experimental Wound Model in Rabbits

¹Borhan Mehdinezhad, ²Ali Rezaei, ³Daryoush Mohajeri and ⁴Saeid Safarmashaei

¹Animals Surgery, Science and Researches Branch, Islamic Azad University, Tehran, Iran

²Department of Clinical Science, Tabriz Branch, Islamic Azad University, Tabriz, Iran

³Department of Pathobiology, Tabriz Branch, Islamic Azad University, Tabriz, Iran

⁴Young Researchers Club, Tabriz Branch, Islamic Azad University, Tabriz, Iran

Abstract: Nowadays, the promotion of wound healing in some diseases and chronic disorders with the aid of herbal extract is more challenging. That is why new compounds prepared for this purpose have been widely accepted. *Verbascum thapsus* is from Scrophuoriaceae family. It is considered as an effective drug in remedy of wounds in traditional medicine. Also this plant plays an important role in enhancing elasticity and resistance of skin. It can also be effective in restoration of tissue in case of cell death. This article aims are to study histopathological and histometrical effects of *Verbascum thapsus* extract consuming in comparison with zinc oxide on healing after experimental coetaneous wound creation in rabbit. Material and Methods: The extracts were prepared. Under surgical anesthesia, one full thickness similar excisional wound were made on the back of 40 rabbits and they were divided into 4 groups of *Vevascum thapsus* 20%,zinc oxide ointment, Eucerin and control. A double-blind method was used throughout the study. All the cases were treated with topical ointment for 28 days daily. Healing process of the wound was daily checked and compared using digital photography and image analysis software. Histopathologic examination was performed in the 0th, 7th, 14th, 21th and 28th days and the wound healing was scored using healing grade ² to ²V with regard to the wound healing parameters such as edema, phylogenic process, congestion, hemorrhage, fibroplasia, epithelium regeneration, wound contraction, collagen deposition and granulation tissue maturation. The overall outcome of the wound recovery for each individual group was calculated and the results were analyzed by SPSS software. Result: The statistical results showed significant difference in healing process of *Verbascum thapsus* 20% group in comparison with other groups. Healing process in Zinc oxide group was better than *Verbascum thapsus* 20%. Eucerin was in next in place. The control group had the worst case. The results showed that *Verbascum thapsus* 20% extract Have good healing effect on regeneration. Conclusion: *Verbascum thapsus* could be a new promising therapeutic approach to wound healing because of its anti-inflammatory potential and wound healing stimulatory effects.

Key words: *Verbascum thapsus* • Wound Healing • Anti-Inflammation • Skin • Rabbit

INTRODUCTION

Nowadays,Chronic wounds and wounds that have little regeneration ability, are important clinical problems. These wounds occurrences are increased by occurrence of some diseases like fatness, diabetes mellitus and bedsore, there by chemical and botanical drugs have been introduced to accelerate the treatment [1]. *Verbascum thapsus* flower is one year or two years firm bush. *Verbascum* species are worldwide distributed and grow

in Asia, north Africa, north America and Europe [2]. *Verbascum* chemical compounds include: 3% musilage that transforms to galactose, arabinose and aromatic acids (act as unguent) after hydrolyzes; 4% flovonoeids including rutine and hesperidin as common (cause diuretic effects), triterpene saponins, verbasco saponin(have expectorant activity), iridoid glycoside, tannen: acobin, katapol and related compounds (have anti-inflammatory activity), polysaccharides: galactose, arabinose and phenolic acids that have

medical effects in local inflammation [3, 4]. Its fumigation has nose anticongestive effect and is used for respiratory channels disorders [5]. Dried powder and leaves poultice are used for severe wounds of any kind. In ancient medicine viewpoint, 6 spices of this flower have no side effects and have the following treatment features; pulmonary disease, somniferous, sore throat, vein constrictor, wound healing and pertussis treatment [6-8]. Antiviral effects also are considered for this plant [9]. Its recommended dose does not have any side effects [6]. About its healing effect on wound, there is not any clinical and scientific experiment [10]. Zinc oxide ointment is one of the most consumed topical constrictor and protective agent in topical wound treatment that has 20% zinc oxide powder and has a vast usage in skin disease. Most of the ointments, powders, lotions and pastes are zinc oxide included. Different formulation methods have been used for zinc oxide in USA and it is used for 4 reasons: as surface protectant, constrictor, partial antiseptic and anti toxicant. Eucerin or cholesterol vaseline is a natural substance that is extracted from sheep wool. But is produced synthetically today [11]. Eucerin is a base for other ointment products. Eucerin structure makes the drug homogenous and easily released. Eucerin is used as lanolin in shampoos [12].

MATERIALS AND METHODS

Animals: Forty male rabbits were selected with average weight of 1500 ± 150 g and average age of 3 months. Rabbits were fed by safe water and pellet (Tabriz Niroosahand Coproduction®). All of the rabbits were kept in antiseptic condition in laboratory in Tabriz Islamic Azad University. They were kept in 24°C and 70% humidity in an 80 m^2 room and separated cages. During this period natural lighting were used. The protocol of this study is on the basis of ethical principles of international committees that protect laboratory animals.

Preparation of the Extract: The method for extracting *Verbascum thapsus* flower is as the following: milling and making powder and putting for 48 hours in chloroform methanol solvent compound (40:60), the mix is filtered and the solvent is evaporated by using rotary and the remainder mixture is solved in the least volume of methanol for fat removing. Remainder is solved in at list dichloromethane or chloroform and water is removed by sodium sulphate. Again the solvent is evaporated under vacuum condition and net extract is recovered [13].

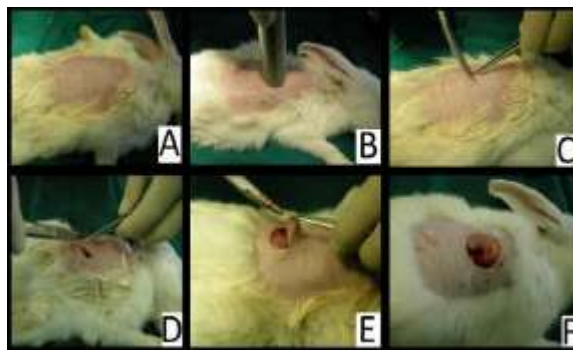


Fig. 1: In the rabbit model, the process of the "punch-incision" wound creation, 2.5×0.3 cm (length \times depth)

Administration and Wound Excision Model:

The rabbits were anesthetized by administering Xylazine® 2% (Alphasam company, Holland, 0/44 mg/kg b.wt., IM) and Ketamine Hydrochloride® 10% (Alphasam company Holland, 11 mg/kg b.wt., IM). Because of very low injection volume, sterile insulin syringes were used separately for each rabbit.

After anesthesia, the awareness (alertness) level of rabbits was determined and shaving was done. The shaving area was back of the animal, in the withers. Antiseption was done by alcohol 70% and povidoneiodine 10% for 7 times. Animals were lay on surgical Table in sternal recumbency [14]. "Punch-incision" wound of $2.5 \text{ cm} \times 0.3 \text{ cm}$ (diameter \times depth) was created using a biopsy forceps at one spot within the shaved area. This procedure generates the wound in both the epidermis and the dermis layers [15] (Fig. 1).

Histopathological Study: At the end of the experiment, the cross-sectional full-thickness skin specimens from each group were collected for histopathology. Samples were fixed in buffered formalin 10%, processed and blocked with paraffin and then sectioned into $5 \mu\text{m}$ sections and stained with Hematoxylin & Eosin (H&E). The tissues were examined by light microscope (Olympus CX41 attached with Kameram® Digital Image Analyze System) and graded subjectively (Fig. 2).

Histometry: By means of morphometrical techniques, quantitative information on the observed variations related to skin epithelium diameter recorded on each slide (of all samples) was analyzed using the Image Tools 3.0 software.

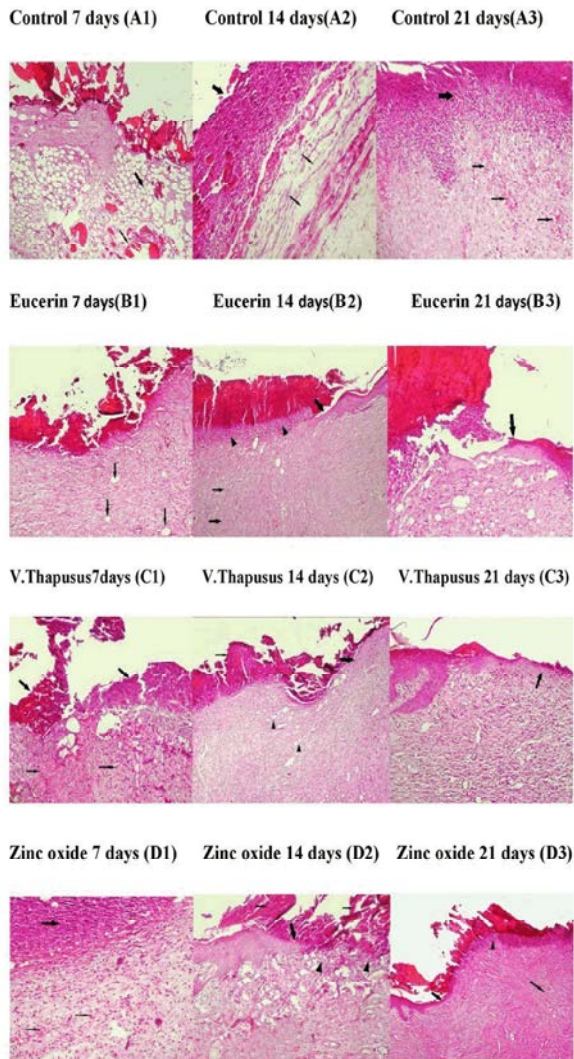


Fig. 2: Histopathological view of wound healing in epiderm /derm. Remodeling in the control, *verbascum Thapsus*, eucerin and zinc oxide groups. (H&E, 40X).

Statistical Analysis: The data on wound healing percentage were statistically analyzed using One-Way Analysis of Variance (ANOVA). A p-value ≤ 0.05 was considered statistically significant. Histopathologic data were considered to be nonparametric.

RESULTS AND DISCUSSION

The Experimental Results Are Given in Fig 2-4: In group with the Zinc oxide 20% the wound demonstrated the best tensile strength and the wound healing was the lowest ($0.178 m^2$) on the 21th day (Fig. 3). In this fig the *Verbascum thapsus* has second place in the wound

healing and tensile strength. Histopathological and histometrical results are summarized and presented in Fig. 1 and Figs. 3,4. According to the results we can state, *Verbascum thapsus* improve excisional wounds by reducing swelling and inflammation of surgical trauma. In order to introduce action mechanism of the plant extract many experiments should be done, such as assessing the effect of each component of the extract on histometric and histopathologic parameters, serum levels of growth factors and their synergic activity, separately.

Histometrical Examination: Wound area in all groups increase until day 7 of trail period in comparison with day zero. In day 14, this process is reduced and by using histometric results we found that *Verbascum thapsus* has better trend than Eucerin but slower process than zinc oxide. By lapse of time this difference was more observable. On day 21 zinc oxide group had the most percentage of wound contraction, *Verbascum thapsus* was in the second place and the control group had the last place in wound area diameter (Fig. 1). The results of Tukey test showed significant difference in wound areas on 0,7,14 and 21 days in different groups (Fig. 3 and diagram 1, $p \leq 0.05$).

Histopathological Examination: On day zero in wound place, clot of blood around the wound, infiltration of inflammatory cells and fibrin sediment were observed. On the 7th day the predominant phenomenon was developing areolar connective tissue in hypoderm from deep parts of the wound into the empty space. Bleeding and clot formation in empty space of the wound and surface sealing were observed in control group (Fig. 2).

On the 7th day of experiment, in groups with eucerin and zinc oxide, coagulation of blood including fibrin, inflammatory cells, necrotic tissues debris covered the wound surface. Wound space was filled by granulation tissues. Acute type inflammatory cells was observed in granulation tissues with hyperemia (Fig. 2).

On the 7th day of experiment in treatment group with *Verbascum Thapsus* extract, wound surface was covered by crut including blood clot with fibrin, inflammatory cells and necrotic tissue debris. Wound space was filled with young granulation tissues that had bleeding, hyperemia and intense necrotic changes and was infiltrated by inflammatory cells. These changes were severe in surface (Fig. 2).

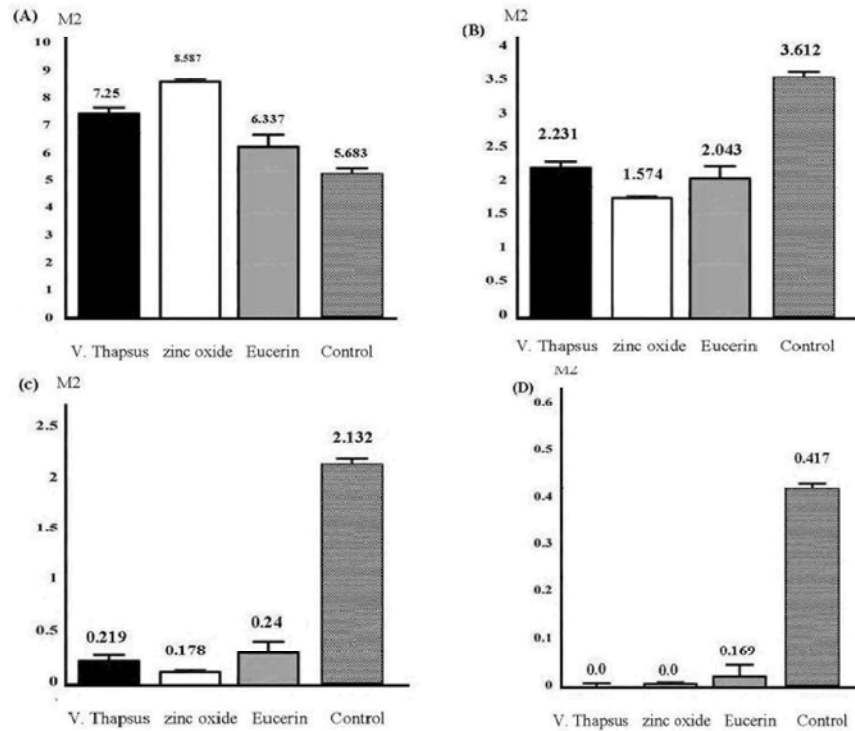


Fig. 3: The wound place on day 7 (A) day 14 (B) day 21 (C) day 28 (D).

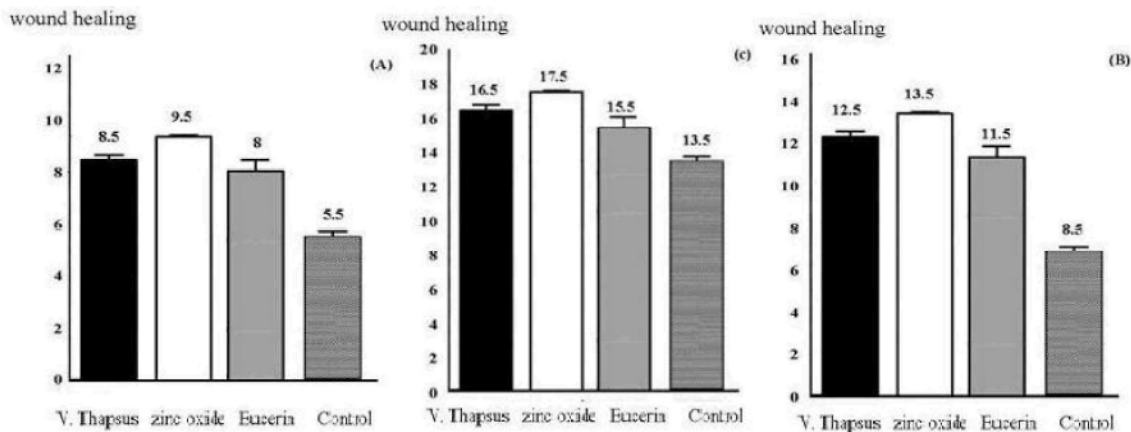


Fig. 4: The process of wound healing on day 7 (A), day 14 (B) and day 21 (C)

On 14th day of experiment, in all groups, blood clot including fibrin, inflammatory cells and necrotic tissue debris covered the wound. In control group repairing tissues and existing of edema extended to the interstitial space were seen. More inflammatory cells and necrotic tissue with bacterial colonies were observed in the wound (Fig. 2). In treatment group with eucerin and zinc oxide on 14th days of experiment, wound space was filled by young cells and vessel rich granulation tissues and hyperemia was observed in new vessels. Abundant inflammatory cells were observed around the surface of the wound.

Newborn epithelial squamous tissue was formed under clot and was extended to wound surface (Fig. 2).

On 14th day of experiment, in treatment group with *Verbascum thapsus* extract, wound space was filled by cells and vessel rich young granulation tissues with hyperemia and minor bleeding. Acute inflammatory cells were limited to the wound surface and under crust. Wound surface was covered with crust including blood clot with fibrin, inflammatory cells and necrotic tissues debris. Newborn epithelial squamous tissue was formed under clot and was extended to wound surface (Fig. 2).

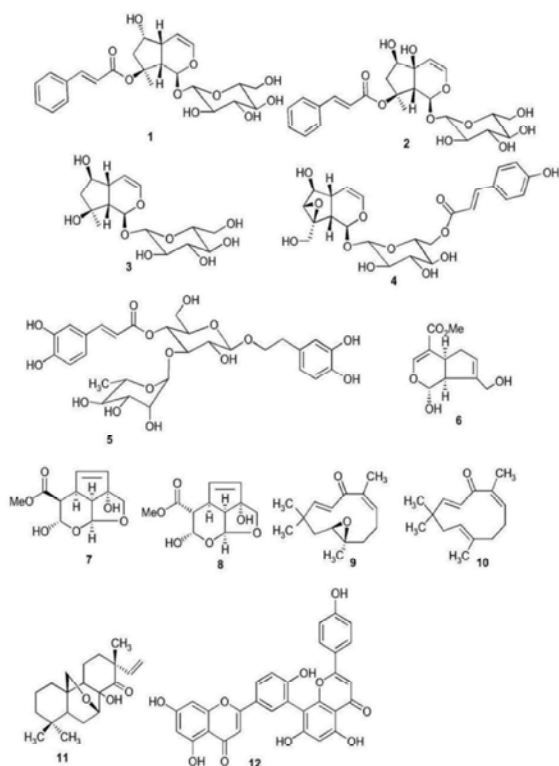


Fig. 5: Chemotaxonomic significance

On 21th day after surgery in control group, new born epithelial squamous tissue, began to extend toward wound surface. Wound surface was covered by crut containing blood clot, abundant inflammatory cells and necrotic tissue debris. Wound space was filled by cells and vessel rich young granulation tissues and less hyperemia was seen in new vessels (Fig. 2).

In treatment group with eucerin and zinc oxide on 21st day of experiment, new born epithelial squamous tissue covered most parts of wound surface and epithelial gap of wound was filled with small crut including blood clot, inflammatory cells and necrotic tissue debris. Wound space was filled with young granulation tissue that had more fibers. Inflammatory cells infiltration under the crut were more than other parts of regenerated tissue (Fig. 2).

Treatment of the wound with herbal extract of *Verbascum thapsus* was associated with enhanced formation of epidermis and deposition of connective tissue when compared to control group animals. The lesser epithelialization and lesser collagen formation were in control groups. The animals without treatment indicated incomplete healing. The results of Tukey test showed significant difference in wound areas on 0,7,14 and 21 days in different groups shown in Fig. 4 and diagram 2 ($p \leq 0.05$).

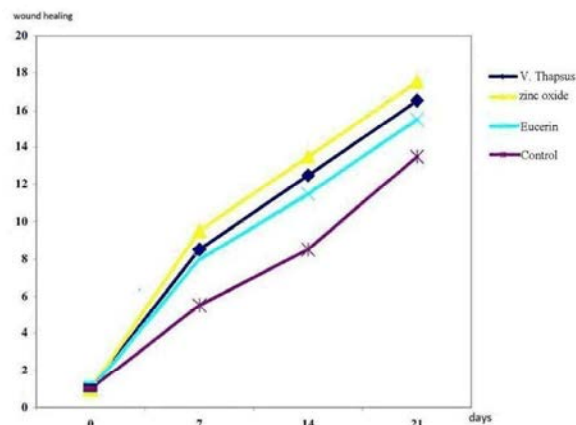


Diagram 1: Comparison of *in-vivo* wound healing activity (histopathological) of *Verbascum Thapsus* flower on the 7th day to 21th day with other groups

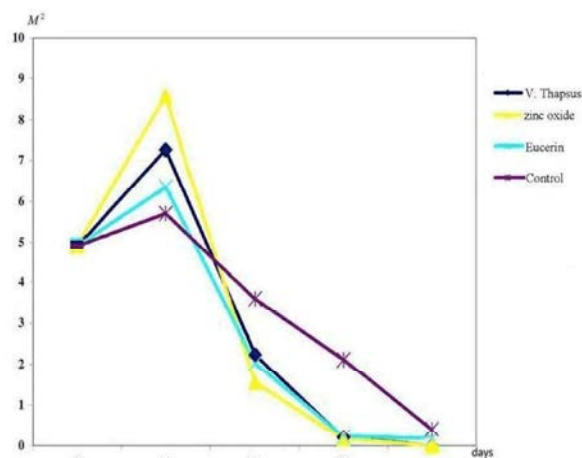


Diagram 2: Comparison of *in-vivo* wound healing activity (Histometrical) of *Verbascum Thapsus* flower on the 7th day to 21th day with other groups.

The flower of *Verbascum thapsus* has been traditionally used as cicatrizant in the Abruzzo, Lazio and Molise National Park (Italian Apennines) (Idolo *et al.*, 2010). The anti-inflammatory and antinociceptive agent of the flowers of *Verbascum* species were investigated in a previous study [16].

Verbascum species in previous studies were also shown to have antimicrobial activity [17-20]. Antimicrobial potential of a wound healing promoting agent is important because of prevention of the wound from microbial infection.

The *Verbascum thapsus* is a rich source of flavonoids, iridoids, saponins and polysaccharides [21-23] (Fig. 5).

Polysaccharides have been shown to have mainly anti-inflammatory and immunomodulating activities. Their beneficial effects on burns, wounds, ulcers, external and internal inflammations and irritations, diarrhea and dysentery have also been well-known in the traditional or conventional medicine. Wound healing activity of some *Verbascum* species may be attributable to their polysaccharide content [24, 25].

Zinc oxide is one of the most consumed ointments for topical wound treatment that includes 20% zinc oxide powder. Surface protection, constriction, partial antiseptic and being non toxic are the characteristics of this drug, that lead to use it in medical and health material agents [11]. In our study this ointment has been used as positive control. Bacterial infection of digestive system by *kelebsiella pneumonia* and *staph. aureus* and urine system can be treated by *Verbascum thapsus*. A study has been done on its structure and biological formula [26]. This plant has antibacterial effects on gram negative and gram positive bacteria but this is not related to the methanol of this flower.

Gradation of Fibroplasias Process in Wound Space:

Not appearing granulation tissue on wound and occupation of wound space by blood clot including fibrin and blood cells and inflammatory cells and filling of the wound space by extending areolar connective tissue from under part of the tissues, Grade 1.

Primary appearance of granulation tissue on wound place, cell-rich granulation tissue and new vessels in wound place (angiogenesis), Grade 2.

Primary appearance of collagen (fibrous) in wound space, Grade 3.

Arrangement in collagen (fibrous) in wound space, Grade 4.

Gathering and organizing collagen and scar erosion on wound space, Grade 5.

Epithelial Tissue Reconstruction: Not observing epithelial tissue reconstruction (primary sealing of wound by blood coagulation including fiber and blood cells and evaporation from coagulation surface and crut on wound surface, sometimes mucosa excretion with mesensymal source in the keratocells collected on wound was seen as a distinguished layer on wound).

A1: The space was filled with areolar connective tissue (thick arrow) in deep parts that is along side with severe hypermia (slim arrow). A2: Young vessel-rich granulation tissue (slim arrow), fibrin, inflammatory cells and necrotic

tissue debris. Inflammatory cells excretions under coagulate is severe (arrows tip). A3: fibrin, inflammatory cells and necrotic tissue debris. Inflammatory cells excretion under coagulate is severe (arrows tip), Inflammatory cells excretions under coagulate is severe (thick arrow, 100X). B1: Wound space completely occupied with young vessel – rich granulation tissue (arrows). There is less and slight hyperemia in new vessels. Wound surface was covered with crut of blood clot including fibrin, inflammatory cells and necrotic tissue debris. B2: wound surface was occupied fully by young vessel-rich granulation tissue (slim arrow), B3: New squamous covering tissue that extend from crut to wound. C1: Wound surface was covered by crut of blood clot including fibrin, inflammatory cells and necrotic tissue debris. (thick arrows), C2: wound surface was covered with crut of blood clot including fibrin, inflammatory cells and necrotic tissue debris (slim arrows), Wound space was filled by cell and vessel – rich young granulation tissue, Inflammatory cells excretions under coagulate and wound borders are inflamed severely (arrows tip), C3: New squamous covering tissue that forward from crut to the wound can be seen and covered by crut of blood clot. D1: Wound space was occupied completely by young granulation tissues including inflammatory cells of acute type and slight and dispensed bleeding (slim arrow), D2: Wound surface was covered with crut of blood clot including fibrin, inflammatory cells and necrotic tissue debris (slim arrows). Inflammatory cells excretions under crut and wound borders is severe (arrows tip). D3: New squamous covering tissue that forward from crut to wound can be seen. Excretion of cells under crut is severe. Wound space is filled by granulation tissues that have fibrosis.

REFERENCES

1. Emami, A. and A. Ahi, 2008. Medical Bothany. Iran University of Medical Sciences and Health Services, pp: 37-96.
2. Rahimina, M., 2007. Dictionary of extensive medical plants. Bayan Nashr Company, pp: 413-415.
3. Jafarnia, S., S. Khosroshahi and M.G. Hasemi, 2006. Textbook and Extensive Medical Plants. Integrated Agricultural Education Sabze Iran, pp: 36-39.
4. Millspaugh, C.F., 1974. American Medicinal Plants. Dover Publishing Inc. New York, pp: 430-434.
5. Duck James, A., 1997. The green pharmacy new discoveries in herbal remedies for common diseases conditions from the World's Foremost Authority on Healing Herbs. Nashreney Company, pp: 152-156.

6. Khosbin, S., 2007. 100 Magical herbals. Donyaye Noor Company, 2: 667-669.
7. Zaman, S., 1998. Medical plants. Qognoos Publication House, pp: 335.
8. Zargari, E., 1989. Iran Medical Plants. Iran University of Medical Sciences and Health Services, 4: 230-235.
9. Akhond Zadeh, S.H., 2000. Medical plants Wikipedia. Academic Center for Education & Research (ACECR), pp: 138.
10. Omidbaigi, R., 2007. Production and Processing of Medical plants. Beh nasr Company, 2: 117-169.
11. Katzung, B., 2004. Basic and clinical Pharmacology. Samat Company, 4: 341-382.
12. Sthal, E., 2003. Chromatographische and mikroskopische Anaysis von Drogen. roozbahan company. Translate By: Dr Samsam Sheriat. H., pp: 19-26.
13. Samsam Shariyat, H., 1992. Herbal extracting an effective medical plants. 1st ed. Mani Press. Isfahan., pp: 8-20.
14. Vahar, M., H. Khodabakhsh, M. Rahmani and S. Fahihzaheh., 2008. Anesthesia in special cases. Nour bakhsh Company, pp: 26-43.
15. Lusua, A. and L. Dipietro, 2003. Burns Wound Healing. Methods and protocols (methods in Molecular Medicine). Human press Inc, 1: 3-16.
16. Suntar, I., I. Tatlı, E. KupeliAkkol, H. Keleş, Ç. Kahraman and Z. Akdemir, 2010. An ethnopharmacological study on *Verbascum* species: From conventional wound healing use to scientific verification. *J. Ethnopharmacol.*, 132: 408-413.
17. Meurer-Grimes, B., D.L. McBeth, B. Hallihan and S. Delph, 1996. Antimicrobial activity in medicinal plants of the Scrophulariaceae and Acanthaceae. *J. Pharmaceutical Biol.*, 34: 243-248.
18. Akdemir, Z.S, I.I. Tatlı, E. Bedir and I.A. Khan, 2003. Antimicrobial and antimalarial activities of some endemic Turkish *Verbascum* species. *FABAD J. Pharmaceutical Sci.*, 28: 131-135.
19. Tatlı, I.I. and Z.S. Akdemir, 2005. Antimicrobial and antimalarial activities of secondary metabolites from some Turkish *Verbascum* species. *FABAD J. Pharmaceutical Sci.*, 30: 84-92.
20. Tatlı, I.I., Z.S. Akdemir, E. Bedir and I.A. Khan, 2003. Search for antifungal compounds from some *Verbascum* species growing in Turkey. *FABAD Journal of Pharmaceutical Sci.*, 28: 137-140.
21. Klimek, B., 1996. Hydroxycinnamoyl ester glycosides and saponins from flowers of *Verbascum phlomoides*. *Phytochemistry*, 43: 1281-1284.
22. Yuldashev, M.P., 1996. Flavonoids of the roots of *Verbascum songoricum*. *Chemistry of Natural Compounds*, 32: 925.
23. Kanzaki, T., N. Morisaki, R. Shiina and Y. Saito, 1998. Role of transforming growth factor-path way in the mechanism of wound healing by saponin from Ginseng *Radix rubra*. *British J. Pharmacol.*, 125: 255-262.
24. Morton, J.F., 1990. Mucilaginous plants and their uses in medicine. *J. Ethnopharmacol.*, 29: 245-266.
25. Galati, E.M., M.R. Mondello, M.T. Monforte, M. Galluzzo, N. Miceli and M.M. Tripodo, 2003. Effect of *Opuntia ficus-indica* (L.) Mill. cladodes in the wound healing process. *Journal of the Professional Association for Cactus Development*, 5: 1-16.
26. Hidayat, H., A. Shahid, A. Ghulam, A. Viqar Uddin, A. Saeed and A. Ishtiaq, 2009. Minor chemical constituents of *Verbascum Thapsus*. *J. Biochemical Systematics and Ecol.*, 37: 124-126.