Advances in Biological Research 13 (1): 01-06, 2019
ISSN 1992-0067

DOI: 10.5829/idosi.abr.2019.01.06

Argan Oil Attenuates Testis Toxicity Induced by Lead in Rats

[1, 2]G.A. EL Hag and [1]A.A. Alahmadi

[1]Department of Biological Sciences, Faculty of Sciences,
King Abdulaziz University, P.O. Box: 139109, Jeddah 21323, Saudi Arabia
[2]Department of Fisheries Science, Faculty of Agricultural Technology
and Fisheries Science, Al-Neelain University, P.O. Box: 12702, Khartoum, Sudan

Abstract: The goal of this histopathological study was to evaluate the protective effect of argan (*Argania spinosa* L.) oil on alterations in testis induced by Lead (Pb) toxicity. Forty male Wistar rats were divided randomly into four groups. The first group was served as control, the second group was exposed to Pb acetate (100 mg/kg) three times weekly. Rats of the third group were treated with argan oil (600 mg/kg) plus Pb and group four were received argan oil only. Six weeks after the end of the treatment, the testis from all rats groups were examined using light microscopy technique. The testicular structure of rats exposed to Pb showed degeneration, abnormal distribution of seminiferous tubules and damage appeared in spermatocytes. The administration of argan oil showed marked improvement in testicular tissues. We can conclude from this result that the administration of argan oil protects against testicular toxicity of Pb in male rats.

Key words: Argan Seed Oil · Lead Toxicity · Testicular histology

INTRODUCTION

The increment of environmental pollutants in recent years due to negative activities related to industrialization and modernization that lead to rise of heavy metals toxicity problem. The toxicity of heavy metals is a problem of rising significance for nutritional, ecological, evolutionary and environmental reasons [1, 2]. Despite the adverse health effects of these metals, which continue for long periods of time, but exposure to it is still continuing and growing around the world [2]. Lead is a toxic and nonessential environmental pollutant substance by the Agency for Toxic Substances and Disease Registry (ATSDR) [3, 4].

Male reproductive system is the main target for Pb toxicity that resulting in many dysfunctions such as endocrine disruptors that lead to male infertility [5, 6]. The wide distribution of Pb which is widely consumed in the chemical industry appears one of the most dangerous environmental pollutants that induced oxidative stress tissue damage causing direct depletion of antioxidant reserves [7-9]. Therefore, it has been a big concern for human health. Previous studies have shown that oxidative stress is a contributor to Pb toxicity in terms of its direct and indirect effect on the balance of antioxidants in cells [10].

Research has shown that the effect of oxidative stress in Pb toxicity can be mitigated using antioxidants of animal and plant origin [11]. Plant antioxidants depend on their components of nutrient that have the ability to radical scavenging as well as non-vitamin and minerals substances such as α-tocopherol, ascorbate, carotenoids and Zinc (Zn), in addition to flavonoids, polyphenols and flavoproteins [12]. Herbal medicines has health properties that known for centuries and commonly used, but the amount of its bioactive components determined their activity [13].

Argan oil is edible oil, extracted mainly from argan tree (*Argania spinosa* (L.) Skeels and it is considered one of the oldest forest trees in southwestern Algeria and Morocco [14, 15]. Argan oil consists of unsaturated fatty acids such as oleic (42.8%), linoleic (36.8%) and saturated fatty acids such as, stearic (6.0%), palmitic (12.0%) [16]. Tocopherols, belonging to the vitamin E active compounds characterized as a strong antioxidants and free radicals scavenging [17, 18]. There are four

Corresponding Author: Ghada Ahmed El Hag, Department of Biological Sciences, Faculty of Sciences,
King Abdulaziz University, P.O. Box: 139109, Jeddah 21323, Saudi Arabia.
Tel: +966506553617.

various forms of tocopherols occur naturally in oilseeds (α-, β-, γ- and ä-tocopherol) and the most efficient free radical scavenger of all tocopherol is gamma-tocopherol composes 69% of argan oil total tocopherol content [19, 20]. In addition, the oil is rich in tocopherol (62.0 mg/100g) making argan oil a very important source of vitamin E [21, 22]. Recent studies indicate the role of argan oil in the prevention of some diseases such as heart and blood vessel disease, cancer, retard the onset of the atherosclerosis process and treatment of high cholesterol due to argan oil as it is a choleretic and hepatoprotective agent [22]. This study is designed to investigate whether the parameters of argan oil have a protective effect on rats exposed to lead acetate referred to histopathological damages on testicular male wistar rats.

MATERIALS AND METHODS

Ethical Approval: The Ethical Committee of the Animal Care and King Fahd Medical Research Center, King Abdulaziz University, Jeddah, Saudi Arabia approved this study.

Experimental Animals and Housing: The present study was conducted using forty male albino rats (*Rattus norvegicus*), weighting 130-170 g. The experimental animals were obtained from the Experimental Animal Unit of King Fahd Medical Research Center, King Abdulaziz University, Jeddah, Saudi Arabia. They were housed in standard plastic cages located in a laboratory room with an ambient temperature of 21±°C and up to 12 h of light daily. They were fed *add libitum* on normal commercial chow and had free access to water.

Experimental Design: The experiment was conducted for six weeks. Forty rats were divided into four experimental groups; each consists of ten rats. Rats of group 1 were served as the control. Rats of group 2 were received 100 mg/kg body weight of Pb (lead acetate) orally, three days weekly. Rats of group 3 were orally supplemented with argan oil at a dose of 600 mg/kg body weight/day. In addition they were given Pb orally after 4 hours at the same dose given to group 2. Rats of group 4 were orally supplemented with argan oil at a dose of 600 mg/kg body weight/day.

Histological Examination: After six weeks, testis tissues were isolated from each group and preserved in 10% formalin immediately after rats dissected and testis organ removed from the animals. Then the tissues were embedded in paraffin, sectioned at 4μm, stained with hematoxylin and eosin and examined using light microscope (Olympus BX61- USA) connected to motorized controller unit (Olympus bx-ucb- USA) and photographed by a camera (Olympus DP72- USA) in the microscope unit at King Fahd Medical Research Center.

RESULTS

The testes samples of control rats (Fig. 1A- Fig. 2E) showed normal distribution and organization of seminiferous tubules. The evolution of transformation and conformational change in all cells stages of seminiferous epithelium developments could be in normal way. Spermatogonia cells found in direct contact on the basal lamina and these are the basic cells of the seminal lineage developmental stages. Spermatids are small which are found near the center of the seminiferous tubule. In some seminiferous tubules the spermatozoa appear with distinctive head and tail. The figures revealed that the spindly cell shape called sertoli cells are large cells rest on basement membrane. Their shape is irregular and it has a lowest number compare to other cells of seminiferous tubules. The interstitial area between the seminiferous tubules appears in normal line of connective tissue with blood and lymph vessels and leydig cells, where these cells are seen in a large, round nucleus and the cytoplasm is granular.

Microscopic examination of testis sections of Pb groups showed degeneration and abnormal distribution of seminiferous tubules. There are damages and abnormal arrangement in spermatogonial cells. Dilated and absence of interstitial spaces between seminiferous tubules due to formation of vacuoles between these tubules. The formations of vacuoles lead to increase the gaps between seminiferous tubules (Fig. 1B). Fig. 2F showed necrosis, vacuolation and degeneration of the spermatogenic cells, damage and reduction of sertoli cells. Also there are degeneration and vacuolation in the interstitial space with loss of leydig cells.

Microscopic examination of testis sections of Pb plus argan oil treated rats group showed most of seminiferous tubules are in normal structures and maturation of spermatogenic cells, normal development of spermatocytes and seminiferous tubules (Fig. 1C and Fig. 2G).

In (Fig. 1D and Fig. 2H) microscopic examination of testis section of argan oil treated rats group showed normal structure and regular arrangement in seminiferous tubules, natural developmental stages of spermatogenesis and all germ cell types (spermatogonia, spermatocytes and spermatids) outwardly in seminiferous tubules with intact interstitial tissue.

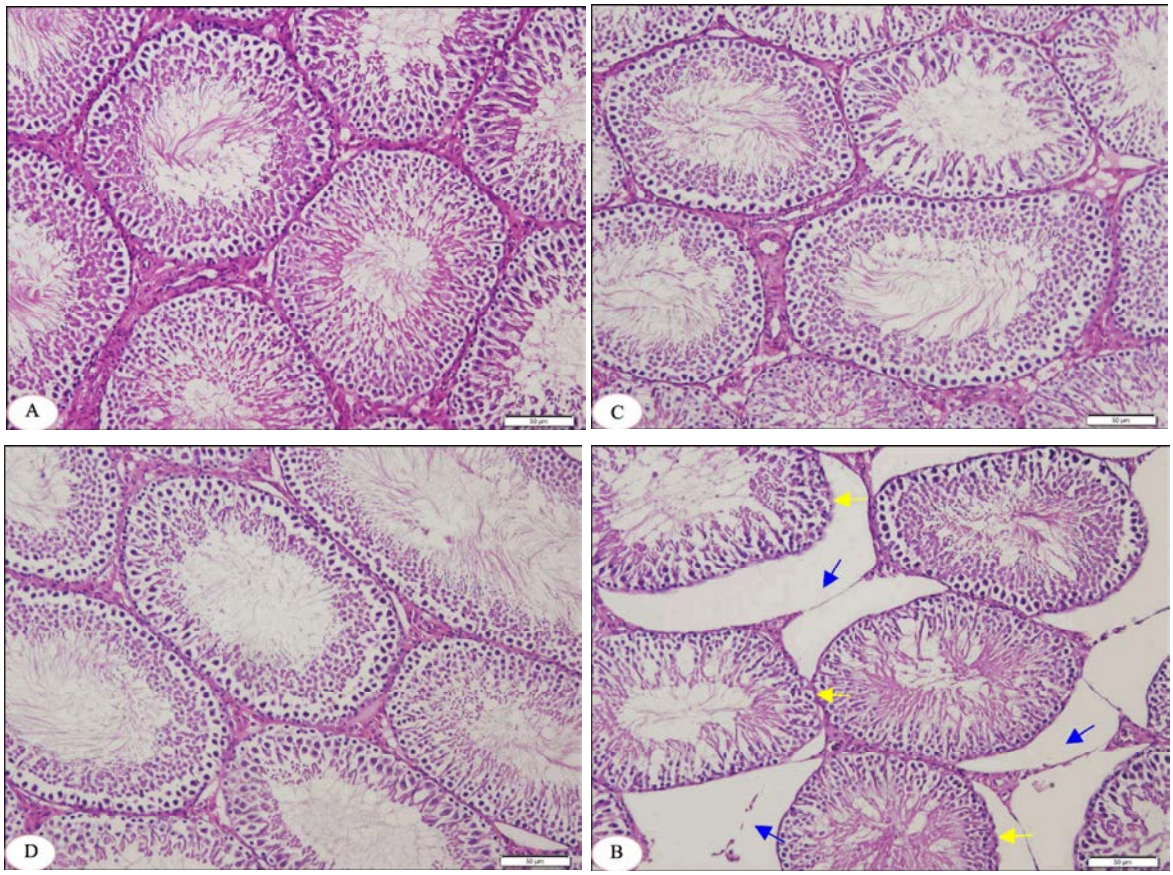

Fig. 1: (A-D) Photomicrographs of rat testis with Hematoxylin and Eosin (x20)

A: Photomicrograph of testis section of control rats showing normal seminiferous tubules structure.

B: Photomicrograph of testis section of Pb treated rats showing deterioration in the form and distribution of spermatocytes in seminiferous tubules (yellow arrows), and vacuolation in interstitial tissues (blue arrows).

C: Photomicrograph of testis section of argan oil plus Pb treated rats showing normal development of spermatocytes and development of seminiferous tubules.

D: Photomicrograph of testis section of argan oil treated rats showing normal structure and natural evolution stages of spermatogenesis in seminiferous tubules.

DISCUSSION

The histopathological result from the present study pointed out rats treated with Pb at a dose of 100 mg/kg body weight three times weekly; which motivate some histological changes in the testis tissue of male albino rats. These results showed that the testis structural tissue treated rats had negatively affected when exposed to Pb.

The present experiment clearly appeared lead acetate changes in normal structural form of testicular histology, mainly led to several alternation damage in testicular tissue. These testicular changes included degeneration, abnormal distribution of seminiferous tubules, deterioration in the form and distribution of spermatocytes in seminiferous tubules, the wreckage of damaged cells appeared in the lumen of tubules and reduction of sertoli cells. Degeneration and vacuolation hemorrhage into the interstitial space with low leydig cells appearance. These results are in symmetric line with the results of previous studies that effected on the formation and maturity of sperm cells when rats exposed to lead [23- 25].

The histological examination of testicular tissues in male rats induced by lead acetate showed necrosis of spermatogenic cells in the seminiferous tubules, congestion of blood vessels, severe interstitial edema as well as congestion of interstitial blood vessels [26]. The testicular damage induced by lead acetate affected on

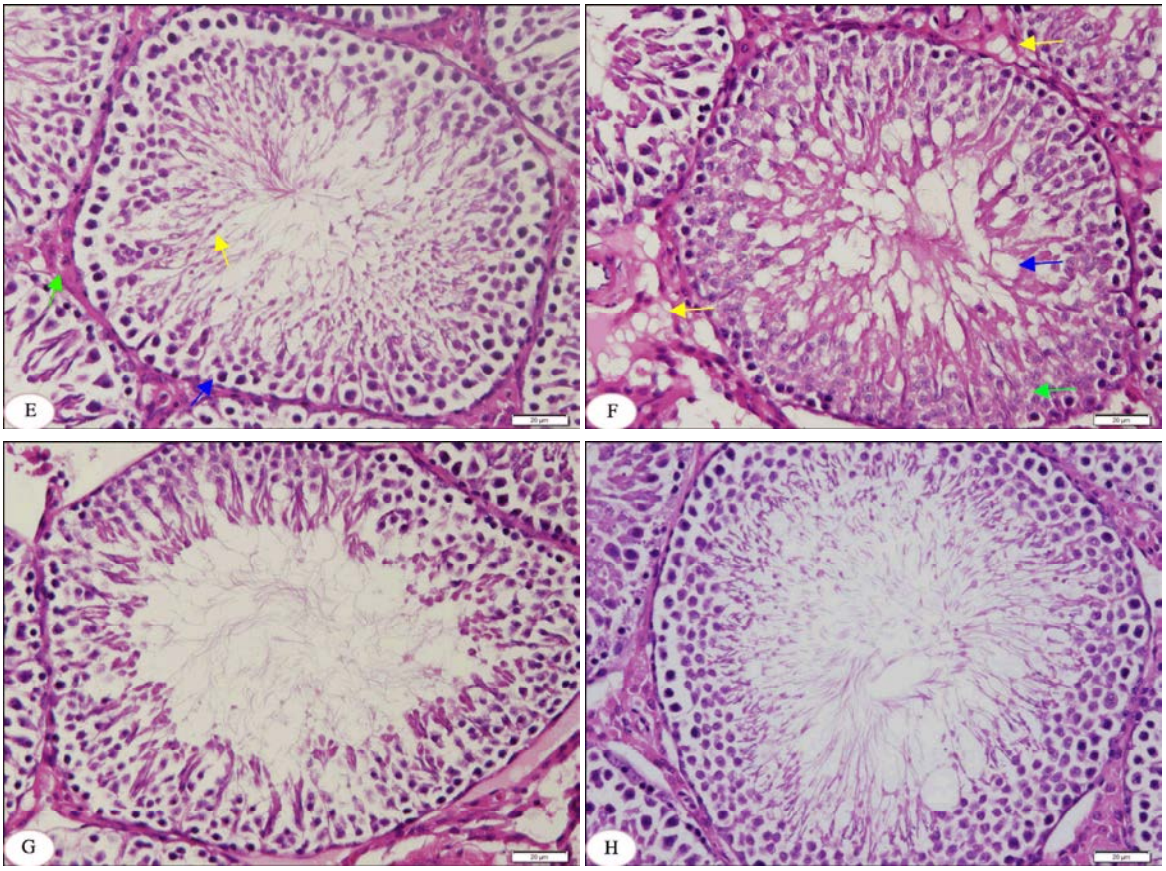

Fig. 2: (E-H) Photomicrographs of rat testis with Hematoxylin and Eosin (x40)

E: Ph otomicrograph of testis section of control rats showing normal seminiferous tubules structure with normal spermatogenesis process, spermatogonia cell (blue arrow) and Spermatid (yellow arrow), connective tissue (green arrow).

F: Ph otomicrograph of testis section of Pb treated rats showing degeneration in spermatogenic cells (green arrow), vacuolation in the lumen of tubules (blue arrow) and degeneration and vacuolation in to the interstitial space (yellow arrows).

G: Ph otomicrograph of testis section of argan oil plus Pb treated rats showing normal development of spermatocytes.

H: P hotomicrograph of testis section of argan oil treated rats showing normal structure to seminiferous tubules.

the reduction of spermatogenesis and their normal arrangement, which were different in configuration among different treated rats groups. The accumulation of Pb in the testis inhibits the formation of sperm and the development associated with the reduced male fertility [27].

Male rats treated with lead acetate (25 mg/ kg) showed alteration on testicular tissue, these changes including loss of normal architecture and seminiferous tubules with vacuolation in the spermatogenic epithelium tissues [28].Moreover, when female rats treated with Pb (25, 50 and 100 mg/kg), of female rats during gestation caused an elevation in the percentage of abnormal morphology of both epididymal and testicular spermatozoa of male mice offspring [29].

The result obtained from rats treated with lead plus argan oil revealed partial improvement in the testis tissue such as normal structure in seminiferous tubules and maturation in spermatogenic cells. However, there are some of it appeared differences in the seminiferous

tubules diameters where these changes will definitely lead to abnormality of their normal testicular functions. The present results showed that supplementing rats with argan oil improved the histopathological alterations induced by Pb toxicity. This indicated the capability of argan oil in preventing against toxicity and improved the protection of testis functions and structures of rats when exposed to Pb.

The effective role of argan oil in this study retained to antioxidant content and that explain the reason of its effectiveness in attenuating symptoms of Pb toxicity. The antioxidants affect lead to protective against the excessive amount of ROS that causes oxidative damage to the (DNA), proteins, and lipids.. Unsaturated and saturated fatty acid, phenols, tocopherols, sterols and B-carotene are all powerful antioxidants found in argan oil. In addition to Vitamin E (α-tocopherol), this is known to be a highly effective antioxidant [30]. Recent research suggested that diet supplemeted to argan oil may improved tissue injury in many diseases [31]. Argan oil has effective parameters in preventing most of the toxic effects of Pb, in accordance with literature reports. Vitamin E as an antioxidant is capable to decrease the Pb induced lipid peroxidation and reducing the deleterious impact of histopathological changes in the rat testis [26]. Through these studies, it is clear that argan oil has been able to reduce the toxic effects of lead acetate on testis tissues and improve some histopathological indicators against Pb toxicity. Therefore, this study suggests that argan oil played an antioxidant and protective role against Pb toxicity in rat testis tissue. additional investigation research into the argan oil may indicate its usefulness as a prospective treatment on the testis after testicular damage caused by lead in rats.

CONCLUSIONS

In conclusion, the present study revealed that argan oil has a preservative effect on lead acetate-induced testis toxicity and has a negative histological alternation with oxidative stress that lead to testicular damage.

ACKNOWLEDGMENT

We gratefully acknowledge the support of King Abdulaziz City for Science and Technology (KACST) for funding this project grants number 1-17-01-009-0042 through King Abdulaziz University.

REFERENCES

1. Nagajyoti, P.C., K.D. Lee and T.V.M. Sreekanth, 2010. Heavy metals, occurrence and toxicity for plants: a review. Environ. Chem. Lett., 8: 199-216. Make references like this style.
2. Jaishankar, M., T. Tseten, N. Anbalagan, B.B. Mathew and K.N. Berregowda, 2014. Toxicity, mechanism and health effects of some heavy metals. Interdiscip. Toxicol., 7: 60-72.
3. Agency for Toxic Substances and Disease Registry (ATSDR), 2007. Lead Toxicity: Who Is at Risk of Lead Exposure? Environmental Health and Medicine Education. U.S. Department of Health and Human Services. Course: WB, pp: 1105.
4. DUFFUS, J.H., 2002. Heavy metals-A meaningless term?. Pure Appl. Chem., 74: 793-807.
5. Burdorf , A., I. Figa`-Talamanca, T.K. Jensen and A.M. Thulstrup, 2006 . Effects of occupational exposure on the reproductive system, core evidence and practical implications. Occup Med., 56: 516-520.
6. Kansal, L., A. Sharma, S. Lodi and S.H. Sharma, 2011. Protective role of Coriandrums V.ativum (coriander) extracts against lead nitrate induced oxidative stress and tissue damage in the liver and kidney in male mice. Int. J. Appl. Biol. Pharm., 2: 65-83.
7. Ercal, N., H. Gurer-Orhan and N. Aykin-Burns, 2001. Toxic metals and oxidative stress part I: mechanisms involved in metal-induced oxidative damage. Curr. Top. Med. Chem., 1: 529-539.
8. Upasani, C.D., A. Khera and R. Balaraman, 2001. Effect of lead with vitamin E, C, or spirulina on malondialdehyde: conjugated dienes and hydroperoxides in rats. Ind. J. Exp. Biol., 39: 70-74.
9. Hamadouche, N.A., M. Slimani, B. Merad-Boudia and C. Zaoui, 2009. Reproductive toxicity of lead acetate in adult male rats. Amer. J. Sci. Res., 3: 38-50.
10. Flora, S.J.S., M. Mittal and A. Mehta, 2008. Heavy metal induced oxidative stress and its possible reversal by chelation therapy. Indian. J. Med. Res., 128: 501-523.
11. Adikwu, E., O. Deo, O.P.M. Geoffrey and D.A. Enimeya, 2013. Lead organ and tissue toxicity: roles of mitigating agents (part 1). Br. J. Pharmacol. Toxicol., 4: 232-240.
12. Sawant, O., V.J. Kadam and R. Ghosh, 2009. *In vitro* free radical scavenging and antioxidant activity of Adiantumlunulatum. J. Herbal. Med. Toxicol., 3: 39-44.

13. Garmza-Michalowska, A., Z. Abramowski, E. Jove and M. Hes, 2008. Antioxidant potential of herbs extracts and impact on HEPG2 cells viability. Acta. Sci. Pol., 7: 61-72.
14. Haimeur, A., M. Hessaouri, L. Ulmann, V. Mimouni, A. Masrar, A. Chraibi, G. Tremblin and N. Meskini, 2013. Argan oil prevents prothrombotic complications by lowering lipid levels and platelet aggregation, enhancing oxidative status in dyslipiemic patients from the area of rabat (Morocco). Health. Dis., 12: 107.
15. Sour, S., M. Belarbi, N. Sari, C.H. Benammar, C.H. Baghdah and F. Visioli, 2015. Argan oil reduces in rats, the high fat diet-induced metabolic effects of obesity. Nutr. Metab. Cardiovasc. Dis., 25: 382-387.
16. Khallouki, F., C. Younos, R. Soulimani, T. Oster, Z. Charrouf, B. Spiegelhalder, H. Bartsch and R.W. Owen, 2003. Consumption of argan oil (Morocco) with its unique profile of farry acids, tocopherols, squalene, sterols and phenolic compounds should confer valuable cancer chemo preventive effects. Eur. J. Cancer. Prev., 12: 67-75.
17. Guillaume, D. and Z. Charrouf, 2011. Argan oil. Altern. Med. Rev., 16: 275-279.
18. Kartah, B.A., H. El-Monfalouti, H. Harhar, S. Gharby, Z. Charrouf and B. Matthaus, 2015. Effect of filtration on virgin argan oil: quality and stability. J. Mater. Environ. Sci., 6: 2871-2877.
19. Jiang, Q., S. Christen, M.K. Shigenaga and B.N. Ames, 2001. Gamma-tocopherol, the major from vitamin E in the US diet, deserves more attention. Am. J. Clin. Nutr., 74: 714-722.
20. Charrouf, Z. and D. Guillaume, 2008. Argan oil functional food and the sustainable development of the argan forest. Nat. Prod Commun., 3: 283-288.
21. Chimi H., J. Cillard and P. Cillard, 1994. Autooxydation de l'huile d'argan Argania spinosa L. du Maroc. Science des aliments, 14: 117-124.
22. Bousalham, R., L.J. Rhazali, H. Aarmouch, H. Lotfi, B. Benazzouz, A. El Hessni, A. Ouichou, O. Akhouayri and A. Mesfioui, 2015. Dose argan oil supplementation affect metabolic parameters and behavior in wistar rats?. Food. Sci. Nutr., 6: 816-824.
23. Asadpour, R., A.A. Shahbazfar, D. Kianifard, M. Azari and N. Zaboli, 2013. Comparison of the protective effects of garlic (Allium sativumL) extract, vitamin E and N acetyl cysteine on testis structure and sperm quality in rats treated with lead acetate. Revue. Med. Vet., 164: 27-41.
24. Isaac, J.A., A.M. Bolanle and A. Oluyemi, 2013. Modulatory effects of kolaviron (Garcinia kola extract) on spermogram and reproductive system of adult male wistar rats in lead acetate induced toxicity. J. Toxicol. Environ. Health Sci., 5: 121-130.
25. Alawi, N.A, G.A. EL Hag, S.O. Rabah, N.M. Al-Baqami, N.H. Hajrah, A.M. Al-Attar and I.M. Abu Zeid, 2018. The Protective effect of Grape (Vitisvinifera) Seed Oil on Testicular Structure of Male Rats Exposed to Lead. Advances in Biological Research, 12: 16-25.
26. El-Sayed, M.F., S.K. Abdel-Ghafar, M.A. Adly, A. Abdo Salim and W.M. Abdel-Samei, 2015. The ameliorative effects of DMSA and some vitamins against toxicity induced by lead in the testes of albino rats. J. Basic. Appl. Zool., 71: 60-65.
27. Wang, X., M. Wang, W. Dong, Y. Li, Z Xheng, F. Piao and S. Li, 2013. Subchronic exposure to lead acetate inhibits spermatogenesis and downnregulates the expression of Ddx3y in testis of mice. Reprod. Toxicol., 42: 242-250.
28. El-Shafai, A., N. Zohdy, K. El-Mulla, M. Hassan and N. Morad, 2011. Lead and electron microscopic study of toxic effect of prolonged lead exposure on the seminiferous tubules of albino rats and the possible protective effect of ascorbic acid. Food Chem. Toxicol., 49: 734-743.
29. Al-Ani, I.M., I.N. Al-Khfaji, M.B. Fakhrildin, H.H. Mangalo and S.R. Al-Obaidi, 2009. The effect of lead exposure of mice during pregnancy on the morphology of epididymal and testicular spermatozoa of their offspring. I. M. J., 8: 11-16.
30. Kalender, S., F.G. Uzun, F. Demir, M. Uzunhisarcikli and A. Aslanturk, 2013. Mercuric chloride-induced testicular toxicity in rats and the protective role od sodium selenite and vitamin E. Food. Chem. Toxicol., 55: 456-462.
31. Sekeroglu, Z.A., B. Aydin and T.V. Sekeroglu, 2017. Argan oil reduces oxidative stress, genetic damage and emperipolesis in rats treated with acrylamide. Biomedecine & Pharmacotherapie, 94: 873-879.